


Journal Pre-proof

The concepts of Intra Spinal Pressure (ISP), Intra Thecal Pressure (ITP), and Spinal Cord Perfusion Pressure (SCPP) in acute, severe traumatic spinal cord injury: narrative review

Samira Saadoun, Hasan Asif, Marios C. Papadopoulos



PII: S2772-5294(24)01175-5

DOI: <https://doi.org/10.1016/j.bas.2024.103919>

Reference: BAS 103919

To appear in: *Brain and Spine*

Received Date: 30 June 2024

Revised Date: 16 September 2024

Accepted Date: 9 October 2024

Please cite this article as: Saadoun, S., Asif, H., Papadopoulos, M.C., The concepts of Intra Spinal Pressure (ISP), Intra Thecal Pressure (ITP), and Spinal Cord Perfusion Pressure (SCPP) in acute, severe traumatic spinal cord injury: narrative review, *Brain and Spine*, <https://doi.org/10.1016/j.bas.2024.103919>.

This is a PDF file of an article that has undergone enhancements after acceptance, such as the addition of a cover page and metadata, and formatting for readability, but it is not yet the definitive version of record. This version will undergo additional copyediting, typesetting and review before it is published in its final form, but we are providing this version to give early visibility of the article. Please note that, during the production process, errors may be discovered which could affect the content, and all legal disclaimers that apply to the journal pertain.

© 2024 Published by Elsevier B.V. on behalf of EUROSPINE, the Spine Society of Europe, EANS, the European Association of Neurosurgical Societies.

The concepts of Intra Spinal Pressure (ISP), Intra Thecal Pressure (ITP), and Spinal Cord Perfusion Pressure (SCPP) in acute, severe traumatic spinal cord injury: narrative review

Samira Saadoun, Hasan Asif, Marios C. Papadopoulos

Academic Neurosurgery Unit, Neuroscience and Cell Biology Research Institute, St. George's, University of London, Cranmer Terrace, Tooting, London SW17 0RE, U.K.

Correspondence to: S. Saadoun, Senior Lecturer in Neuroscience

T +44(0)2087254179

F +44(0)2087254452

E ssaadoun@sgul.ac.uk

Abstract

There is increasing interest in monitoring pressure from the injured spinal cord to guide the management of patients with acute, severe traumatic spinal cord injuries (TSCI). This is analogous to monitoring intracranial pressure and cerebral perfusion pressure in traumatic brain injury (TBI). Here, we explore key concepts in this field and novel therapies that are emerging from these ideas. We argue that the Monro-Kellie doctrine, a fundamental principle in TBI, may also apply to TSCI as follows: The injured cord swells, initially displacing surrounding cerebrospinal fluid (CSF) that prevents a rise in spinal cord pressure; once the CSF space is exhausted, the spinal cord pressure at the injury site rises. The spinal Monro-Kellie doctrine allows us to define novel concepts to guide the management of TSCI based on principles employed in the management of TBI such as intraspinal pressure (ISP), intrathecal pressure (ITP), spinal cord perfusion pressure (SCPP), spinal pressure reactivity index (sPR_x), and optimum SCPP (SCPP_{opt}). Draining lumbar CSF and expansion duroplasty are currently undergoing clinical trials as novel therapies for TSCI. We conclude that there is acknowledgement that blood pressure targets applied to all TSCI patients are inadequate. Current research aims to develop individualised management based on ISP/ITP and SCPP monitoring. These techniques are experimental. A key controversy is whether the spinal cord pressure is best measured from the injury site (ISP) or from the lumbar cerebrospinal fluid (ITP).

1. Introduction

The management of acute, severe traumatic spinal cord injury (TSCI) markedly differs from the management of acute, severe traumatic brain injury (TBI). This is surprising considering that the brain and the spinal cord are comprised of the same cell types similarly arranged, which implies that they respond to trauma in the same way. Here, we argue that basic principles developed to aid the management of acute, severe TBI in the intensive care unit (ICU), such as intracranial pressure (ICP), cerebral perfusion pressure (CPP), and decompressive craniectomy (DC) also apply in TSCI. We discuss research attempting to define analogous concepts in TSCI and provide ideas for future research.

2. Current management

2.1 Traumatic brain injury. Patients with severe TBI have CT imaging of the brain and are urgently transferred to an ICU for monitoring ICP and CPP [1]. TBI management focusses on optimising each patient's ICP and CPP to prevent secondary brain damage. ICP and CPP vary between patients, and the causes for high ICP and low CPP (e.g. intracranial haematoma, cerebral contusion, and diffuse brain oedema) also vary. Different treatments are employed including osmotic diuretics, removal of haematoma, and DC. CT imaging and ICP/CPP monitoring thus allow individualised management of TBI patients, by neurosurgeons and ICU physicians specialising in neurotrauma.

2.2 Traumatic Spinal Cord Injury. TSCI patients are managed by orthopaedic surgeons or neurosurgeons. Many TSCI patients are not admitted to ICU. A CT scan of the spine is done to define the bony damage. Unlike TBI, where the CT provides useful information about the injured brain (e.g. haematoma, effacement of ventricles, effacement of basal cisterns, midline shift), in TSCI an MRI is required to visualise the spinal cord, which is cumbersome to obtain

as an emergency. Surgical decisions focus on how to fix the spine (e.g. anterior vs. posterior vs. 360° approach) and how many levels to fix. The optimal timing of surgery (early ≤ 24 hours vs. late >24 hours) has been vigorously debated with most surgeons currently advocating early decompression and fixation [2]. What constitutes effective spinal cord decompression in TSCI has received little attention [3]. Most surgeons request a CT after spinal fixation to visualise the metalwork and to demonstrate restoration of normal spinal alignment. CT provides little information about the adequacy of spinal cord decompression, in contrast to brain CT in TBI that clearly shows whether the brain has been well-decompressed. Thus, the surgical emphasis in TSCI is on bony fixation, whereas in TBI it is on effective decompression of the injured brain.

The haemodynamic management after TSCI is also poorly defined [4]. The lack of monitoring from the injury site, analogous to ICP and CPP monitoring in TBI, means that doctors are unaware of the status of the injury site, thus making it impossible for them to initiate meaningful treatment to prevent secondary spinal cord damage. Management guidelines often mention maintaining mean arterial pressure (MAP) 85 – 90 mmHg for a week after TSCI injury [5], but with weak evidence that this is beneficial and with some evidence that it is detrimental in the elderly [6-8]. Surely, what matters in TSCI is not the MAP, but the spinal cord perfusion pressure (SCPP), a concept analogous to the CPP in TBI [6]. To illustrate the superiority of SCPP over MAP, consider patient with a swollen and compressed spinal cord (high ISP) who will require a higher MAP to maintain adequate spinal cord perfusion than a patient with a well-decompressed spinal cord (low ISP).

3. Pressure-volume relationship at the injury site

A basic concept in TBI is the Monro-Kellie doctrine, which states that the sum of the volumes of brain, CSF, and intracranial blood is constant and thus an increase in one should

cause a decrease in one or both of the other two [1]. After TBI, the brain swells initially displacing venous blood and CSF, which are low-pressure compartments, thus preventing a rise in ICP. When the CSF and venous blood spaces become exhausted, the brain then becomes compressed generating a steeply rising ICP with increased brain swelling. This concept explains the exponential pressure-volume relationship of the intracranial system.

It is likely that the Monro-Kellie doctrine also applies in TSCI (Fig. 1). The injured spinal cord swells thus displacing venous blood and surrounding CSF, to prevent a rise in spinal cord pressure. Once the CSF and venous blood spaces become exhausted, the swollen spinal cord becomes compressed against the surrounding theca and spinal cord pressure at the injury site will begin to rise. After TSCI, there is often external compression of the theca (e.g. by bone, haematoma, disc etc) which reduces the compensatory reserve space around the injured spinal cord. The Monro-Kellie doctrine likely still applies in TSCI even in the absence of extrathecal compression, e.g. following bony decompression including laminectomy. In the absence of extrathecal compression, there is more compensatory reserve space around the injured spinal cord; however, the swollen injured spinal cord will ultimately become compressed against the non-stretchable theca. The theca has a high elastic modulus, axially, of 5 – 20 MPa [9], which means that changes in pressure within the physiologically relevant range i.e. 0 – 50 mmHg (0 – 0.0067 MPa) would not produce any appreciable stretching of the theca. These arguments apply to pressure changes that happen within a few days. The theca may stretch, and the adjacent bone may remodel, in conditions of chronically elevated pressure, which are not relevant here. This argument means that it is possible to define the concept of Intra Spinal Pressure (ISP) in TSCI analogous to ICP for TBI.

What contributes to elevated pressure of CNS tissue at the injury site in brain *vs.* spinal cord? In TBI, brain oedema and various types of intracranial haematoma (extradural, subdural, intraparenchymal) are the main causes of elevated ICP. In TSCI, the elevated ISP

arises from cord compression external to the dura by bony fragments, disc material and haematoma. What is less well appreciated, and by analogy to TBI, the elevated ISP also arises from the swollen spinal cord (by cord oedema, intramedullary haematoma) becoming compressed against the surrounding dura [10].

4. Monitoring spinal cord pressure

4.1 Intra Spinal Pressure (ISP). ISP, defined as the pressure within the spinal cord at the injury site, is technically difficult to measure safely, because inserting a pressure probe into the injured cord will potentially exacerbate cord damage. Some groups monitor ISP by placing a pressure probe between the injured cord and the dura at the injury site [11, 12]. When the injured spinal cord is compressed against surrounding structures, this technique measures ISP, which differs from cerebrospinal fluid pressure (CSFP) above the injury site, CSFP [13, 14] below, and extradural pressure, i.e. there is compartmentalisation at the injury site (Fig. 2). When the injured spinal cord is not compressed, this technique measures CSFP which, with the patient, lying horizontally, is the same throughout the CSF spaces. When there is CSF around the injury site, the pressure inside the spinal cord at the injury site may not equal CSFP, if the pia is intact. In normal spinal cord, the pia is tough enough to allow high pressure to be generated inside the cord without spinal cord swelling, by ~70 mm Hg (cervical) and ~50 mm Hg (thoracic) [15]. Experiments in rodents indicate that, after severe TSCI, the pia becomes damaged and no longer restricts spinal cord swelling or spinal cord compression against the dura [16-18].

There are limitations to inserting a pressure probe intradurally to measure ISP [19]. First is the risk of exacerbating spinal cord damage whilst inserting the probe. Second, is the risk of pseudomeningocele and/or CSF leak through the surgical wound. Third, the probe can only be inserted under direct vision using a microscope in the operating room. Data from 42

patients who had ISP monitoring [19] show that the technique is safe: complications were probe displacement in 1/42 patients (2.4 %), CSF leakage that required wound re-suturing in 3/42 (7.1 %), and asymptomatic pseudomeningocele in 8/42 patients (19.0 %) that resolved within 6 months in all patients. ISP measurements have provided invaluable information to define the physiology of spinal cord swelling and spinal cord perfusion after TSCI.

4.2 Biophysics of the ISP signal. The ISP signal is remarkably similar to ICP [12, 20] with three peaks: P1 (percussion wave generated from arterial pulsation), P2 (tidal wave, represents spinal cord compliance), and P3 (dicrotic wave, produced by aortic valve closure). Fourier analysis reveals frequency peaks for heart rate, respiration, and harmonics. With increasing ISP, P2 rises with the ISP waveform ultimately becoming rounded and losing the individual peaks. These changes in the ISP waveform shape with increasing ISP further support the notion that the Monroe-Kellie doctrine, initially developed in TBI, also applies to TSCI at the injury site. This means that we can define the concept of compensatory reserve, i.e. how much space there is around the injured spinal cord to allow cord swelling without generating high ISP. In TBI, compensatory reserve is measured using the RAP index, computed as the correlation coefficient (R) between the ICP pulse amplitude AMP (A) and the mean ICP (P) [13, 14]. $RAP = 0$ on the linear part of the pressure-volume curve, $+1$ on the ascending exponential part, and ≤ 0 as ICP increases further related to the critical closing of cerebral vessels. By analogy with RAP in TBI, we defined sRAP in TSCI as the spinal compensatory reserve index and showed that, as ICP rises and as SCPP falls, compensatory reserve is exhausted [12].

4.3 Autoregulation and optimum spinal cord perfusion. A basic concept in neurotrauma is cerebral autoregulation, which is the ability of the brain to maintain constant cerebral blood

flow (CBF) independent of changes in arterial blood pressure (ABP). Intact autoregulation means that an increase in ABP causes vasoconstriction, whereas a decrease in ABP causes vasodilation, to maintain constant CBF. Vasoconstriction will decrease the ICP whereas vasodilatation will increase the ICP. Thus, with intact autoregulation, there is a negative correlation between the ABP and the ICP signals. When autoregulation is impaired in TBI, CBF, and thus ICP, increases (or decreases) as ABP increases (or decreases) and, therefore, there is a positive correlation between ABP and ICP. The running correlation coefficient between ICP and ABP, termed 'Pressure Reactivity index' or PRx is widely used to quantify cerebral autoregulation [21, 22].

An analogous concept may also be defined in TSCI, i.e. the running correlation coefficient between ISP and ABP, termed the 'spinal PRx' or sPRx [12]. Fig. 3 shows plots of ISP vs. PRx and SCPP vs. PRx for two patients with acute, severe TSCIs. As ISP rises, autoregulation becomes increasingly disrupted in both patients. Each patient has a different optimum SCPP ($SCPP_{opt}$) defined as the minimum of the sPRx vs. SCPP curve. Reducing the SCPP below $SCPP_{opt}$, causes spinal cord hypoperfusion with more disrupted autoregulation. Increasing the SCPP above $SCPP_{opt}$, causes spinal cord hyperperfusion, again with more disrupted autoregulation. $SCPP_{opt}$ not only varies between patients, but $SCPP_{opt}$ also varies with time in each patient [23]. The concept of $SCPP_{opt}$ may be further refined to be a range rather than a single value, defined as the range of SCPP that maintains sPRx <0.2 . Targeting SCPP within a range is more practical, than trying to achieve a single SCPP value.

4.4 Intra Thecal Pressure (ITP). Another way of measuring pressure is by inserting a lumbar catheter [24, 25]. This pressure, termed intrathecal pressure (ITP), is the CSFP in the lumbar subarachnoid space. Advantages of this technique, compared with ISP monitoring, are familiarity with inserting a lumbar catheter, ease of insertion, insertion done in the ICU

without surgery, and no risk of damaging the injured cord. The lumbar catheter may also be used to drain CSF to reduce the ITP, potentially increasing spinal cord perfusion. The idea of monitoring ITP comes from vascular surgery, to monitor spinal cord perfusion in thoracoabdominal aneurysm repair and drain CSF to reduce spinal cord ischaemia [26].

When there is CSF around the injured spinal cord, ISP (measured at the injury site using an intradural, extramedullary probe) = ITP. In this situation SCPP, calculated as mean arterial pressure (MAP) minus ISP (measured at the injury site using an intradural, extramedullary probe), is the same as SCPP calculated as $MAP - ITP$. If the pia mater is intact, the pressure inside the injured spinal cord may be higher than CSFP; however, CSFP contributes to the pressure inside the spinal cord and thus draining CSF should reduce spinal cord pressure, as done during thoracoabdominal aneurysm repair [26].

When the injured spinal cord is compressed, ISP (measured at the injury site using an intradural, extramedullary probe) \neq ITP. In this case, SCPP computed as $MAP - ISP \neq$ SCPP computed as $MAP - ITP$. Therefore, draining CSF from the lumbar subarachnoid space is expected to reduce ITP and increase SCPP (computed as $MAP - ITP$), but not to have an appreciable effect on ISP or SCPP (computed as $MAP - ISP$). In 12 patients with acute, severe TSCI, there was no correlation between mean 24-hour ISP (measured at the injury site using an intradural, extramedullary probe) and simultaneously measured mean 24-hour ITP [27]. Examination of the ISP and ITP traces revealed periods when $ITP = ISP$ and periods when $ITP \neq ISP$. This finding suggests that, following surgery, spinal cord compression against the dura is dynamic, and that ITP may be an inadequate estimate of ISP.

Unlike ISP, ITP cannot be used to compute other physiological parameters of the injured spinal cord such as pressure reactivity and optimum SCPP, defined below. Monitoring from the lumbar CSF compartment precludes multi-modality monitoring including

microdialysis [28] and spinal cord tissue oxygen (p_{sctO_2}) [29], because these probes need to contact spinal cord tissue at the injury site to provide meaningful readings.

5. Novel treatments

5.1 Effect of draining lumbar CSF. Currently, the Canadian/American Spinal Cord Perfusion Pressure and Biomarker Study (CASPER, Clinicaltrials.gov NCT03911492) trial is investigating whether ‘the active management of SCPP (computed at $\text{MAP} - \text{ITP}$) with maintenance at ≥ 65 mmHg results in better neurologic recovery than conventional hemodynamic management that aims solely to maintain the MAP’. As discussed above, this definition of SCPP is not necessarily the same as $\text{SCPP} = \text{MAP} - \text{ISP}$. Draining 10 mL CSF from the lumbar subarachnoid space in 12 patients had variable effect on ISP, sometimes decreasing ISP, sometimes increasing ISP, sometimes without changing ISP, but overall having little influence on ISP following several CSF drainages per patient [27]. Draining 10 mL CSF from the lumbar subarachnoid space also had a variable effect on p_{sctO_2} , sometimes decreasing p_{sctO_2} , sometimes increasing p_{sctO_2} , sometimes without change in p_{sctO_2} , but overall having little influence on p_{sctO_2} following several CSF drainages per patient [29]. These findings suggest that draining lumbar CSF may not effectively improve spinal cord physiology at the injury site. This may be because, unlike TBI where draining CSF from a lateral ventricle may create more intracranial space thus reducing ICP, in TSCI there is no CSF around the swollen cord compressed against the theca and therefore draining CSF does not effectively reduce ISP or increase p_{sctO_2} .

5.2 Expansion duroplasty (or duraplasty). After TBI, the swollen brain becomes compressed against dura and skull. Therefore, DC requires not only removing skull, but also opening the dura to effectively reduce ICP [30]. Decompressing the injured spinal cord

merely refers to restoring normal spinal alignment and removing components compressing the spinal cord from outside the dura such as bone fragments, disc protrusions or haematoma. The concept that spinal cord compression may arise because of ‘compression from inside the dura’, i.e. the cord is expanded and compressed against the dura is not widely appreciated. It is interesting to speculate why the notion of ‘compression from inside the dura’ has not developed in TSCI:

1. The injured cord cannot be adequately visualised on CT imaging, and most surgeons do not obtain MRIs postoperatively to visualise compression of the injured cord against the dura.
2. The most common surgical pathologies that affect the spinal cord such as disc protrusion, canal stenosis, and ossification of the posterior longitudinal ligament are compressions from structures outside the dura. This introduces bias when thinking about TSCI, that spinal cord compression is also solely from external factors.
3. TSCI is commonly associated with extradural spinal cord compression from bony fragments, which are the most striking feature on the pre-operative MRI making it impossible to visualise ‘compression from inside’.
4. Many TSCI patients are managed by orthopaedic surgeons rather than neurosurgeons who may not be very familiar with the TBI concepts of ICP, and CPP.

Recently, some surgeons have used ultrasound imaging intraoperatively to ensure adequate decompression of the spinal cord by showing CSF surrounding the cord [31, 32]. Ultrasound is non-invasive, easy to use, and provides clear images of the injured cord. A potential problem is that intraoperative ultrasound may provide false reassurance in case of delayed spinal cord swelling with cord compression against the dura. The analogy with TBI is an early CT showing no brain compression but effacement of basal cisterns after a few days as brain oedema increases, and brain contusions blossom [33, 34]. ISP monitoring for

several days after TSCI is required to define the evolution of spinal cord swelling after TSCI. Another problem is that intraoperative USS is only feasible following laminectomy and thus impossible to perform with an anterior approach.

The logical extension of the concept of spinal cord compression by dura is surgical decompression not only by laminectomy, but also by duroplasty to reduce ISP, analogous to DC in TBI. Several case series report generally positive findings with duroplasty after TSCI [35-37]. A pilot study has shown that the procedure is safe, and effectively reduces ISP, increases SCPP and improves sPRx [35]. Duroplasty is a simple surgical technique [35-37]. After laminectomy, the theca is incised longitudinally under the microscope. An oval-shaped dural patch is then sutured along the thecal edges. The longitudinal extent of the thecal opening is judged from the preoperative MRI to span the extent of cord injury. The width of the patch is about 2 cm. Fig. 4 shows an example of expansion duroplasty in a TSCI patient. Duroplasty is often performed during foramen magnum decompression for Chiari malformation [38, 39] but it has not been widely used in TSCI and thus the technique is not standardised in this context. Unanswered questions are whether to open the arachnoid, whether to divide the dentate ligament, whether to place a tenting suture, and whether to use fibrin sealant that may limit CSF leak but cause delayed cord compression. Commonly used dural substitutes are acellular bovine collagen, and endogenous fascia lata [40]. In experienced hands the procedure adds about 30 minutes to the operating time and the cost of an artificial duroplasty patch is around €100. The main complication is non-compressive pseudomeningocele evident on postoperative MRI that disappears within 6 months postoperatively.

A randomised controlled trial is underway, termed Duroplasty for Injured cervical Spinal Cord with Uncontrolled Swelling (DISCUS), [clinicaltrials.gov NCT04936620](https://clinicaltrials.gov/ct2/show/study/NCT04936620) [41]. Adult patients with acute severe cervical TSCIs are randomised 1:1 to have bony

decompression including laminectomy *vs.* bony + dural decompression. The inclusion-exclusion criteria are listed in Table 1. The primary outcome measure is the change in the motor score of the American spinal injury association Impairment Scale (AIS) at 6 months post-randomisation *vs.* baseline. Monitoring ISP and/or microdialysis from the injury site, to test the hypothesis that duroplasty reduces ISP and improves metabolism (higher tissue glucose, lower tissue lactate-to-pyruvate ratio) at the injury site compared with bony decompression is optional.

5.3 Effect of intervention to increase SCPP. Some studies have used multi-modality monitoring from the injury site in which probes were inserted intradurally to monitor not only ISP and SCPP, but also microdialysis [28] and p_{sctO_2} [29] of spinal cord tissue. This is analogous to multi-modality monitoring for TBI which involves monitoring ICP, microdialysis, and brain tissue oxygen [42]. Increasing SCPP improved the metabolic [28] and oxygenation [29] profiles of the injured spinal cord including higher tissue glucose, lower tissue lactate-to-pyruvate ratio as well as higher p_{sctO_2} .

There are several studies generally reporting positive experiences when intervening to increase SCPP in patients with acute, severe TSCIs. In these studies, SCPP is increased by increasing the MAP using inotropes. Osmotic diuretics, widely used to reduce ICP in TBI, do not effectively reduce ISP in TSCI [6]. In a cohort of AIS grade C patients, there was a linear correlation between limb motor score plotted against SCPP [43]. Increasing SCPP has also been shown to lower the sensory level in some patients [44], and improve urodynamic parameters such as reducing the urinary bladder fill volume that produces the first desire to void [45]. In a recent study of patients with severe cervical TSCIs, there was an inverted U-shaped relationship between various measures of diaphragmatic function, primarily derived from ultrasound scanning, *vs.* SCPP [46]. There is also a strong correlation between the SCPP

averaged over the first two weeks after surgery and long-term neurological outcome quantified as AIS grade conversion [24, 47]. Together, these findings suggest that SCPP is a fundamental physiological parameter after TSCI.

6. Future directions

Table 2 summaries key analogous concepts in TBI and TSCI. Monitoring ISP (or ITP) is not widely performed and remains experimental. This may be due to surgical pessimism regarding outcomes in TSCI, concern of damaging the cord by inserting probes intradurally or draining CSF, concern of causing meningitis or metalwork infection, or shortage of ICU beds. Current clinical management of acute TSCI with emphasis on improving neurological function remains rudimentary, compared with TBI management where ICP monitoring is widespread. Recent consensus recommendations on the haemodynamic management of TSCI are to maintain an optimal MAP acknowledging uncertainty what is optimum MAP; SCPP remains experimental but with increasing efforts to elucidate this concept [48]. The concept of SCPP, while making sense, needs to be validated in large prospective studies; the evidence to date on the role of SCPP monitoring is low and does not at this stage support a shift in practice [4].

Future developments will likely arise from collaboration between the investigators who monitor ISP/ITP to develop concepts together, share monitoring data, exchange ideas, conduct multi-centre trials (because no single centre can provide enough TSCI patients), and publish consensus recommendations. The development of novel optical and ultrasound probes to monitor from the injury site that can be placed extradurally by percutaneous approach by ICU doctors without surgery may facilitate widespread use of such monitoring techniques in TSCI.

In severe TBI, DC has been shown to reduce mortality [49]. Many survivors have severe cognitive disabilities, which makes this surgical treatment option controversial. Because the brain has cognition, preservation of brain tissue in severe TBI may increase awareness of the disability enough to increase suffering. The spinal cord is a purely mechanical system lacking consciousness. Thus, any spinal cord tissue preservation in TSCI, by interventions to improve SCPP, should improve quality of life by increasing limb sensation, limb power, sphincter control, thermoregulation, and blood pressure control.

7. References

1. Rabelo NN, da Silva Brito J, da Silva JS, de Souza NB, Coelho G, Brasil S, et al. The historic evolution of intracranial pressure and cerebrospinal fluid pulse pressure concepts: Two centuries of challenges. *Surg Neurol Int.* 2021;12:274. https://doi.10.25259/SNI_53_2021.
2. Ter Wengel PV, Reith F, Adegeest CY, Fehlings MG, Kwon BK, Vandertop WP, et al. Under pressure - A historical vignette on surgical timing in traumatic spinal cord injury. *Brain Spine.* 2024;4:102825. <https://doi.10.1016/j.bas.2024.102825>.
3. Aarabi B, Olexa J, Chryssikos T, Galvagno SM, Hersh DS, Wessell A, et al. Extent of Spinal Cord Decompression in Motor Complete (American Spinal Injury Association Impairment Scale Grades A and B) Traumatic Spinal Cord Injury Patients: Post-Operative Magnetic Resonance Imaging Analysis of Standard Operative Approaches. *J Neurotrauma.* 2019;36:862–76. <https://doi.10.1089/neu.2018.5834>.
4. Evaniew N, Davies B, Farahbakhsh F, Fehlings MG, Ganau M, Graves D, et al. Interventions to Optimize Spinal Cord Perfusion in Patients With Acute Traumatic Spinal

Cord Injury: An Updated Systematic Review. *Global Spine J.* 2024;14:58S–79S.

<https://doi.10.1177/21925682231218737>.

5. Saadeh YS, Smith BW, Joseph JR, Jaffer SY, Buckingham MJ, Oppenlander ME, et al.

The impact of blood pressure management after spinal cord injury: a systematic review of the literature. *Neurosurg Focus.* 2017;43:E20. <https://doi.10.3171/2017.8.FOCUS17428> .

6. Werndle MC, Saadoun S, Phang I, Czosnyka M, Varsos G, Czosnyka Z, et al.

Measurement of Intraspinial Pressure After Spinal Cord Injury: Technical Note from the Injured Spinal Cord Pressure Evaluation Study. *Acta Neurochir Suppl.* 2016;122:323–8. https://doi.10.1007/978-3-319-22533-3_64 .

7. Inoue T, Manley GT, Patel N , Whetstone WD. Medical and surgical management after spinal cord injury: vasopressor usage, early surgeries, and complications. *J Neurotrauma.* 2014;31:284–91. <https://doi.10.1089/neu.2013.3061> .

8. Readdy WJ, Whetstone WD, Ferguson AR, Talbott JF, Inoue T, Saigal R, et al.

Complications and outcomes of vasopressor usage in acute traumatic central cord syndrome. *J Neurosurg Spine.* 2015;23:574–80. <https://doi.10.3171/2015.2.SPINE14746> .

9. Percy Q, Tomlinson J, Niestrawska JA, Mobius D, Zhang M , Zwirner J. Systematic review and meta-analysis of the biomechanical properties of the human dura mater applicable in computational human head models. *Biomech Model Mechanobiol.* 2022;21:755–70. <https://doi.10.1007/s10237-022-01566-5>.

10. Saadoun S, Werndle MC, Lopez de Heredia L , Papadopoulos MC. The dura causes spinal cord compression after spinal cord injury. *Br J Neurosurg.* 2016;30:582–4.

<https://doi.10.3109/02688697.2016.1173191> .

11. Dhaliwal P, Gomez A , Zeiler FA. Case report: Continuous spinal cord physiologic monitoring following traumatic spinal cord injury-A report from the Winnipeg Intraspinal Pressure Study (WISP). *Front Neurol.* 2023;14:1069623. <https://doi.10.3389/fneur.2023.1069623>.
12. Werndle MC, Saadoun S, Phang I, Czosnyka M, Varsos GV, Czosnyka ZH, et al. Monitoring of spinal cord perfusion pressure in acute spinal cord injury: initial findings of the injured spinal cord pressure evaluation study*. *Crit Care Med.* 2014;42:646–55. <https://doi.10.1097/CCM.0000000000000028> .
13. Zeiler FA, Ercole A, Cabeleira M, Beqiri E, Zoerle T, Carbonara M, et al. Compensatory-reserve-weighted intracranial pressure versus intracranial pressure for outcome association in adult traumatic brain injury: a CENTER-TBI validation study. *Acta Neurochir (Wien).* 2019;161:1275–84. <https://doi.10.1007/s00701-019-03915-3>.
14. Zeiler FA, Kim D, Cabeleira M, Calviello L, Smielewski P , Czosnyka M. Impaired cerebral compensatory reserve is associated with admission imaging characteristics of diffuse insult in traumatic brain injury. *Acta Neurochir (Wien).* 2018;160:2277–87. <https://doi.10.1007/s00701-018-3681-y>.
15. Harwell DM, Gibson JL, Fessler RD, Holtz J, Pettigrew DB , Kuntz C. Pia Mater Significantly Contributes to Spinal Cord Intraparenchymal Pressure in a Simulated Model of Edema. *Spine (Phila Pa 1976).* 2016;41:524. <https://doi.10.1097/BRS.0000000000001306> .
16. Khaing ZZ, Cates LN, Fishedick AE, McClintic AM, Mourad PD , Hofstetter CP. Temporal and Spatial Evolution of Raised Intraspinal Pressure after Traumatic Spinal Cord Injury. *J Neurotrauma.* 2017;34:645–51. <https://doi.10.1089/neu.2016.4490> .

17. Khaing ZZ, Cates LN, Dewees DM, Hyde JE, Gaing A, Birjandian Z, et al. The effect of durotomy versus myelotomy on tissue sparing and functional outcome after spinal cord injury. *J Neurotrauma*. 2020 <https://doi.10.1089/neu.2020.7297> .
18. Khaing ZZ, Cates LN, Dewees DM, Hyde JE, Gaing A, Birjandian Z, et al. Effect of Durotomy versus Myelotomy on Tissue Sparing and Functional Outcome after Spinal Cord Injury. *J Neurotrauma*. 2021;38:746–55. <https://doi.10.1089/neu.2020.7297>.
19. Phang I, Zoumprouli A, Saadoun S , Papadopoulos MC. Safety profile and probe placement accuracy of intraspinal pressure monitoring for traumatic spinal cord injury: Injured Spinal Cord Pressure Evaluation study. *J Neurosurg Spine*. 2016;25:398–405. <https://doi.10.3171/2016.1.SPINE151317> .
20. Varsos GV, Werndle MC, Czosnyka ZH, Smielewski P, Koliass AG, Phang I, et al. Intraspinal pressure and spinal cord perfusion pressure after spinal cord injury: an observational study. *J Neurosurg Spine*. 2015;23:763–71. <https://doi.10.3171/2015.3.SPINE14870> .
21. Donnelly J, Czosnyka M, Adams H, Cardim D, Koliass AG, Zeiler FA, et al. Twenty-Five Years of Intracranial Pressure Monitoring After Severe Traumatic Brain Injury: A Retrospective, Single-Center Analysis. *Neurosurgery*. 2019;85:E75–82. <https://doi.10.1093/neuros/nyy468> .
22. Czosnyka M, Czosnyka Z , Smielewski P. Pressure reactivity index: journey through the past 20 years. *Acta Neurochir (Wien)*. 2017;159:2063–5. <https://doi.10.1007/s00701-017-3310-1> .

23. Chen S, Smielewski P, Czosnyka M, Papadopoulos MC , Saadoun S. Continuous Monitoring and Visualization of Optimum Spinal Cord Perfusion Pressure in Patients with Acute Cord Injury. *J Neurotrauma*. 2017;34:2941–9. <https://doi.10.1089/neu.2017.4982> .
24. Squair JW, Belanger LM, Tsang A, Ritchie L, Mac-Thiong JM, Parent S, et al. Spinal cord perfusion pressure predicts neurologic recovery in acute spinal cord injury. *Neurology*. 2017;89:1660–7. <https://doi.10.1212/WNL.0000000000004519> .
25. Kwon BK, Curt A, Belanger LM, Bernardo A, Chan D, Marquez JA, et al. Intrathecal pressure monitoring and cerebrospinal fluid drainage in acute spinal cord injury: a prospective randomized trial. *J Neurosurg Spine*. 2009;10:181–93. <https://doi.10.3171/2008.10.SPINE08217> .
26. Blakeslee-Carter J, Novak Z, Jansen JO, Schanzer A, Eagleton MJ, Farber MA, et al. Prospective randomized pilot trial comparing prophylactic and therapeutic cerebrospinal fluid drainage during complex endovascular thoracoabdominal aortic aneurysm repair. *J Vasc Surg*. 2024;80:11–9. <https://doi.10.1016/j.jvs.2024.02.041>.
27. Hogg FRA, Gallagher MJ, Kearney S, Zoumprouli A, Papadopoulos MC , Saadoun S. Acute Spinal Cord Injury: Monitoring Lumbar Cerebrospinal Fluid Provides Limited Information about the Injury Site. *J Neurotrauma*. 2020;37:1156–64. <https://doi.10.1089/neu.2019.6789> .
28. Phang I, Zoumprouli A, Papadopoulos MC , Saadoun S. Microdialysis to Optimize Cord Perfusion and Drug Delivery in Spinal Cord Injury. *Ann Neurol*. 2016;80:522–31. <https://doi.10.1002/ana.24750> .

29. Visagan R, Hogg FRA, Gallagher MJ, Kearney S, Zoumprouli A, Papadopoulos MC, et al. Monitoring Spinal Cord Tissue Oxygen in Patients With Acute, Severe Traumatic Spinal Cord Injuries. *Crit Care Med.* 2022;50:e477–86. <https://doi.10.1097/CCM.0000000000005433>.
30. Schirmer CM, Ackil AAJ, Malek AM. Decompressive Craniectomy. *Neurocrit Care.* 2008;8:456–70. <https://doi.10.1007/s12028-008-9082-y>.
31. Chryssikos T, Stokum JA, Ahmed A, Chen C, Wessell A, Cannarsa G, et al. Surgical Decompression of Traumatic Cervical Spinal Cord Injury: A Pilot Study Comparing Real-Time Intraoperative Ultrasound After Laminectomy With Postoperative MRI and CT Myelography. *Neurosurgery.* 2023;92:353–62. <https://doi.10.1227/neu.0000000000002207>.
32. Ali DM, Harrop J, Sharan A, Vaccaro AR, Sivaganesan A. Technical Aspects of Intra-Operative Ultrasound for Spinal Cord Injury and Myelopathy: A Practical Review. *World Neurosurg.* 2023;170:206–18. <https://doi.10.1016/j.wneu.2022.10.101>.
33. Carnevale JA, Segar DJ, Powers AY, Shah M, Doberstein C, Drapcho B, et al. Blossoming contusions: identifying factors contributing to the expansion of traumatic intracerebral hemorrhage. *J Neurosurg.* 2018;129:1305–16. <https://doi.10.3171/2017.7.JNS17988>.
34. Ratan R, Mohindra S, Tripathi M, Singla R, Chauhan R. Factors determining the requirement of surgical intervention and prognosis in cases of traumatic bifrontal contusions: A prospective observational study. *Surg Neurol Int.* 2023;14:438. https://doi.10.25259/SNI_754_2023.

35. Phang I, Werndle MC, Saadoun S, Varsos G, Czosnyka M, Zoumprouli A, et al. Expansion duroplasty improves intraspinal pressure, spinal cord perfusion pressure, and vascular pressure reactivity index in patients with traumatic spinal cord injury: injured spinal cord pressure evaluation study. *J Neurotrauma*. 2015;32:865–74. <https://doi.10.1089/neu.2014.3668> .
36. Zhu F, Yao S, Ren Z, Telemacque D, Qu Y, Chen K, et al. Early durotomy with duroplasty for severe adult spinal cord injury without radiographic abnormality: a novel concept and method of surgical decompression. *Eur Spine J*. 2019;28:2275–82. <https://doi.10.1007/s00586-019-06091-1> .
37. Garg K, Agrawal D , Hurlbert RJ. Expansive Duraplasty - Simple Technique with Promising Results in Complete Cervical Spinal Cord Injury: A Preliminary Study. *Neurol India*. 2022;70:319–24. <https://doi.10.4103/0028-3886.338668> .
38. Yahanda AT, Limbrick DDJ. Posterior Fossa Decompression with or Without Duraplasty for Chiari I Malformation. *Neurosurg Clin N Am*. 2023;34:105–11. [https://doi.S1042-3680\(22\)00078-X](https://doi.S1042-3680(22)00078-X) [pii].
39. Chotai S, Medhkour A. Surgical outcomes after posterior fossa decompression with and without duraplasty in Chiari malformation-I. *Clin Neurol Neurosurg*. 2014;125:182–8. <https://doi.10.1016/j.clineuro.2014.07.027> .
40. Khurana D, Suresh A, Nayak R, Shetty M, Sarda RK, Knowles JC, et al. Biosubstitutes for dural closure: Unveiling research, application, and future prospects of dura mater alternatives. *J Tissue Eng*. 2024;15:20417314241228118. <https://doi.10.1177/20417314241228118>.

41. Saadoun S, Grassner L, Belci M, Cook J, Knight R, Davies L, et al. Duroplasty for injured cervical spinal cord with uncontrolled swelling: protocol of the DISCUS randomized controlled trial. *Trials*. 2023;24:497–2. <https://doi.10.1186/s13063-023-07454-2>.
42. Denchev K, Gomez J, Chen P, Rosenblatt K. Traumatic Brain Injury: Intraoperative Management and Intensive Care Unit Multimodality Monitoring. *Anesthesiol Clin*. 2023;41:39–78. <https://doi.10.1016/j.anclin.2022.11.003>.
43. Hogg FRA, Kearney S, Zoumprouli A, Papadopoulos MC, Saadoun S. Acute Spinal Cord Injury: Correlations and Causal Relations Between Intraspinal Pressure, Spinal Cord Perfusion Pressure, Lactate-to-Pyruvate Ratio, and Limb Power. *Neurocrit Care*. 2020; <https://doi.10.1007/s12028-020-00988-2>.
44. Saadoun S, Papadopoulos MC. Spinal cord injury: is monitoring from the injury site the future?. *Crit Care*. 2016;20:308–3. <https://doi.10.1186/s13054-016-1490-3>.
45. Hogg F, Kearney S, Solomon E, Gallagher MJ, Zoumprouli A, Papadopoulos MC, et al. Acute, severe traumatic spinal cord injury: improving urinary bladder function by optimizing spinal cord perfusion. *J Neurosurg Spine*. 2021:In press.
46. Visagan R, Boseta E, Zoumprouli A, Papadopoulos MC, Saadoun S. Spinal cord perfusion pressure correlates with breathing function in patients with acute, cervical traumatic spinal cord injuries: an observational study. *Crit Care*. 2023;27:362–y. <https://doi.10.1186/s13054-023-04643-y>.
47. Saadoun S, Chen S, Papadopoulos MC. Intraspinal pressure and spinal cord perfusion pressure predict neurological outcome after traumatic spinal cord injury. *J Neurol Neurosurg Psychiatry*. 2017;88:452–3. <https://doi.10.1136/jnnp-2016-314600>.

48. Kwon BK, Tetreault LA, Martin AR, Arnold PM, Marco RAW, Newcombe VFJ, et al. A Clinical Practice Guideline for the Management of Patients With Acute Spinal Cord Injury:

Recommendations on Hemodynamic Management. *Global Spine J.* 2024;14:187S–211S.

<https://doi.10.1177/21925682231202348>.

49. Hutchinson PJ, Koliass AG, Timofeev IS, Corteen EA, Czosnyka M, Timothy J, et al.

Trial of Decompressive Craniectomy for Traumatic Intracranial Hypertension. *N Engl J Med.*

2016;375:1119–30. <https://doi.10.1056/NEJMoa1605215> .

Journal Pre-proof

Figure Legends

Fig. 1. Monro-Kellie doctrine applied to TSCI. **A.** CSF around injury site. Further swelling of spinal cord displaces CSF and does not increase ISP at the injury site. **B.** Injury site in contact with dura. Further swelling of spinal cord begins increase ISP at the injury site. **C.** Injury site in compressed against dura. Further swelling of spinal cord causes exponential increase ISP at the injury site.

Fig. 2. Compartmentalisation at injury site. T2 sagittal MRIs of 3 patients showing swollen spinal cords compressed against dura. Compression creates 4 compartments, each having a different pressure: CSF above, extradural, injury site (ISP), and CSF below (ITP).

Fig. 3. Spinal cord pressure reactivity index (sPRx). **A.** sPRx vs. ISP, and **B.** sPRx vs. SCPP, for two patients (white dots, black dots) with different SCPP_{opt} at 66 and 82 mmHg.

Fig. 4. Example of an expansion duroplasty with ISP and microdialysis probes *in situ*.

Intraoperative photo taken under a surgical microscope.

Table1. DISCUS trial inclusion and exclusion criteria

INCLUSION	EXCLUSION
Age 16 years or older	Probable dural tear due to TSCI
Cervical (C2 – T1) TSCI	Life limiting or rehabilitation restricting co-morbidities
AIS Grade A-C	Thoracic or lumbar TSCI
Deemed to require and be suitable for surgery that includes laminectomy by local surgeons	Other CNS disease
Surgery within 72 hours of TSCI	

AIS, American spinal injury association Impairment Scale; CNS, central nervous system; TSCI, traumatic spinal cord injury

Table 2. Analogies between traumatic brain injury and traumatic spinal cord injury.

TRAUMATIC BRAIN INJURY	TRAUMATIC SPINAL CORD INJURY
ICP, Intra Cranial Pressure	ISP / ITP, Intraspinal pressure / Intrathecal pressure
CPP, Cerebral Perfusion Pressure	SCPP, Spinal Cord Perfusion Pressure
PR _x , Pressure Reactivity Index	sPR _x , spinal Pressure Reactivity Index
CPP _{opt} , Optimum Cerebral Perfusion Pressure	SCPP _{opt} , Optimum Spinal Cord Perfusion Pressure
RAP, Compensatory Reserve Index	sRAP, spinal Compensatory Reserve Index
P1 P2 P3, peaks on normal ICP waveform	P1 P2 P3, peaks on normal ISP waveform
Decompressive craniectomy	Laminectomy + duroplasty

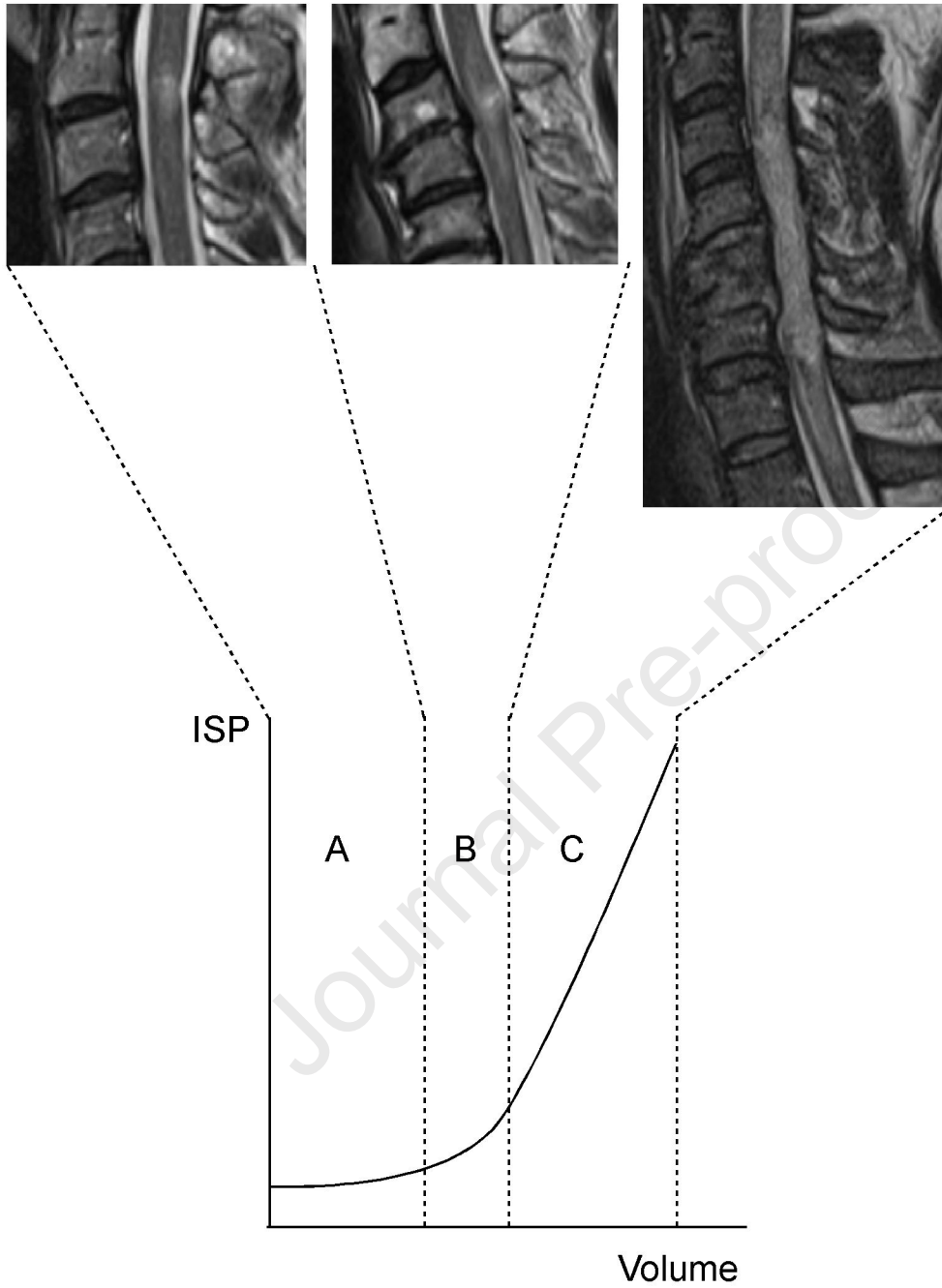


FIGURE 1

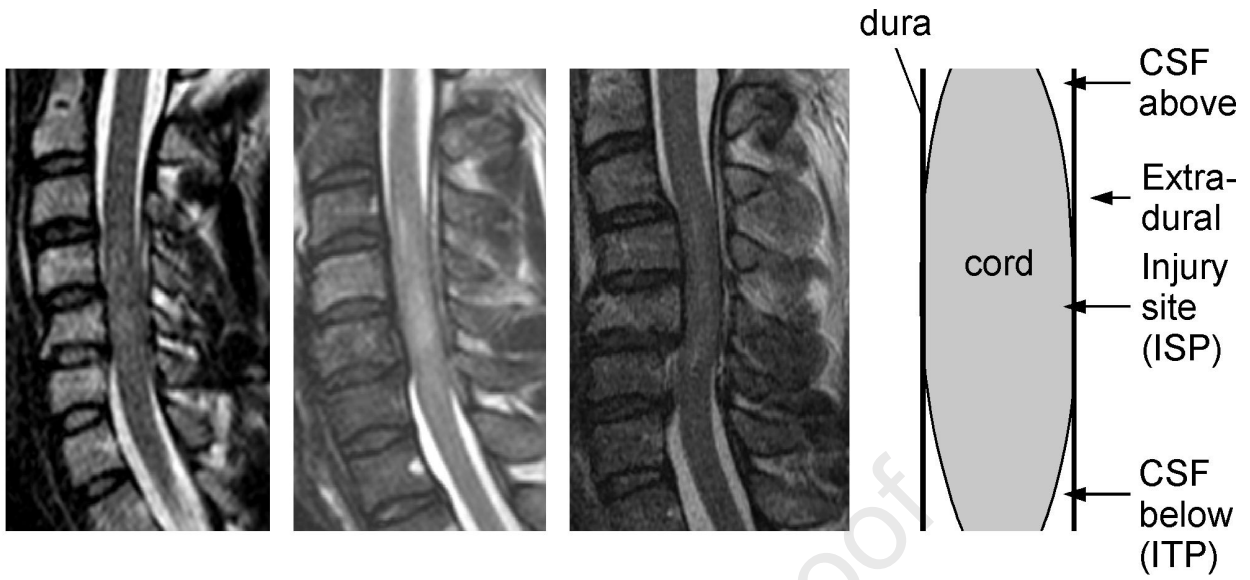


FIGURE 2

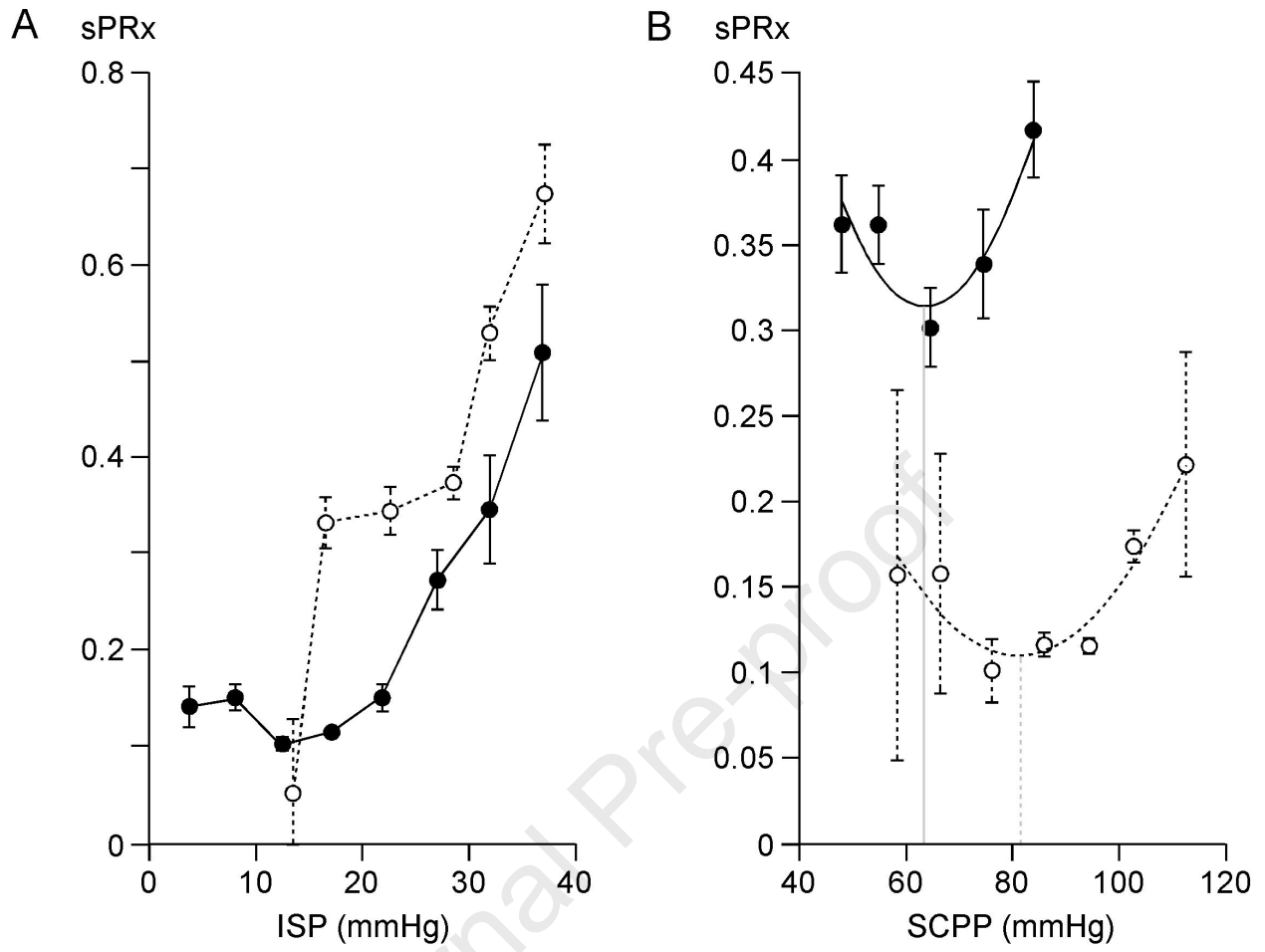


FIGURE 3

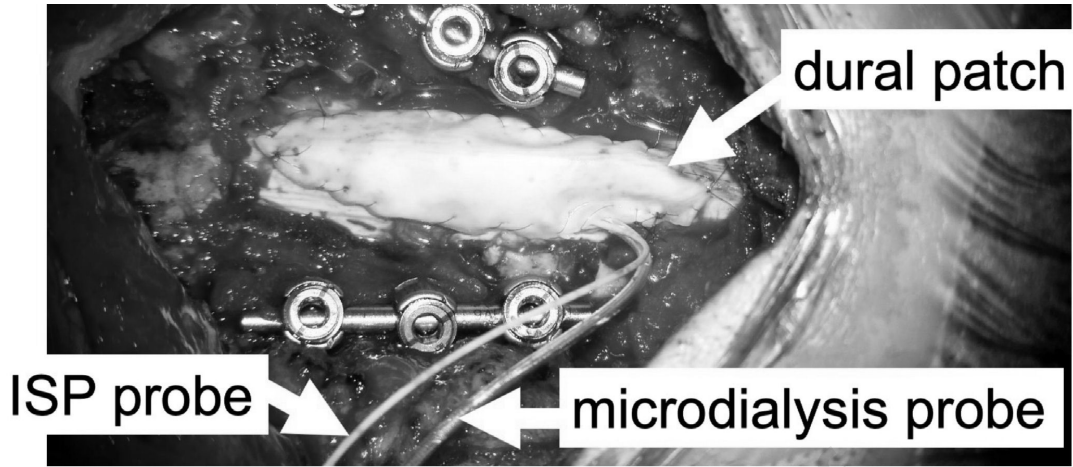


FIGURE 4

Highlights

- Blood pressure targets for managing acute spinal cord injury are inadequate.
- Monitoring intraspinal pressure and spinal cord perfusion pressure, help management of acute spinal cord injury in the Intensive Care Unit.
- The Monro-Kellie doctrine, a fundamental principle in traumatic brain injury, also applies in spinal cord injury.
- Draining lumbar cerebrospinal fluid and expansion duroplasty are currently undergoing clinical trials as novel therapies for acute spinal cord injury.
- It is unclear whether spinal cord pressure is best measured from the injury site or from the lumbar cerebrospinal fluid.

Critical care unit

Ischemia

Monitoring

Perfusion

Probe

Spinal cord injury

Journal Pre-proof

Declaration of interests

The authors declare that they have no known competing financial interests or personal relationships that could have appeared to influence the work reported in this paper.

The authors declare the following financial interests/personal relationships which may be considered as potential competing interests:

Samira Saadoun, Hasan Asif, Marios C. Papadopoulos
30 June 2024

Journal Pre-proof