

Navigating paediatric virology through the COVID-19 era (Review)

IOANNIS N. MAMMAS¹⁻³, SIMON B. DRYSDALE^{4,5}, CHARALAMPOS CHARALAMPOUS⁶, PATRA KOLETISI^{7,8}, ALEXIA PAPTHERODOROPOULOU⁹, CHRYSISS KOUTSAFTIKI^{10,11}, THEODOROS SERGENTANIS¹¹, KYRIAKOULA MERAKOU¹¹, HELEN KORNAROU¹¹, GEORGIA PAPAIOANNOU¹², ANNA KRAMVIS¹³, ANNE GREENOUGH¹⁴, MARIA THEODORIDOU² and DEMETRIOS A. SPANDIDOS¹

¹Department of Clinical Virology, School of Medicine, University of Crete, 71003 Heraklion; ²First Department of Paediatrics, School of Medicine, University of Athens, 11527 Athens; ³Paediatric Clinic, Aliveri, 34500 Island of Euboea, Greece; ⁴Centre for Neonatal and Paediatric Infection, St. George's, University of London, London SW17 0RE;

⁵Department of Paediatrics, St. George's University Hospitals NHS Foundation Trust, London SW17 0QT, UK;

⁶Kliniken Maria Hilf GmbH, 41063 Mönchengladbach, Germany; ⁷Department of Paediatrics, and

⁸Paediatric Intensive Care Unit (PICU), 'Penteli' Children's Hospital, 15236 Palaia Penteli; ⁹Paediatric Intensive Care Unit (PICU), University Hospital of Patras, 26504 Rio; ¹⁰COVID-19 Reference Centre, 'Rafina' Health Care Centre, 19009 Rafina;

¹¹Department of Public Health Policy, School of Public Health, University of West Attica, 11521 Athens; ¹²Department of Paediatric Radiology, 'Mitera' Children's Hospital, 15123 Athens, Greece; ¹³Hepatitis Virus Diversity Research Unit, Department of Internal Medicine, School of Clinical Medicine, University of the Witwatersrand, 2193 Johannesburg, South Africa; ¹⁴Division of Asthma, Allergy and Lung Biology, King's College London, London SE5 9RS, UK

Received May 9, 2023; Accepted July 12, 2023

DOI: 10.3892/ijmm.2023.5286

Abstract. The present review article presents the key messages of the 8th Workshop on Paediatric Virology organised virtually by the Institute of Paediatric Virology based on the island of Euboea in Greece. The major topics covered during the workshop were the following: i) New advances in antiviral agents and vaccines against cytomegalovirus; ii) hantavirus nephropathy in children; iii) human rhinovirus infections in children requiring paediatric intensive care; iv) complications and management of human adenovirus infections; v) challenges of post-coronavirus disease 2019 (COVID-19) syndrome in children and adolescents; and vi) foetal magnetic resonance imaging in viral infections involving the central nervous system. The COVID-19 era requires a more intensive, strategic, global scientific effort in the clinic and in the laboratory, focusing on the diagnosis, management and prevention of viral infections in neonates and children.

Contents

1. Introduction
2. Developing antiviral agents and vaccines against cytomegalovirus: New advances
3. Hantavirus nephropathy in children: Cases in Europe
4. Human rhinovirus infections requiring paediatric intensive care
5. Complications and management of human adenovirus infections in children
6. Post-COVID-19 syndrome in children and adolescents: Exploring current terminology, symptomatology and management
7. Foetal magnetic resonance imaging and viral infections: Indications and findings
8. Conclusions and future perspectives

1. Introduction

The recent coronavirus disease 2019 (COVID-19) pandemic has prioritised multifaced international scientific effort for adequate, state-of-the-art, health and medical care, worldwide (1). The COVID-19 era has been a very demanding and challenging period for all individuals, including paediatric health professionals, newborns, children and parents (2). Moreover, it has highlighted the value of multi-disciplinary international scientific cooperation and medical education, including online learning using virtual, hybrid teaching modes (3). Paediatric viral infections continue to represent

Correspondence to: Professor Demetrios A. Spandidos, Department of Clinical Virology, School of Medicine, University of Crete, Voutes, 71003 Heraklion, Greece
E-mail: spandidos@spandidos.gr

Key words: paediatric virology, vaccines, antiviral agents, cytomegalovirus, hantavirus, rhinovirus, adenovirus, post-COVID-19, magnetic resonance imaging, children

an educational, clinical and research field with increasing needs and future perspectives. The present review describes the key messages addressed during the recent 8th Workshop on Paediatric Virology, which was organised through the COVID-19 era by the Institute of Paediatric Virology (IPV; <https://www.paediatricvirology.org>) on October 20, 2022 (4). The workshop was coordinated virtually by the Paediatric Virology Study Group (PVSG); this is the third year that this workshop adopted a hybrid format and did not require the physical presence of its participants due to the COVID-19 pandemic (5,6). The workshop focused on the following factors: i) New advances in antiviral agents and vaccines against cytomegalovirus (CMV); ii) hantavirus nephropathy in children; iii) human rhinovirus (HRV) infections in children requiring paediatric intensive care; iv) complications and management of human adenovirus (HAdV) infections; v) challenges of post-COVID-19 syndrome (PCS) in children and adolescents and vi) foetal magnetic resonance imaging (MRI) in viral infections involving the central nervous system (CNS) (Table I).

In the context of the workshop, Professor Anna Kramvis, Professor of Virology at the University of the Witwatersrand (Johannesburg, South Africa), was awarded (2022 Paediatric Virology Award) for her outstanding academic, research, teaching and publishing contribution in hepatitis B virus research in Africa (7-9). Dr Fergus Maher, Consultant in Palliative Medicine at the Norfolk and Norwich University Hospitals, NHS Foundation Trust (Norwich, UK) and Honorary Associate Professor in Palliative Medicine at the Norwich Medical School of the University of East Anglia (Norwich, UK), was also awarded (2022 George N. Papanicolaou Humanitarian Award) due to his state-of-the art clinical and academic contribution to palliative medicine in the UK (10).

2. Developing antiviral agents and vaccines against cytomegalovirus: New advances

CMV causes one of the most common infections globally, with most individuals being infected at some point in life (11). For most, it results in a mild, self-resolving illness that leads to lifelong, latent infection. However, for some high-risk individuals, such as those who are immunocompromised, CMV infection can result in severe disease and even mortality (12). In addition, foetuses infected *in utero* can develop congenital CMV infection with sequelae ranging from asymptomatic infection through to multiorgan failure, severe neurodisability and mortality (13). To date, several antiviral medications are already available to treat CMV infection. Ganciclovir, valganciclovir, foscarnet and cidofovir have been used for a number of years (12,13). Aciclovir/valaciclovir, primarily used to treat varicella-zoster virus (VZV) and herpes simplex virus (HSV) infections, have activity against CMV infection and are used to treat pregnant women to reduce the risk of transmission of CMV to the foetus; the antivirals acyclovir/valaciclovir are less toxic than other CMV antivirals (14). Different doses for each medication have been suggested for different clinical scenarios (e.g., congenital CMV infection, immunocompromised children, those with renal issues, prematurity and various ages) (12-14). Newer agents, such as brincidofovir, letermovir and maribavir, have recently been developed, although their

use remains limited (15). Novel antivirals are in early-stage development. These include classes of small molecules, such as distinct acyclic nucleoside phosphonate analogues, non-nucleoside inhibitors of DNA polymerase, monoclonal antibodies, and host-targeted antivirals, such as sirtuins (16). The pipeline for CMV antivirals is certainly very promising.

The search for a CMV vaccine has been ongoing for a number of decades; however, new vaccine platforms, particularly those developed during the COVID-19 pandemic have recently led to significant advances. CMV vaccines are being designed to target two key groups, namely women of child-bearing potential/pregnant women, to try to reduce the burden of congenital CMV, and those who are severely immunosuppressed, to prevent the complications of acute and chronic CMV infection in this population. There are three main vaccines in clinical development. The first, and currently most promising, is a mRNA-based CMV vaccine, which uses the same technology as that used in some of the COVID-19 vaccines. This vaccine is being studied in several ongoing phase 1-3 clinical trials in healthy adults and adolescents and patients, who have received a haemopoietic stem-cell transplant to assess safety, immunogenicity and efficacy potential [for further information please visit the official website of the National Institutes of Health (NIH), US National Library of Medicine, ClinicalTrials.gov: <https://clinicaltrials.gov/ct2/results?cond=CMV&term=vaccine%2C+Moderna&cntry=&state=&city=&dist=&Search=Search>]. Results from these studies are expected over the ensuing years. A conditionally replication-defective CMV vaccine (17) was recently assessed in a phase 2 clinical trial in women of child-bearing potential (for further information visit the official website of the NIH, U.S. National Library of Medicine, ClinicalTrials.gov: <https://clinicaltrials.gov/ct2/show/NCT03486834>). It was shown to be safe and immunogenic, and reduced the quantity and duration of CMV shedding in those who received three doses of the vaccine (18). However, neither the three-dose nor the two-dose regimen demonstrated significant efficacy against CMV infection (18). It is unclear whether the development of this vaccine will continue. The third is a CMV recombinant protein subunit vaccine consisting of a combination of glycoprotein B and pentamer antigens, being evaluated in a phase 1 clinical trial in healthy adults (for further information visit the official website of the NIH, US National Library of Medicine, ClinicalTrials.gov: <https://clinicaltrials.gov/ct2/show/NCT05089630?term=vaccine%2C+gsk&cond=CMV&draw=2&rank=3>). Although there is clearly a long road ahead, advances in vaccine development consequent to the COVID-19 pandemic, suggest that the prospect of a licensed CMV vaccine is becoming increasingly promising.

3. Hantavirus nephropathy in children: Cases in Europe

In children, hantaviruses can cause a wide spectrum of clinical manifestations, which have recently been grouped into two clinical syndromes: i) Haemorrhagic fever with renal syndrome (HFRS), which is endemic in Europe; and ii) hantavirus cardiopulmonary syndrome (19-22). Children can be infected following exposure to aerosolized urine, droppings or saliva of infected rodents or following exposure to dust from their nests; rodents are the main hosts of hantaviruses. The

Table I. Top key messages of the 8th Workshop on Paediatric Virology.

Topic	Key messages
CMV	<p>CMV is a common infection in neonates and children and has a significant healthcare burden. Several antivirals are available with more in development; different doses for each medication have been suggested for different clinical scenarios (e.g., congenital CMV infection, immunocompromised children, those with renal issues, prematurity and various ages).</p> <p>There are CMV vaccines in the pipeline although one getting to licensure is several years away at least.</p>
Hantavirus	<p>Hantaviruses should be considered as possible causes of interstitial nephritis with decreased GFR in children even in areas with a low incidence of this infection.</p> <p>In children with fever, thrombocytopenia and haematuria or proteinuria, differential diagnosis should include hantavirus induced nephropathy.</p>
HRV	<p>HRVs have been recently associated with increased morbidity, hospitalisation rates and PICU admissions; recent advances in NGS analyses have highlighted the significant burden in PICU admissions due to SARI caused by HRV as well as CNS disease and MODS.</p> <p>As there is no antiviral-specific treatment for HRV, recognition of signalling pathways involved and the profiling of patients according to disease phenotypes may lead the way to future treatment modalities in hyperinflammatory antiviral response.</p>
HAdV	<p>HAdVs are common causes of self-limited febrile illnesses in young children; however, in some cases, it may lead to disseminated disease, which requires hospitalisation and intensive management with antivirals and immunotherapy.</p> <p>The most common adenovirus infection in healthy children involves the respiratory system and eyes; outbreaks of epidemic keratoconjunctivitis can occur in hospitals due to the rapid transmission of HAdVs via the hands of health care workers, contaminated instruments or eye drops.</p> <p>Neonates and immunocompromised individuals are at a risk of increased morbidity and mortality; in these groups antiviral therapy with cidofovir, ganciclovir, ribavirin and vidarabine has been used in case reports or uncontrolled series, leading to inconclusive evidence for efficacy.</p>
SARS-CoV-2	<p>PCS appears to be an existing entity in the paediatric population; its prevalence is as yet undetermined and can occur in SARS-CoV-2 positive children, even if asymptomatic; the most frequent symptoms are headache, fatigue-weakness, sleep disturbances, cognitive disorders and myalgia-arthralgia.</p> <p>The clarification of PCS diagnostic criteria and management may help to improve the health of young patients and guide health policy makers.</p>
Foetal MRI and viral infections	<p>Congenital infections represent a serious cause for foetal CNS injury with serious sequelae in the neonate.</p> <p>In the case that maternal viral infection is suspected, combining prenatal ultrasound and foetal MRI may document the extent of tissue damage and therefore contribute to treatment and counselling.</p>

CMV, cytomegalovirus; GFR, glomerular filtration rate; HRV, human rhinovirus; PICU, paediatric intensive care unit; NGS, next-generation sequencing; SARI, severe acute respiratory infections; CNS, central nervous system; MODS, multiple organ dysfunction syndrome; HAdV, human adenovirus; SARS-CoV-2, severe acute respiratory syndrome coronavirus type 2; PCS, post-COVID-19 syndrome; COVID-19, coronavirus disease 2019; MRI, magnetic resonance imaging.

virus is transmitted through the exposure of injured skin or mucous membranes (eyes or nose) to these materials; transmission from one human to another has rarely been described; however, it is not impossible (19-22).

HFRS usually appears between the 7th and the 14th day after contact with the virus through the infectious material, although in some occasions, it may take up to 2 months to manifest. Symptoms of the acute phase include intense

headaches, back and abdominal pain, fever, chills, nausea and blurred vision. Affected patients may experience flushing of the face, inflammation or redness of the eyes, or a rash. Low blood pressure, acute shock and acute kidney injury can appear later on. Each virus is responsible for different manifestations of the illness (23-25). The *Hantaan* and *Dobrava* viruses are associated with severe disease, while the *Seoul*, *Saaremaa* and *Puumala* virus can cause milder symptoms. The recovery can

vary from several days to months. The key to the diagnosis of HFRS is the detection of hantavirus RNA sequences in blood or tissue. The optimal strategy with which to control the disease is by treating the basic symptoms and supporting the patient with the management of fluids and electrolytes; in the case that this is not applicable, dialysis may be used. Intravenous ribavirin has been shown to decrease illness and mortality associated with HFRS, if used in the very early stages of the disease (26,27).

Cases in Europe. Dusek *et al* (28) referred to the first three children with *Puumala* virus nephropathy diagnosis in the Czech Republic. A boy and two girls were diagnosed with interstitial nephritis. Their initial symptoms were similar to those of the 'common cold'. The children presented with mild fever and a high erythrocyte sedimentation rate and C-reactive protein levels, and low haemoglobin levels (28). Kidney injury was verified by the presence of proteinuria, the high serum creatinine levels and a renal biopsy. The serological tests for *Puumala* virus antigen antibodies were positive. All children reacted positively to the supportive therapy, which led to a clinical improvement within 1 month (28). van der Werff ten Bosch *et al* (29) described a young girl from Belgium diagnosed with hantavirus infection; in that case, the main symptoms and signs were high fever, proteinuria, haematuria and eye lesions. No kidney injury or haematological discrepancies were documented. The diagnosis was based on the detection of hantavirus in the blood tests. No specialised therapy was required and the child had a rapid recovery (29). Eboriadou *et al* (30) described a case of an 11-year-old boy from Northeastern Greece with haemorrhagic fever with HFRS caused by hantavirus infection. The child presented with a mild fever with total lack of other symptoms. The creatinine and urea levels progressively increased to 23 and 930 mg/l, respectively, accompanied with oligoanuria, proteinuria and haematuria. The glomerular filtration rate (GFR) was 47.3 ml/min. The IgG *Hantaan* viral antibody titer was 1:2,048; no IgM antibody titer was quantified. The symptomatic therapy with fluids and electrolytes was in this case of crucial significance and concluded to a complete renal recovery after 6 months of follow-up.

4. Human rhinovirus infections requiring paediatric intensive care

HRV of the *Enterovirus* genus, belonging to the family *Picornaviridae*, has been traditionally recognised as the 'common cold' pathogen. However, the association with severe acute respiratory infection (SARI) in children needs to be highlighted as there is increasing evidence to indicate the implication of HRV with increased rates of hospitalisation and paediatric intensive care unit (PICU) admissions (31-33). Of note, a prospective cohort study including >600 infants linked severe HRV-associated respiratory tract illness with maternal atopic disease and HRV species, with HRV group B being associated with longer hospital stay (34). Similarly, other authors have highlighted the presence of comorbidities, such as bronchopulmonary dysplasia, a very low birth weight and congenital heart disease, as significant risk factors for SARI caused by HRV (35-37).

To date, an increasing number of studies have shown the increased rate of HRV in PICU admissions due to SARI in paediatric, as well as adult populations (31-39). In a recent retrospective study, Smith and Wilson (33) demonstrated that 1 in 3 children with HRV infection admitted to a PICU had severe respiratory insufficiency, and 14% of these children met the diagnostic criteria for paediatric acute respiratory distress syndrome (ARDS). Similarly, Spaeder *et al* (38) conducted a multicentre cohort study, including 519 patients with HRV infection admitted to a PICU, providing insightful morbidity and mortality data. It is worth noting, however, that 12.5 and 6.4% of the patients had viral and bacterial coinfection, respectively (38). In the same study (38), clinical presentation to the PICU consisted of wheezing (36%), apnoea (3%), stridor or croup (1.2%) and seizures (3%). In addition, 1 in 4 patients required mechanical ventilation, 3% were diagnosed with multiple organ dysfunction syndrome (MODS), 2% developed ARDS and 2 patients underwent extracorporeal membrane oxygenation; the mortality rate was 2%. Notably, HRV infection prevailed in PICU admissions among other usual suspects, such as respiratory syncytial virus (RSV) and influenza viruses (38). Finally, Asner *et al* (32) conducted a retrospective cohort study in 750 children randomly selected from a cohort of >5,000 outpatients, exploring the clinical severity of single positive HRV cases compared with other viral infections. They concluded that children with HRV had a more severe course of disease than those with RSV and influenza A and B, and often had significant comorbidities, such as cardiorespiratory, metabolic and immunocompromise that also leading to a relatively higher mortality rate (4.7%) (32). Of note, during the past decade, HRV C, a previously unrecognised genogroup of HRVs, has been discovered and linked to severe respiratory illness associated with PICU admission, mechanical ventilation support and prolonged hospital stay in addition to its association with the exacerbation of asthma (39-41).

Furthermore, HRV infection has been implicated in critical illness with extrapulmonary complications, mainly CNS involvement and multiple organ dysfunction (42). Liu *et al* (43) described the case of a 10-year-old female patient without comorbidities infected with HRV, who presented with seizures attributed to significant diffuse encephaloedema, and subsequently developed septic shock requiring intubation, inotropes support and continuous renal replacement treatment. She had a prolonged hospital stay of 75 days and her MODS was attributed to HRV A45 confirmed by metagenomic next-generation sequencing (NGS) (43). Similar cases have been reported in previously healthy children, whereas in a large analysis of unexplained cases of encephalitis using metatranscriptomic sequencing, HRV was implicating in a considerable proportion of them (44,45). Triantafilou *et al* (46) attempted to elucidate the mechanism of host hyperinflammatory response to HRV via translational studies in human cell lines. According to their experimental results, the Toll-like receptors (TLR) 2, 7 and 8 and melanoma differentiation-associated (MDA) protein 5 signalling pathways mediated the recognition of the virus in non-immune cells, which further triggered a synergistic pro-inflammatory cytokine release and hyperinflammatory phenotype, components that may be targeted for future treatment modalities (46).

5. Complications and management of human adenovirus infections in children

First isolated in the 1950s, HAdVs are double-stranded DNA viruses, which consist of a family (*Adenoviridae*) of >60 serotypes, divided into seven subgroups, A to G (47). Certain serotypes are associated with distinct clinical manifestations, reflecting preferential infection of the respiratory, gastrointestinal and urinary tracts and conjunctiva; however, the majority of infections are asymptomatic (47). HAdVs are among the most common viruses isolated from young children with febrile illness. Pharyngitis, exudative tonsillitis, otitis media, bronchiolitis and pneumonia are common presentations of respiratory tract infections. There is a high incidence of pulmonary sequelae following adenoviral pneumonia in young children, including restrictive lung disease, bronchiectasis and bronchiolitis obliterans (48). Extrapulmonary complications include meningoencephalitis, hepatitis, myocarditis, nephritis, neutropenia and disseminated intravenous coagulation (47).

Pharyngoconjunctival fever is a classic adenoviral syndrome that consists of a benign conjunctivitis often accompanied by a febrile pharyngitis and cervical adenitis (47,49). Outbreaks have been described, particularly in summer camps and swimming pools. Epidemic keratoconjunctivitis is a more severe disease characterized by bilateral conjunctivitis with preauricular adenopathy, followed by the development of painful corneal opacities. It may be transmitted in hospitals via the hands of healthcare workers, contaminated instruments or eye drops. As previously demonstrated, in a neonatal intensive care unit, an outbreak of HAdV type 8 conjunctivitis occurred in seven premature infants who had undergone ophthalmological examination (49). In an American study by Bowles *et al* (50), polymerase chain reaction (PCR) testing identified HAdV as the most detected virus in the myocardium of children and adults with acute myocarditis and dilated cardiomyopathy.

It is unclear whether HAdV infection is a cause of the recent 2022 outbreak of unexplained hepatitis in children. As of July 8, 2022, 35 countries had reported to the World Health Organization (WHO) probable cases of children with severe acute hepatitis of unknown aetiology (51). To date, there is no established link with COVID-19 or hepatitis viruses A, B, C, D and E. Although HAdV serotype 41 was detected by PCR in 65% of the tested cases in the UK and 44.6% in the USA (52), it remains uncertain whether the virus is the causative agent, as HAdV does not typically cause hepatitis in healthy children. Preprints from the UK suggest that co-infection with HAdV-associated virus 2, a member of the parvovirus family may play a role (53); however, additional studies are required to confirm this. Management includes supportive therapy and treatment of coagulopathy disorders and hepatic encephalopathy (51).

HAdVs are rare causes of CNS disease, particularly in immunocompetent children. The diseases spectrum is highly variable, ranging from febrile seizures and mild aseptic meningitis to severe, acute necrotizing encephalopathy, leading to death. In a retrospective study by Schwartz *et al* (54) conducted at the Hospital for Sick Children (Toronto, Canada), 5% of children with microbiologically confirmed HAdV infection had neurologic symptoms with an encephalitis

incidence of 0.4%; alternatively, 1.9% of encephalitis cases were attributed to HAdV. (54). In another paediatric study from Taiwan by Huang *et al* (55), a similar rate (3.3%) of children with culture-confirmed HAdV infections had symptoms or signs of neurological dysfunction. Notably, in the study by Schwartz *et al* (54), HAdV in cerebrospinal fluid or brain tissue was only isolated in 15% of the cases; the most prevalent recorded serotype was type 7, followed by serotypes 3 and 2. Complex seizures, coagulopathy, younger age and serotype 2 were associated with adverse outcomes.

Hemophagocytic lymphohistiocytosis (HLH) is a life-threatening condition of immune dysregulation (56,57). It is characterized by a prolonged fever, hepatosplenomegaly, cytopenia and abnormal laboratory tests, including elevated levels of aspartate aminotransferase, alanine transaminase, triglycerides, ferritin and serum soluble interleukin-2 receptor. Young children often have a genetic predisposition for primary or familial HLH, while others suffer from secondary HLH as a complication of infection, malignancy or rheumatologic disease. In the literature, there are few reports on HAdV-associated HLH in healthy children (56,57). Otto *et al* (56) described five cases of HAdV 7 associated HLH and HLH-like illness in children aged 2 months-16 years old during the 2018-2019 season. In another report (57), two neonates with disseminated HAdV infection, developed ARDS and cardiovascular failure attributed to virus-related HLH. No specific therapeutic protocols have been established; however, intravenous immunoglobulin, dexamethasone, cyclosporin A, etoposide and methotrexate have been used with beneficial effects.

HAdVs can cause disease during the post-transplantation period in patients who have received haematopoietic stem cell or solid organ transplants (58). The spectrum of infection ranges from asymptomatic shedding to fatal disseminated disease. Common manifestations include pneumonia, hepatitis, haemorrhagic cystitis/nephritis (accompanied by acute renal failure at ~90%), colitis and encephalitis. In a retrospective study by Munoz *et al* (58), 11 of 440 children with HAdV infection had disseminated disease; among these, 54% (6 of 11) were immunocompromised. Mortality from disseminated disease was 73%, overall (83% among immunocompromised and 60% among immunocompetent hosts).

The majority of HAdV infections are self-limiting and treatment is supportive. Patients with CNS involvement, severe respiratory disease, severe keratitis and immunosuppression require hospitalisation. Neonates and immunocompromised individuals are at a risk of increased morbidity and mortality. In these groups, antiviral therapy with cidofovir, ganciclovir, ribavirin and vidarabine has been used in case reports or uncontrolled series; however, the evidence of efficacy is inconclusive (59). Cidofovir appears more efficient against HAdV than other antiviral drugs, although severe nephrotoxicity is a major dose-limiting adverse event. In a retrospective study on 45 patients with HAdV infection following allogeneic haematopoietic stem cell transplantation, 69% were successfully treated with cidofovir, even though 40% experienced toxicity (60). Intravenous immunoglobulin has also been used in conjunction with antivirals (61). T-cell immunity is critical for the recovery from HAdV infection following haematopoietic stem cell transplantation. The rapid transfer of donor-derived,

virus-specific memory T-cells offers substantial promise in controlling severe disease with low adverse effects in those with intolerance or nonresponse to antivirals. In the study by Leen *et al* (62), the treatment of HAdV infections in 17 paediatric stem cell transplant recipients with banked third-party virus-specific T-cells from individuals with common human leukocyte antigen polymorphisms, resulted in a complete or partial response in 78% of patients; 7 patients with complete response and 7 patients with partial response.

6. Post-COVID-19 syndrome in children and adolescents: Exploring current terminology, symptomatology and management

Even though acute severe acute respiratory syndrome coronavirus 2 (SARS-CoV-2) infection has proven to be a mild disease for the majority of children, it has been recognized that symptoms from various systems may persist, re-emerge or recur months following the acute phase, constituting the PCS or 'long COVID' (Fig. 1). This syndrome, which has been described primarily in adults, was first mentioned in May 2020 on Twitter by patients themselves (adults), trying to communicate inexplicable symptoms following acute SARS-CoV-2 infection, that made their everyday living difficult (63). In September 2020, WHO established the codes U09 in the International System of Classification of Diseases (ICD-10 and ICD-11) for this new condition (64) without mentioning the children. Once again, in November, 2020, the media highlighted that children may also be affected by PCS (65). Since then, there have been numerous attempts made to define this new condition, mainly for the adults, but lately also for the children, the most acceptable of which are presented in Table II.

To date, numerous terms have been used in order to describe this syndrome, such as 'long-haulers', 'long COVID', 'post-acute sequelae of COVID-19 (PASC)', 'post-COVID', 'long term effects of COVID', 'long-post-COVID' and 'chronic COVID' (66,67). Symptoms and signs from almost all systems have been reported, including cardiovascular (chest pain, palpitations, orthostatic intolerance), neurological-neuropsychiatric (brain fog, concentration disorders, sleep disorders, headaches, memory disorders, behavioural disorders, irritability, smell/taste disorders, dizziness, night sweats, anxiety, depression, convulsions), dermatological (rash, chilblains), gastrointestinal (abdominal pain, epigastric pain, diarrhoea, vomiting), musculoskeletal (myalgia, arthralgia), respiratory (cough, dyspnoea, sore throat, nasal congestion), haematological (coagulation disorders, haemorrhagic diathesis) and endocrinological (hyperglycaemia) (68-70).

The reported prevalence varies widely, from <4 to >66%, depending on the symptom and the methodology of the study (68,71-73). The most frequently reported symptoms are headache, fatigue-weakness, sleep disturbances, cognitive disorders and myalgia-arthralgia (71). Lower prevalence rates (<2-3%) are usually observed in children with no history of hospitalisation and mild-to-moderate disease, whereas higher rates (>10%) are recorded in children with more severe disease, with comorbidities, who may have been hospitalised (72,74). Therefore, it is crucial for studies to specify the level of severity of the initial disease. Of note however, numerous children with

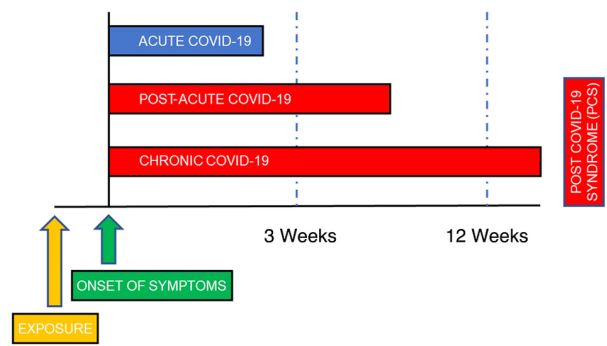


Figure 1. Classification of post-COVID-19 syndrome.

a negative history of infection also exhibit symptoms, such as anxiety, sleep disturbances, headaches and a decline in mental functions, attributed to the COVID-19 pandemic itself (75,76).

The clinical spectrum of PCS should be treated with ample attention, whether originating from pathophysiological alterations, or it is the result of increased stress and aggravation of pre-existing psychological issues, which developed due to the pandemic. The question that remains unanswered, is which is the most appropriate management of those individuals who believe they are suffering from it. The majority of studies focus on the care of the adult population, and propose the provision of supportive, holistic, individualized treatment of people with PCS, initially at primary care level, but with immediate referral to specialists whenever serious conditions emerge (77).

For the paediatric population, some advocate that there should be a clinical assessment of children with a history of SARS-CoV-2 infection, either confirmed or suspected, 4-12 weeks after the primary infection (78,79). During the first visit, a clinical examination should be performed and a detailed history should be taken, aiming to detect symptoms, even of low intensity, that make the daily lives of children difficult and may not have been evaluated properly, either by the child, or by the caregiver (68,73,78). Subsequently, there should be re-evaluation visits, whenever symptom patterns change (79). Further management should be undertaken on an individualized basis, consisting of laboratory investigation (e.g., chest X-ray, blood biochemistry test, respiratory tests, and other tests) or referral to an appropriate specialty depending on the clinical manifestations. The management of PCS means primarily listening to the patients, and validating their experience (77). Special care should be taken when assessing previously healthy adolescents, who present with psychological issues, to not reinforce their possibly false concept of being unwell (73,80). When the specialized examination/investigation (pulmonological, neurological, rheumatological, cardiological, allergological and psychiatric) reveals specific conditions, the appropriate treatment (inhaled bronchodilators, anti-inflammatories, β -blockers, antihistamines, anxiolytics, etc.) should be administered (68,73,81).

Health care professionals should be trained and informed about this new PCS condition. The long COVID-19 clinics, which have been established by the majority of hospitals, play a crucial role; however, it is critical to train primary

Table II. Definitions of the post-COVID-19 syndrome (PCS).

Scientific corporation/institute/group	Definitions
WHO	In October 2021, the WHO defined the post-COVID-19 syndrome as ‘the condition that occurs in people with a history of definite or probable SARS-CoV-2 infection, usually within 3 months of the onset of the COVID-19 disease, with symptoms that last at least 2 months and cannot be attributed-explained by another diagnosis’ (64). These symptoms may follow an initial period of recovery or persist from the initial infection and generally have an impact on the functions of daily life. This definition does not include children.
CDC	In July 2021, the CDC introduced post-COVID-19 as the condition where there is no complete return to previous health status, where patients of all ages experience new, recurrent, or persistent symptoms, at least 4 weeks after SARS-CoV-2 infection (90). Symptoms can recur after a period of recovery from the initial infection and can occur regardless of the severity of the acute infection.
NICE	In February 2022, NICE defined long COVID-19 as persistent symptoms originating from the infection (ongoing symptomatic COVID-19) and lasting for 4 up to 12 weeks but also symptoms after the infection (post-COVID-19 syndrome) lasting ≥ 12 weeks (91).
NIHR	The NIHR has proposed that post-COVID-19 syndrome consists of different syndromes that include post-intensive care syndrome, post-viral fatigue syndrome, long-term COVID-19 syndrome and chronic disease that can result from organ damage due to of COVID-19, with patients likely to suffer from more than one syndrome and some showing different clusters of symptoms or patterns of symptoms (92).
CLoCk Consortium	At the end of 2021, the scientific group ‘CLoCk Consortium’ published a definition for children and young people, corresponding to the WHO definition (93). Post-COVID-19 condition occurs in children and young people with a history of confirmed SARS-CoV-2 infection, with one or more persistent physical symptoms, for a minimum period of 12 weeks following the initial diagnosis and cannot be explained by another diagnosis. Symptoms must affect daily functioning, may persist or develop after COVID-19, and may fluctuate or recur over time.

WHO, World Health Organization; COVID-19, coronavirus disease 2019; CDC, Centers of Disease Control and Prevention; NICE, National Institute for Health and Care Excellence; NIHR, National Institute for Health Research.

health care (PHC) professionals in this new entity, as they are going to face the majority of such patients (73). In a Centers for Disease Control and Prevention (CDC) publication by Kompaniyets *et al* (70) on PCS syndrome in children, who were 0-17 years of age, conditions that were more likely to occur among children with a history of SARS-CoV-2 infection than without, included the following: Acute pulmonary embolism, myocarditis and cardiomyopathy, acute renal failure and type I and type II diabetes mellitus. These are very severe conditions, which are not commonly found in paediatric patients; thus, PHC workers should be aware of and prepared to combat these. The majority of symptoms subside after 12 weeks from the infection and the most valid criterion for recognizing improvement is the testimony of the patient that they feel better. As more guidelines are becoming available for the management of PCS, it is important that these are followed by the health care workers involved (68,73,78,81). Studying and understanding this new entity is essential, as it will not only help improve the health of young patients, but will also help health policy makers to re-examine measures against the pandemic and re-evaluate the need for different protection and management strategies against SARS-CoV-2 infection in children.

7. Foetal magnetic resonance imaging and viral infections: Indications and findings

Foetuses are susceptible to a wide variety of viral infections, which can result in significant health issues associated with morbidity and disabilities in the affected children (82,83). CMV, HSV, human immunodeficiency virus (HIV), enteroviruses, VZV, parvovirus B19 and Zika virus account for transplacental foetal infection and most commonly involve the CNS (83). Neurosonography, including a foetal ultrasound brain scan, is the primary technique for assessing the foetal brain, while foetal MRI complements the ultrasound (82). Maternal infections represent one of the main indications for performing foetal CNS MRI, particularly if the ultrasound is abnormal or equivocal (82,84). Although imaging is practically unable to set the diagnosis of a viral infection in foetal life and reveal the pathogens, it has the potential to accurately suggest this scenario in foetal life, map the extent of involvement and direct the investigation, the parental consultation and the neonatal care accordingly. In fact, the developing brain is particularly sensitive to neurotropic viruses and infections acquired early in pregnancy, which may interfere with normal brain development (83). Each pathogen has a predilection for specific

anatomical region/s. However, the sequelae of an intrauterine infection reflect a combination of the pathogens and the stage of foetal development at which the exposure has occurred (85,86).

CMV appears to represent the most frequent and critical maternal infection. The findings of microcephaly, gyration anomalies and parenchymal lesions may provide a clue, although they are usually non-specific to foetal CMV infection (84). As a neurotropic virus, CMV haematogenously seeds the choroid plexus and replicates in the ependymal, germinal matrix and capillary endothelium (83). It may severely affect the foetal brain and cause permanent sequelae in almost 50% of symptomatic neonates, but also in up to 25% of the asymptomatic infants, who will develop sensorineural hearing loss usually by the age of 2 (83,86). Thus, foetal CNS MRI is indicated in these pregnancies, even if the ultrasound is negative. If CMV infection is acquired early in the second trimester, by predilection of the germinal matrix cells, it appears to interfere with normal neuro-glial migration and cause migrational and cortical abnormalities, such as agyria/pachygyria, polymicrogyria, schizencephaly, cerebellar hypoplasia and ventriculomegaly (83,86). Capillary involvement may lead to thrombosis and brain ischaemic lesions (83). This interesting association is examined in the literature, where there is an attempt to associate imaging findings with the timing of infection during pregnancy. In late gestation infections, different kinds, usually less severe, anomalies are noted, such as ventriculomegaly and myelin delay (focal, patchy or confluent with posterior distribution but sparing of the periventricular and subcortical white matter). Periventricular cysts are more characteristic of CMV infection, with variable locations, commonly in the anterior temporal lobes where white matter abnormalities are also noted. The differential diagnosis includes other cysts and parenchymal lesions. Parenchymal calcifications of variable configuration may be seen throughout pregnancy but they are not pathognomonic of CMV infection. These are better appreciated on neonatal ultrasound or CT (83).

Intrauterine HSV infection is rare and may lead to foetal hydrops, encephalomalacia, ventriculomegaly, microcephaly and foetal demise (83). Foetal HIV infection is globally decreasing due to preventative measures. In HIV-infected foetuses, calcifications of the subcortical white matter of the frontal lobes are typically seen and their severity is associated with the viral load. Foetuses affected by Zika virus at any time of the gestation present with a variety of severe brain defects, including microcephaly, brain atrophy, ventriculomegaly, cortical, callosal and posterior fossa abnormalities and ocular anomalies. Congenital varicella infection, caused by in utero transmission of VZV, causes variable imaging findings, which range from lobar destruction, basal ganglia necrosis and cerebellar hypoplasia to polymicrogyria and ventriculomegaly. Congenital infections represent a serious cause for foetal CNS injury with severe sequelae in the neonate (86). In suspicion of maternal viral infection, combining prenatal ultrasound and foetal MRI may document the extent of tissue damage and contribute to targeted treatment and counselling (87,88).

8. Conclusions and future perspectives

The management and prevention of CMV infection requires the administration of antiviral agents and the development

of effective vaccines approved by the international scientific community. Hantaviruses should be considered as possible causes of interstitial nephritis with decreased GFR in children. Recent advances in NGS analyses have emphasized the contribution of non-RSV, non-influenza viruses in the PICU disease burden. Among these, HRV appears to be a common pathogen causing severe respiratory disease requiring mechanical support, whereas CNS involvement and hyperinflammatory response with multi-organ involvement are being recognised as extrapulmonary HRV infection complications in critically ill children. HAdVs can also lead to disseminated disease, which requires hospitalisation and PICU management with antivirals and immunotherapy. PCS has been proposed as a new entity in the paediatric population; its prevalence is as yet undetermined and can occur in SARS-CoV-2 positive children, even if asymptomatic. The clarification of its definition and management may help improve the health of young patients, and may also guide health policy makers. Congenital infections represent a severe cause of foetal CNS injury with severe sequelae in the neonate. In the case that maternal viral infection is suspected, combining prenatal ultrasound and foetal MRI may document the extent of tissue damage and contribute to treatment and counselling. The COVID-19 era requires continuous, intensive, systematic, global scientific efforts in the clinic and in the laboratory, focusing on the diagnosis, management and prevention of all neonatal and paediatric viral infections.

Acknowledgements

The present study was published in the context of the 8th Workshop on Paediatric Virology, which was organised virtually on October 20, 2022, by the Institute of Paediatric Virology (IPV; <https://www.paediatricvirology.org>) based on the island of Euboea in Greece, under the auspices of the World Academy of Sciences (WAS) and the support of the Department of Clinical Virology of the University of Crete School of Medicine and the First Department of Paediatrics of the University of Athens School of Medicine. In the context of the same workshop three more articles by Kramvis *et al* (7), Maher *et al* (10) and Mammas *et al* (89) were published in Biomedical Reports, Medicine International and Experimental and Therapeutic Medicine, respectively.

Funding

No funding was received.

Availability of data and materials

Not applicable.

Authors' contributions

All authors (INM, SBD, CC, PK, AP, CK, TS, KM, HK, GP, AK, AG, MT and DAS) contributed equally to the conception and design of the study, wrote the original draft, edited and critically revised the manuscript, and read and approved the final manuscript. Data authentication is not applicable.

Ethics approval and consent to participate

Not applicable.

Patient consent for publication

Not applicable.

Competing interests

DAS is the Editor-in-Chief for the journal, but had no personal involvement in the reviewing process, or any influence in terms of adjudicating on the final decision, for this article. The other authors declare that they have no competing interests.

References

- Jansen M, Irving H, Gillam L, Sharwood E, Preisz A, Basu S, Delaney C, McDougall R, Johnston C, Isaacs D and Lister P: Ethical considerations for paediatrics during the COVID-19 pandemic: A discussion paper from the Australian Paediatric Clinical Ethics Collaboration. *J Paediatr Child Health* 56: 847-851, 2020.
- International Child Health Group; Royal College of Paediatrics & Child Health; Royal College of Paediatrics & Child Health: Impact of the COVID-19 pandemic on global child health: Joint statement of the International Child Health Group and the Royal College of Paediatrics and Child Health. *Arch Dis Child* 106: 115-116, 2021.
- Johnston R, Sen C and Baki Y: Virtual paediatrics: What COVID-19 has taught us about online learning. *Arch Dis Child Educ Pract Ed* 108: 125-129, 2023.
- Mammas IN, Greenough A, Theodoridou M and Spandidos DA: The foundation of the Institute of Paediatric Virology on the island of Euboea, Greece (Review). *Exp Ther Med* 20: 302, 2020.
- Mammas IN, Kramvis A, Papaevangelou V, Doukas SG, Naya SD, Doukas PG, Melikoki V, Bouros D, Thiagarajan P, Chrousos GP, *et al*: SARS-CoV-2 infection and children: Insights from the 6th Workshop on Paediatric Virology (Review). *World Acad Sci J* 4: 1-12, 2022.
- Mammas IN, Liston M, Koletsi P, Vitoratou DI, Koutsaftiki C, Papatheodoropoulou A, Kornarou H, Theodoridou M, Kramvis A, Drysdale SB and Spandidos DA: Insights in paediatric virology during the COVID-era (Review). *Med Int (Lond)* 2: 17, 2022.
- Kramvis A, Mammas IN and Spandidos DA: Exploring the optimal vaccination strategy against hepatitis B virus in childhood (Review). *Biomed Rep* 19: 48, 2023.
- Kramvis A: The clinical implications of hepatitis B virus genotypes and HBeAg in pediatrics. *Rev Med Virol* 26: 285-303, 2016.
- Kramvis A: Challenges for hepatitis B virus cure in resource-limited settings in sub-Saharan Africa. *Curr Opin HIV AIDS* 15: 185-192, 2020.
- Maher F, Mammas IN and Spandidos DA: The challenges and perspectives of palliative medicine: A webinar by the Paediatric Virology Study Group. *Med Int (Lond)* 3: 24, 2023.
- Fowler K, Mucha J, Neumann M, Lewandowski W, Kaczanowska M, Grys M, Schmidt E, Natenshon A, Talarico C, Buck PO and Diaz-Decaro J: A systematic literature review of the global seroprevalence of cytomegalovirus: Possible implications for treatment, screening, and vaccine development. *BMC Public Health* 22: 1659, 2022.
- Hiskey L, Madigan T, Ristagno EH, Razonable RR and Ferdjallah A: Prevention and management of human cytomegalovirus in pediatric HSCT recipients: A review. *Front Pediatr* 10: 1039938, 2022.
- Pesch MH, Kuboushek K, McKee MM, Thorne MC and Weinberg JB: Congenital cytomegalovirus infection. *BMJ* 373: n1212, 2021.
- Faure-Bardon V, Fourgeaud J, Stirnemann J, Leruez-Ville M and Ville Y: Secondary prevention of congenital cytomegalovirus infection with valgacyclovir following maternal primary infection in early pregnancy. *Ultrasound Obstet Gynecol* 58: 576-581, 2021.
- Chen SJ, Wang SC and Chen YC: Challenges, recent advances and perspectives in the treatment of human cytomegalovirus infections. *Trop Med Infect Dis* 7: 439, 2022.
- Acosta E, Bowlin T, Brooks J, Chiang L, Hussein I, Kimberlin D, Kauvar LM, Leavitt R, Prichard M and Whitley R: Advances in the development of therapeutics for cytomegalovirus infections. *J Infect Dis* 221(Suppl 1): S32-S44, 2020.
- Li L, Freed DC, Liu Y, Li F, Barrett DF, Xiong W, Ye X, Adler SP, Rupp RE, Wang D, *et al*: A conditionally replication-defective cytomegalovirus vaccine elicits potent and diverse functional monoclonal antibodies in a phase I clinical trial. *NPJ Vaccines* 6: 79, 2021.
- Das R, Blazquez-Gamero D, Bernstein DI, Gantt S, Bautista O, Beck K, BSN RN, Conlon A, Rosenbloom D, Wang D, *et al*: 1048. Double-blind, randomized, placebo-controlled phase 2b multicenter trial of V160, a replication-defective human cytomegalovirus (CMV) vaccine. *Open Forum Infect Dis* 8(Suppl 1): S615-S616, 2021.
- Mustonen J, Huttunen NP, Brummer-Korvenkontio M and Vaheri A: Clinical picture of nephropathia epidemica in children. *Acta Paediatr* 83: 526-529, 1994.
- Peters CJ: Viral Hemorrhagic Fevers. *Viral Pathogenesis*. Lippincott-Raven Publishers, New York, NY, 779-794, 1997.
- Peters CJ, Simpson GL and Levy H: Spectrum of hantavirus infection: Hemorrhagic fever with renal Syndrome and hantavirus pulmonary Syndrome. *Annu Rev Med* 50: 531-545, 1999.
- Linderholm M and Elgh F: Clinical characteristics of hantavirus infections on the Eurasian continent. *Curr Top Microbiol Immunol* 256: 135-151, 2001.
- Koskela S, Mäkelä S, Strandin T, Vaheri A, Outinen T, Joutsu-Korhonen L, Pörsti I, Mustonen J and Laine O: Coagulopathy in acute puumala hantavirus infection. *Viruses* 13: 1553, 2021.
- Latus J, Schwab M, Tacconelli E, Pieper FM, Wegener D, Rettenmaier B, Schwab A, Hoffmann L, Dippon J, Müller S, *et al*: Acute kidney injury and tools for risk-stratification in 456 patients with hantavirus-induced nephropathia epidemica. *Nephrol Dial Transplant* 30: 245-251, 2015.
- Latus J, Kitterer D, Segerer S, Artunc F, Alscher MD and Braun N: Severe thrombocytopenia in hantavirus-induced nephropathia epidemica. *Infection* 43: 83-87, 2015.
- Antoniades A, Grekas D, Rossi CA and LeDuc JW: Isolation of a hantavirus from a severely ill patient with hemorrhagic fever with renal syndrome in Greece. *J Infect Dis* 156: 1010-1013, 1987.
- Ferres M and Vial P: Hantavirus infection in children. *Curr Opin Pediatr* 16: 70-75, 2004.
- Dusek J, Pejcoch M, Kolsky A, Seeman T, Nemeč V, Stejskal J, Vondrak K and Janda J: Mild course of Puumala nephropathy in children in an area with sporadic occurrence Hantavirus infection. *Pediatr Nephrol* 21: 1889-1892, 2006.
- van der Werff ten Bosch J, Heyman P, Potters D, Peeters S, Cochez C and Piérard D: Hantavirus Puumala infection as a cause of fever of unknown origin in a child. *Acta Paediatr* 93: 1120-1122, 2004.
- Eboriadou M, Kalevrosoglou I, Varlamis G, Mitsiakos G, Papa A and Antoniadis A: Hantavirus nephropathy in a child. *Nephrol Dial Transplant* 14: 1040-1041, 1999.
- Papadopoulos NG, Moustaki M, Tsolia M, Bossios A, Astra E, Prezerakou A, Gourgiotis D and Kafetzis D: Association of rhinovirus infection with increased disease severity in acute bronchiolitis. *Am J Respir Crit Care Med* 165: 1285-1289, 2002.
- Asner SA, Petrich A, Hamid JS, Mertz D, Richardson SE and Smieja M: Clinical severity of rhinovirus/enterovirus compared to other respiratory viruses in children. *Influenza Other Respir Viruses* 8: 436-442, 2014.
- Smith ME and Wilson PT: Human rhinovirus/enterovirus in pediatric acute respiratory distress Syndrome. *J Pediatr Intensive Care* 9: 81-86, 2020.
- Miller EK, Williams JV, Gebretsadik T, Carroll KN, Dupont WD, Mohamed YA, Morin LL, Heil L, Minton PA, Woodward K, *et al*: Host and viral factors associated with severity of human rhinovirus-associated infant respiratory tract illness. *J Allergy Clin Immunol* 127: 883-891, 2011.
- Costa LF, Queiróz DA, Lopes da Silveira H, Bernardino Neto M, de Paula NT, Oliveira TF, Tolardo AL and Yokosawa J: Human rhinovirus and disease severity in children. *Pediatrics* 133: e312-e321, 2014.
- Miller EK, Bugna J, Libster R, Shepherd BE, Scalzo PM, Acosta PL, Hijano D, Reynoso N, Batalle JP, Coviello S, *et al*: Human rhinoviruses in severe respiratory disease in very low birth weight infants. *Pediatrics* 129: e60-e67, 2012.

37. Brand HK, de Groot R, Galama JM, Brouwer ML, Teuwen K, Hermans PW, Melchers WJ and Warris A: Infection with multiple viruses is not associated with increased disease severity in children with bronchiolitis. *Pediatr Pulmonol* 47: 393-400, 2012.
38. Spaeder MC, Custer JW, Miles AH, Ngo L, Morin NP, Scafidi S, Bembea MM and Song X: A multicenter outcomes analysis of children with severe rhino/enteroviral respiratory infection. *Pediatr Crit Care Med* 16: 119-123, 2015.
39. Louie JK, Roy-Burman A, Guardia-Labar L, Boston EJ, Kiang D, Padilla T, Yagi S, Messenger S, Petru AM, Glaser CA and Schnurr DP: Rhinovirus associated with severe lower respiratory tract infections in children. *Pediatr Infect Dis J* 28: 337-339, 2009.
40. Renwick N, Schweiger B, Kapoor V, Liu Z, Villari J, Bullmann R, Miething R, Briese T and Lipkin WI: A recently identified rhinovirus genotype is associated with severe respiratory-tract infection in children in Germany. *J Infect Dis* 196: 1754-1760, 2007.
41. Lee WM, Kiesner C, Pappas T, Lee I, Grindle K, Jartti T, Jakiela B, Lemanske RF Jr, Shult PA and Gern JE: A diverse group of previously unrecognized human rhinoviruses are common causes of respiratory illnesses in infants. *PLoS One* 2: e966, 2007.
42. To KK, Lau SK, Chan KH, Mok KY, Luk HK, Yip CC, Ma YK, Sinn LH, Lam SH, Ngai CW, *et al*: Pulmonary and extrapulmonary complications of human rhinovirus infection in critically ill patients. *J Clin Virol* 77: 85-91, 2016.
43. Liu J, Zhao H, Feng Z, Liu Y, Feng Q, Qian S, Xu L, Gao H and Xie Z: A severe case of human rhinovirus A45 with central nervous system involvement and viral sepsis. *Virol J* 19: 72, 2022.
44. Li CX, Burrell R, Dale RC, Kesson A, Blyth CC, Clark JE, Crawford N, Jones CA, Britton PN and Holmes EC: Diagnosis and analysis of unexplained cases of childhood encephalitis in Australia using metatranscriptomic sequencing. *J Gen Virol* 103 2022.
45. Hazama K, Shiihara T, Tsukagoshi H, Matsushige T, Dowa Y and Watanabe M: Rhinovirus-associated acute encephalitis/encephalopathy and cerebellitis. *Brain Dev* 41: 551-554, 2019.
46. Triantafylou K, Vakakis E, Richer EA, Evans GL, Villiers JP and Triantafylou M: Human rhinovirus recognition in non-immune cells is mediated by Toll-like receptors and MDA-5, which trigger a synergetic pro-inflammatory immune response. *Virulence* 2: 22-29, 2011.
47. Centers for Disease Control and Prevention (CDC). Adenoviruses. CDC, Atlanta, GA, 2022. <https://www.cdc.gov/adenovirus/hcp/index.html>.
48. Edmond K, Scott S, Korczak V, Ward C, Sanderson C, Theodoratou E, Clark A, Griffiths U, Rudan I and Campbell H: Long term sequelae from childhood pneumonia; systematic review and meta-analysis. *PLoS One* 7: e31239, 2012.
49. Birenbaum E, Linder N, Varsano N, Azar R, Kuint J, Spierer A and Reichman B: Adenovirus type 8 conjunctivitis outbreak in a neonatal intensive care unit. *Arch Dis Child* 68 (5 Spec No): 610-611, 1993.
50. Bowles NE, Ni J, Kearney DL, Pauschinger M, Schultheiss HP, McCarthy R, Hare J, Bricker JT, Bowles KR and Towbin JA: Detection of viruses in myocardial tissues by polymerase chain reaction. Evidence of adenovirus as a common cause of myocarditis in children and adults. *J Am Coll Cardiol* 42: 466-472, 2003.
51. World Health Organization (WHO): Severe acute hepatitis of unknown aetiology in children-Multi-country. WHO, Geneva, 2022. <https://www.who.int/emergencies/disease-outbreak-news/item/2022-DON400>. Accessed October 20, 2022.
52. Cates J, Baker JM, Almendares O, Kambhampati AK, Burke RM, Balachandran N, Burnett E, Potts CC, Reagan-Steiner S, Kirking HL, *et al*: Interim analysis of acute hepatitis of unknown etiology in children aged <10 years-United States, October 2021-June 2022. *MMWR Morb Mortal Wkly Rep* 71: 852-858, 2022.
53. Morfopoulou S, Buddle S, Torres Montaguth OE, Atkinson L, Guerra-Assunção JA, Storey N, Roy S, Lennon A, Lee JCD, Williams R, *et al*: Genomic investigations of acute hepatitis of unknown aetiology in children. doi.org/10.1101/2022.07.28.22277963. <https://media.gosh.nhs.uk/documents/MEDRXIV-2022-277963v1-Breuer.pdf>. Accessed October 20, 2022.
54. Schwartz KL, Richardson SE, MacGregor D, Mahant S, Raghuram K and Bitnun A: Adenovirus-Associated central nervous system disease in children. *J Pediatr* 205: 130-137, 2019.
55. Huang YC, Huang SL, Chen SP, Huang YL, Huang CG, Tsao KC and Lin TY: Adenovirus infection associated with central nervous system dysfunction in children. *J Clin Virol* 57: 300-304, 2013.
56. Otto WR, Behrens EM, Teachey DT, Lamson DM, Barrett DM, Bassiri H, Lambert MP, Mount S, Petrosa WL, Romberg N, *et al*: Human adenovirus 7-associated hemophagocytic lymphohistiocytosis-like illness: Clinical and virological characteristics in a cluster of five pediatric cases. *Clin Infect Dis* 73: e1532-e1538, 2021.
57. Censoplano N, Gorga S, Waldeck K, Stillwell T, Rabah-Hammad R and Flori H: Neonatal adenovirus infection complicated by hemophagocytic lymphohistiocytosis Syndrome. *Pediatrics* 141(Suppl 5): S475-S480, 2018.
58. Munoz FM, Piedra PA and Demmler GJ: Disseminated adenovirus disease in immunocompromised and immunocompetent children. *Clin Infect Dis* 27: 1194-1200, 1998.
59. Alcamo AM, Wolf MS, Alessi LJ, Chong HJ, Green M, Williams JV and Simon DW: Successful use of cidofovir in an immunocompetent child with severe adenoviral sepsis. *Pediatrics* 145: e20191632, 2020.
60. Ljungman P, Ribaud P, Eyric M, Matthes-Martin S, Einsele H, Bleakley M, Machaczka M, Bierings M, Bosi A, Gratecos N, *et al*: Cidofovir for adenovirus infections after allogeneic hematopoietic stem cell transplantation: A survey by the Infectious Diseases Working Party of the European Group for Blood and Marrow Transplantation. *Bone Marrow Transplant* 31: 481-486, 2003.
61. Sofer A, Arger N and Vest M: Successful Treatment of Adenovirus-Induced ARDS With Cidofovir and IVIG. *Chest Infect* 144: 229A, 2013.
62. Leen AM, Bollard CM, Mendizabal AM, Shpall EJ, Szabolcs P, Antin JH, Kapoor N, Pai SY, Rowley SD, Kebriaei P, *et al*: Multicenter study of banked third-party virus-specific T cells to treat severe viral infections after hematopoietic stem cell transplantation. *Blood* 121: 5113-5123, 2013.
63. Callard F and Perego E: How and why patients made long COVID. *Soc Sci Med* 268: 113426, 2021.
64. Soriano JB, Murthy S, Marshall JC, Relan P, Diaz JV; WHO Clinical Case Definition Working Group on Post-COVID-19 condition: A clinical case definition of post-COVID-19 condition by a Delphi consensus. *Lancet Infect Dis* 22: e102-e107, 2022.
65. Munblit D, Simpson F, Mabbitt J, Dunn-Galvin A, Semple C and O Warner J: Legacy of COVID-19 infection in children: Long-COVID will have a lifelong health/economic impact. *Arch Dis Child* 107: e2, 2022.
66. Lopez-Leon S, Wegman-Ostrosky T, Ayuzo del Valle NC, Perelman C, Sepulveda R, Rebolledo PA, Cuapio A and Villapol S: Long COVID in children and adolescents: A systematic review and meta-analyses *Sci Rep* 12: 9950, 2022.
67. Thallapureddy K, Thallapureddy K, Zerda E, Suresh N, Kamat D, Rajasekaran K and Moreira A: Long-Term complications of COVID-19 infection in adolescents and children. *Curr Pediatr Rep* 10: 11-17, 2022.
68. Fainardi V, Meoli A, Chiopris G, Motta M, Skenderaj K, Grandinetti R, Bergomi A, Antodaro F, Zona S and Esposito S: Long COVID in children and adolescents. *Life (Basel)* 12: 285, 2022.
69. Borch L, Holm M, Knudsen M, Ellermann-Eriksen S and Hagstroem S: Long COVID symptoms and duration in SARS-CoV-2 positive children-a nationwide cohort study. *Eur J Pediatr* 181: 1597-1607, 2022.
70. Kompaniyets L, Bull-Otterson L, Boehmer TK, Baca S, Alvarez P, Hong K, Hsu J, Harris AM, Gundlapalli AV and Saydah S: Post-COVID-19 symptoms and conditions among children and adolescents-United States, March 1, 2020-January 31, 2022. *MMWR Morb Mortal Wkly Rep* 71: 993-999, 2022.
71. Zimmermann P, Pittet LF and Curtis N: How common is Long COVID in children and adolescents? *Pediatr Infect Dis J* 40: e482-e487, 2021.
72. Nittas V, Gao M, West EA, Ballouz T, Menges D, Wulf Hanson S and Puhan MA: Long COVID through a public health lens: An umbrella review *Public Health Rev* 43: 1604501, 2022.
73. Pavli A, Theodoridou M and Maltezou H: Post-COVID Syndrome: Incidence, clinical spectrum and challenges for Primary Healthcare Professionals. *Arch Med Res* 52: 575-581, 2021.
74. Osmanov IM, Spiridonova E, Bobkova P, Gamirova A, Shikhaleva A, Andreeva M, Blyuss O, El-Taravi Y, DunnGalvin A, Comberiat P, *et al*: Risk factors for post-COVID-19 condition in previously hospitalized children using the ISARIC Global follow-up protocol: A prospective cohort study. *Eur Respir J* 59: 210134, 2022.

75. Zimmermann P, Pittet LF and Curtis N: Long covid in children and adolescents. *BMJ* 376: o143, 2022.
76. Zimmermann P, Pittet LF and Curtis N: The challenge of studying Long COVID: An updated review. *Pediatr Infect Dis J* 41: 424-426, 2022.
77. Greenhalgh T, Sivan M, Delaney B, Evans R and Milne R: Long covid-an update for primary care *BMJ* 378: e072117, 2022.
78. Esposito S, Principi N, Azzari C, Cardinale F, Di Mauro G, Galli L, Gattinara GC, Fainardi V, Guarino A, Lancella L, *et al*: Italian intersociety consensus on management of long covid in children. *Ital J Pediatr* 48: 42, 2022.
79. Goldman RD: Long COVID in children. *Can Fam Physician* 68: 263-265, 2022.
80. Cozzi G, Marchetti F and Barbi E: Clinicians need to be careful that they do not confuse mental health issues and long COVID in children and adolescents. *Acta Paediatr* 112: 180-183, 2023.
81. Morrow AK, Malone LA, Kokorelis C, Petracek LS, Eastin EF, Lobner KL, Neuendorff L and Rowe PC: Long-term COVID 19 sequelae in adolescents: The overlap with orthostatic intolerance and ME/CFS. *Curr Pediatr Rep* 10: 31-44, 2022.
82. Salomon LJ and Garel C: Magnetic resonance imaging examination of the fetal brain. *Ultrasound Obstet Gynecol* 30: 1019-1032, 2007.
83. Neuberger I, Garcia J, Meyers ML, Feygin T, Bulas DI and Mirsky DM: Imaging of congenital central nervous system infections. *Pediatr Radiol* 48: 513-523, 2018.
84. Rossi AC and Prefumo F: Additional value of fetal magnetic resonance imaging in the prenatal diagnosis of central nervous system anomalies: A systematic review of the literature. *Ultrasound Obstet Gynecol* 44: 388-393, 2014.
85. Lo CP and Chen CY: Neuroimaging of viral infections in infants and young children. *Neuroimaging Clin N Am* 18: 119-132; viii, 2008.
86. Griffiths PD, Mooney C, Bradburn M and Jarvis D: Should we perform in utero MRI on a fetus at increased risk of a brain abnormality if ultrasonography is normal or shows non-specific findings? *Clin Radiol* 73: 123-134, 2018.
87. Verstraelen H, Vanzieleghem B, Defoort P, Vanhaesebrouck P and Temmerman M: Prenatal ultrasound and magnetic imaging in fetal varicella syndrome: Correlation with pathology findings. *Prenat Diagn* 23: 705-709, 2003.
88. Sanchez TR, Datlow MD and Nidecker AE: Diffuse periventricular calcification and brain atrophy: A case of neonatal central nervous system cytomegalovirus infection. *Neuroradiol J* 29: 314-316, 2016.
89. Mammias IN, Drysdale SB, Theodoridou M and Spandidos DA: Exploring medical terminology inexpediciencies: Triple epidemic vs. triple epidemic. *Exp Ther Med* 26: 334, 2023.
90. Centers for Disease Control and Prevention (CDC): Post-COVID Conditions: Information for Healthcare Providers. CDC, Atlanta, GA, 2022. <https://www.cdc.gov/coronavirus/2019-ncov/hcp/clinical-care/post-covid-conditions.html>. Accessed October 20, 2022.
91. The National Institute for Health and Care Excellence (NICE): COVID-19 rapid guideline: managing the long-term effects of COVID-19. <https://www.nice.org.uk/guidance/NG188>. Accessed October 20, 2022.
92. National Institute for Health and Care Research (NIHR): Living with Covid-19-Second Review. <https://evidence.nihr.ac.uk/theme-dreview/living-with-covid19-second-review>. Accessed October 20, 2022.
93. Stephenson T, Allin B, Nugawela MD, Rojas N, Dalrymple E, Pinto Pereira S, Soni M, Knight M, Cheung EY, Heyman I, *et al*: Long COVID (post-COVID-19 condition) in children: A modified Delphi process. *Arch Dis Child* 107: 674-680, 2022.



Copyright © 2023 Mammias et al. This work is licensed under a Creative Commons Attribution-NonCommercial-NoDerivatives 4.0 International (CC BY-NC-ND 4.0) License.