

CLINICAL PRACTICE

Oral Squamous Cell Carcinoma Presenting as a Stiff Tongue

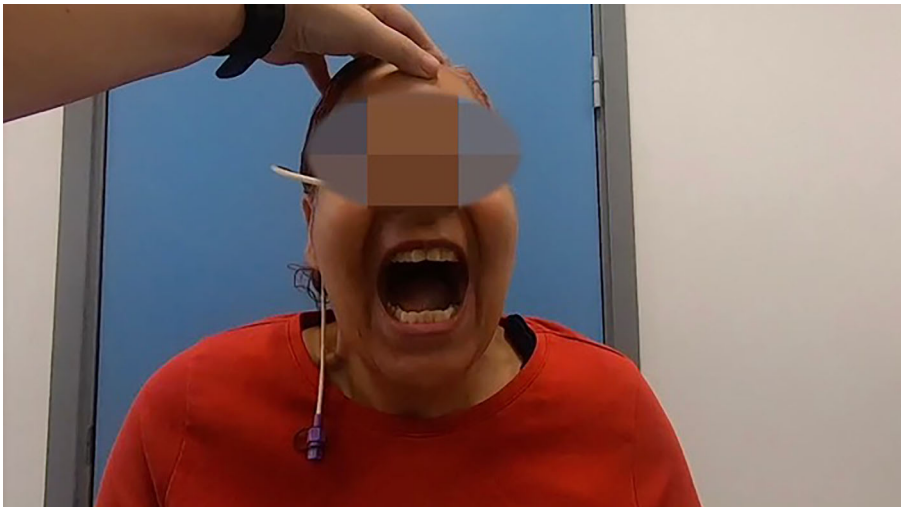
Belén González-Herrero, MD^{1,2,*} and Francesca Morgante, MD, PhD^{1,3} 

A 58-year-old woman was referred to our movement disorders clinic to review the diagnosis of functional tongue dystonia. She had a 9-month history of progressive swallowing and speech impairment as well as difficulties mobilizing the tongue.

On past medical history, she had a subarachnoid hemorrhage secondary to an aneurysm in 2005, from which she recovered with mild left-side hemiparesis.

Symptoms started acutely in the spring of 2021 with pain in the tongue and sore throat followed by speech and swallowing difficulties. At disease onset, she underwent a nasendoscopy, which showed normal palatal function, tongue base, and larynx. She continued deteriorating with increased pain when mobilizing

the tongue and severe dysphagia with sialorrhoea. A nasogastric tube was inserted to ensure nutrition. The following investigations performed 9 months after onset were negative: full blood count, coagulation, general biochemistry (liver and renal function), anti-glutamic acid decarboxylase antibodies and cerebrospinal fluid analysis. Magnetic Resonance Imaging (MRI) of the skull base to the clavicle with contrast was reported normal. Brain MRI showed low attenuation in the frontal parafalcine region bilaterally secondary to a previous brain insult. EMG of the genioglossus and supraglottic muscles was normal. A video fluoroscopic swallow study showed reduced bolus manipulation secondary to reduced lingual coordination and strength.



Video 1. The video shows the inability to protrude or retract the tongue, dysarthria and dysphonia. Speech disturbance did not change upon distractive maneuvers.

Video content can be viewed at <https://onlinelibrary.wiley.com/doi/10.1002/mdc3.13769>

¹Neuroscience Research Centre, Molecular and Clinical Sciences Institute, St George's University of London, London, UK; ²Departamento de Medicina, Universidad Autónoma de Barcelona (UAB), Barcelona, Spain; ³Department of Experimental and Clinical Medicine, University of Messina, Messina, Italy

***Correspondence to:** Dr Belén González-Herrero, Neuroscience Research Centre, Molecular and Clinical Sciences Institute, St George's University of London, London, UK; E-mail: belen.glez.herrero@gmail.com

Keywords: tongue, oral squamous cell carcinoma, dystonia, functional movement disorders.

This is an open access article under the terms of the [Creative Commons Attribution-NonCommercial-NoDerivs](https://creativecommons.org/licenses/by-nc-nd/4.0/) License, which permits use and distribution in any medium, provided the original work is properly cited, the use is non-commercial and no modifications or adaptations are made.

Received 26 October 2022; revised 3 February 2023; accepted 10 February 2023.

Published online 00 Month 2023 in Wiley Online Library (wileyonlinelibrary.com). DOI: 10.1002/mdc3.13769

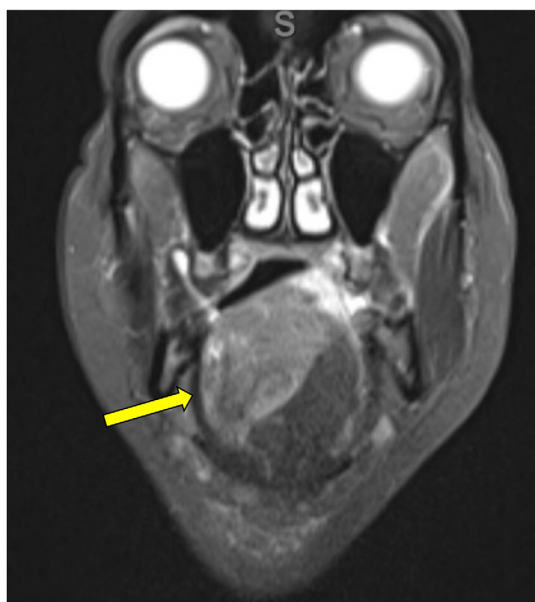

Figure 1. MRI of the skull base and neck performed 11 months after onset showing a neoplastic lesion of the tongue.

Our examination in November 2021 disclosed the following findings (Video 1): inability to mobilize the tongue, dysarthria, and nasal voice with no effect of distractive maneuvers. Upon touching the tongue, the tissue was indurated and had pain and resistance to passive manipulation. No ulcers or leukoplakia were noted.

MRI of the skull base and neck repeated 11 months after onset showed a neoplastic lesion of the tongue (Fig. 1) and an enlarged node (1.6 cm in maximum short axis) overlying the right sternocleidomastoid. A biopsy was performed with the final diagnosis of a moderately to poorly differentiated small cT4 N2c M0 squamous cell carcinoma involving the whole anterior tongue/tongue base. The tumor was not amenable to surgical intervention, and she was started on palliative treatment.

Here we described a woman with a painful fixed posture of the tongue secondary to a structural neoplastic lesion, previously misdiagnosed as functional movement disorder (FMD). Pain, difficulty in mobilizing the tongue, voice changes and dysphagia are common complaints when the tumor is localized at the tongue base.¹ Early diagnosis of oral squamous cell carcinomas is crucial as cervical lymph node metastasis reduces the survival rate by 50% and increases the risk of primary tumor cell dissemination to distant organs.²

This patient was initially diagnosed with FMD based on the acute presentation, the bizarre nature of the clinical syndrome (incongruity), the presence of fixed posture of the tongue and the negativity of neurological investigations. Moreover, investigations such as video fluoroscopic swallow study were misinterpreted based on the diagnostic bias of FMD.

The diagnosis of FMD should rely on demonstrating positive signs.³ Functional speech disorder typically presents with voice abnormalities, stuttering-like dysfluencies, and articulation and

prosodic abnormalities (including pseudo-foreign accents). There is variability during the examination,⁴ and speech can be associated with facial muscles' inefficient and nonergonomic movement patterns. Functional dystonia of the tongue may present as fixed tongue deviation or torsion and tends to be associated with other, generally ipsilateral, FMDs.^{5,6}

Here, we presented a case of an “organic” condition wrongly diagnosed as a functional neurological disorder (FND). Conditions such as stroke, transverse myelitis, Ewing sarcoma, medulloblastoma or autoimmune encephalitis have been misdiagnosed as FND.

This case teaches the central value of clinical examination, keeping an open mind and broad differential diagnosis when assessing patients diagnosed with FND.

Acknowledgments

Dr González-Herrero is grateful to The Alfonso Martin Escudero Foundation, Madrid, Spain, for supporting her research activity.

Author Roles

(1) Research project: A. Conception, B. Organization, C. Execution. (2) Statistical Analysis: A. Design, B. Execution, C. Review and Critique. (3) Manuscript: A. Writing of the first draft, B. Review and Critique.

B.G.-H.: 1C, 3A, 3B.

F.M.: 1A, 1B, 1C, 3B.

Disclosures

Ethical Compliance Statement: We confirm that we have read the Journal's position on issues involved in ethical publication and affirm that this work is consistent with those guidelines. The authors confirm that the approval of an institutional review board was not required for this work. We also guarantee that the patient consented to anonymously report her clinical reports and videos per current ethical standards.

Funding Sources and Conflicts of Interest: This study did not receive any industry funding. The authors have no conflicts of interest to declare.

Financial Disclosure for the Previous 12 Months: B.G.-H.: research scholarship from The Alfonso Martin Escudero Foundation, Madrid. F.M.: Speaking honoraria from Abbvie, Medtronic, Boston Scientific, Bial, Merz; Travel grants from the International Parkinson's disease and Movement Disorder Society; Advisory board fees from Abbvie, Merz and Boston Scientific; Consultancies fees from Boston Scientific, Merz and Bial; Research support from NIH, UKRI, Boston Scientific, Merz and Global Kynetic; Royalties for the book “Disorders of Movement” from Springer; member of the editorial board of Movement Disorders, Movement Disorders Clinical Practice, European Journal of Neurology. ■

References

1. Bagan J, Sarrion G, Jimenez Y. Oral cancer: clinical features. *Oral Oncol* 2010;46:414–417.
2. Bugshan A, Farooq I. Oral squamous cell carcinoma: metastasis, potentially associated malignant disorders, etiology and recent advancements in diagnosis. *F1000Res* 2020;9:229.
3. Espay AJ, Aybek S, Carson A, et al. Current concepts in diagnosis and treatment of functional neurological disorders. *JAMA Neurol* 2018;75:1132–1141.
4. Baker J, Barnett C, Cavalli L, et al. Management of functional communication, swallowing, cough and related disorders: consensus recommendations for speech and language therapy. *J Neurol Neurosurg Psychiatry* 2021; 92:1112–1125.
5. Erro R, Cordivari C, Catania S, Bhatia KP, Edwards MJ. Fixed dystonia of the tongue. *Mov Disord Clin Pract* 2014;1:134–135.
6. Fasano A, Valadas A, Bhatia KP, et al. Psychogenic facial movement disorders: clinical features and associated conditions. *Mov Disord* 2012; 27:1544–1551.