

## Ethnic and sex-related differences at presentation in apical hypertrophic cardiomyopathy: An observational cross-sectional study<sup>☆</sup>

Shafik Khoury, Raghav T. Bhatia, Sarandeep Marwaha, Chris Miles, Alexandros Kasiakogias, Nick Bunce, Elijah Behr, Michael Papadakis, Sanjay Sharma, Maite Tome<sup>\*</sup>

Cardiovascular Clinical Academic Group, St. George's, University of London, St. George's University Hospitals NHS Foundation Trust, United Kingdom

### ARTICLE INFO

#### Keywords:

Hypertrophic cardiomyopathy  
Magnetic resonance imaging  
Hypertension  
Apical hypertrophy

### ABSTRACT

**Background:** We investigated whether ethnicity and sex are associated with different clinical presentations and cardiovascular magnetic resonance (CMR) findings in individuals with apical hypertrophic cardiomyopathy (ApHCM).

**Methods:** A retrospective observational cohort study of consecutive ApHCM patients from a large tertiary referral center in the United Kingdom (UK). Demographic, clinical, 12-lead electrocardiogram (ECG) and CMR findings were collected. Participants presented in our clinics between 2010 and 2020. 'Pure' ApHCM was defined as isolated apical hypertrophy and 'mixed' with both apical and septal hypertrophy but with the apical segments of a greater wall thickness. Deep T-wave inversion was defined as  $\geq 5$  mm in any electrocardiogram lead.

**Results:** A total of 150 consecutive ApHCM patients (75% men, 25% women; 37% White, 25% Black, 24% Asian and 15% of Mixed/Other ethnicity) were included. Females were diagnosed at an older age compared to men, had less prominent ECG changes, had higher left atrial area index, and were more hypertensive. Black patients had higher left ventricular mass index, more hypertension, and more of the 'mixed' type of ApHCM. The majority of hypertensive male patients showed the 'mixed' phenotype.

**Conclusions:** Individuals of Black ethnicity and hypertensive male patients are more likely to present with mixed apical and basal hypertrophy, whereas White, Asian and non-hypertensive male patients tend to have hypertrophy limited to the apex. Females present at an older age and are less likely to have deep T wave inversion on ECG.

### 1. Background

Female and black individuals with the apical variant of hypertrophic cardiomyopathy (ApHCM) have been traditionally understudied. This may be partially explained by the fact that ApHCM is characterised by male predominance [1] with higher prevalence in individuals of Asian ethnicity [2] while it is relatively an uncommon phenotype in Western countries where it comprises up to 10% of hypertrophic cardiomyopathy (HCM) cases [3].

Data on classical HCM suggest that sex is associated with a different clinical presentation and outcomes [4–8]. Similarly, ethnic differences in disease expression and prognosis have been reported [9,10]. However, there is limited data in the current literature on the association between ethnicity and sex in individuals with ApHCM. Therefore, the

authors aimed to investigate whether ethnicity and sex are associated with different clinical presentations and imaging findings in ApHCM.

Over the last decade, cardiovascular magnetic resonance (CMR) has increasingly become part of routine assessment of HCM patients at diagnosis in the United Kingdom (UK) and in many centres around the world [11,12]. It provides more accurate assessment of left ventricular apical hypertrophy and better identifies related complications such as thrombus and aneurysm formation compared to echocardiography. [13,14] However, most available imaging data on ApHCM has been derived from echocardiography and very few CMR cohort studies have been published. Therefore, the authors utilised CMR data to investigate the imaging findings in ApHCM.

<sup>☆</sup> All authors take responsibility for all aspects of the reliability and freedom from bias of the data presented and their discussed interpretation.

<sup>\*</sup> Corresponding author at: Cardiovascular Clinical Academic Group, St. George's University of London, Institute of Molecular and Clinical Sciences, Cranmer Terrace, London SW17 0RE, United Kingdom.

E-mail address: [mtome@sul.ac.uk](mailto:mtome@sul.ac.uk) (M. Tome).

<https://doi.org/10.1016/j.ijcard.2023.131265>

Received 31 March 2023; Received in revised form 3 August 2023; Accepted 10 August 2023

Available online 11 August 2023

0167-5273/© 2023 The Authors. Published by Elsevier B.V. This is an open access article under the CC BY license (<http://creativecommons.org/licenses/by/4.0/>).

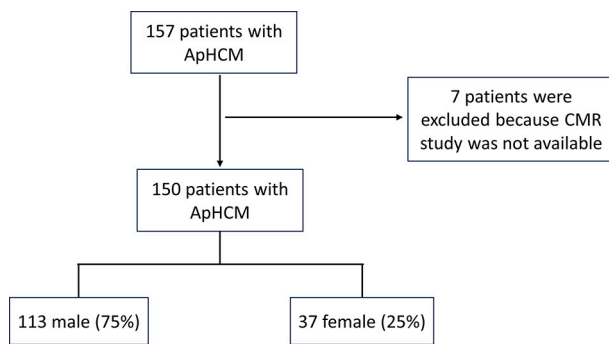


Fig. 1. Flow chart of patient selection in our study.

## 2. Methods

### 2.1. Patient population and data collection

We performed a retrospective observational cross-sectional study of 150 consecutive adult patients ( $\geq 16$  years) with ApHCM who were seen in our specialised inherited cardiac conditions clinic in St George's University Hospital NHS Foundation Trust, London, between 2010 and 2020 and had apical hypertrophy defined as a maximal wall thickness (MWT) of  $\geq 13$  mm on CMR. The prevalence of ApHCM in our centre is estimated at 8–10%. For this study, we analysed 157 patients with ApHCM and excluded 7 patients who did not undergo a CMR study (Fig. 1). This review was conducted in accordance with the Internal Review Board regulations and approval.

The following data were abstracted from electronic medical records: baseline demographic characteristics, age at diagnosis, established ischaemic heart disease (IHD), history of dyslipidaemia, hypertension, diabetes, atrial fibrillation, the trigger for evaluation, symptoms at presentation, family history of HCM and family history of sudden cardiac death (SCD).

We reviewed the 12-lead ECG performed at presentation. Giant T-wave inversion was defined as T-wave inversion that is equal to or  $>10$  mm (1 mV) and deep T-wave inversion as equal to or  $>5$  mm in any electrocardiogram lead at the time of diagnosis.

### 2.2. Cardiovascular magnetic resonance

Patients underwent a CMR scan close to the time of presentation on 1.5 T or 3 T scanners and analysed using Circle CVI: cvi42 software. Volumetric CMR data which included indexed left and right end diastolic and end-systolic volumes, ejection fraction and mass index were taken from confirmed reports. Other parameters were measured by a standard protocol. Wall thickness measurements were taken from end-diastolic short axis views with the exclusion of overlying ventricular trabeculae using the standard 16-segment model. Hypertrophy was defined as  $\geq 13$  mm for all segments. 'Pure' ApHCM was defined as isolated apical hypertrophy and 'mixed' with both apical and septal hypertrophy but with the apex thickest [1,15]. Apical displacement of papillary muscles (PM) was present when the base of PM originated from the apical one-third of the left ventricle (LV) in the apical 4- or 2-chamber views. Systolic obliteration-to-cavity-ratio (%) was defined as the end-systolic obliteration to cavity height. Left atrial (LA) area was obtained in end systole from the frame preceding mitral valve opening and indexed for body surface area. Crypts were defined as  $>50\%$  invagination into normal myocardium. Scar by late gadolinium enhancement was defined visually as present or absent. An apical aneurysm was defined as an akinetic or dyskinetic thinned aneurysmal wall.

### 2.3. Statistics

Statistical analysis was performed using IBM SPSS Statistics version 27 software. Normally distributed continuous variables are presented as means  $\pm$  SD. Categorical variables are reported as counts and percentages. Comparisons between groups were made using the independent t-test for continuous variables and Chi-square analysis for categorical variables. Statistical significance was assumed at  $P$  value  $<0.05$ .

Table 1

Clinical Characteristics and CMR findings by Sex.

Variable	Sex			p value
	Total (150)	Male (113)	Female (37)	
Age at diagnosis	55 $\pm$ 14	52 $\pm$ 14	63 $\pm$ 12	$<0.001$
White ethnicity	55 (37%)	41 (75%)	14 (25%)	
Black ethnicity	37 (25%)	21 (57%)	16 (43%)	
Asian	36 (24%)	29 (81%)	7 (19%)	
Mixed/Other	22 (15%)	22 (100%)	0 (0%)	
Dyslipidaemia	43 (29%)	32 (28%)	11 (30%)	0.87
Hypertension	78 (52%)	53 (47%)	25 (68%)	0.03
Diabetes	9 (6%)	5 (4%)	4 (11%)	0.16
IHD	9 (6%)	7 (6%)	2 (5%)	0.86
Atrial fibrillation	9 (6%)	8 (7%)	1(3%)	0.33
Trigger for evaluation				
Symptoms	88 (59%)	64 (57%)	24 (65%)	0.38
Family screening	6 (4%)	4 (3%)	2 (5%)	0.61
Stroke	5 (3%)	4 (4%)	1 (3%)	0.81
Other	51 (34%)	41 (36%)	10 (27%)	0.3
Symptoms at presentation				
Chest discomfort	59 (39%)	44 (39%)	15 (41%)	0.86
Dyspnoea	16 (11%)	9 (8%)	7 (19%)	0.06
Palpitations	20 (13%)	13 (12%)	7 (19%)	0.25
Syncope	7 (5%)	5 (4%)	2 (5%)	0.81
Family history of HCM	11 (7%)	7 (6%)	4 (11%)	0.35
Family history of SCD	14 (9%)	10 (7%)	4 (11%)	0.49
Giant T wave inversion	41 (27%)	36 (32%)	5 (14%)	0.03
Deep T wave inversion	105 (70%)	85 (75%)	20 (54%)	0.02
Location of deep T wave				
V1-V3	53 (35%)	42 (37%)	11 (30%)	0.41
V4-V6	99 (66%)	81 (72%)	18 (49%)	0.01
II, III, aVF	9 (6%)	7 (6%)	2 (5%)	0.86
I, aVL	14 (9%)	10 (9%)	4 (11%)	0.72
MWT	16 $\pm$ 3	17 $\pm$ 3	16 $\pm$ 3	0.16
'Pure' apical	106 (71%)	77 (68%)	29 (78%)	0.24
'Mixed' type	44 (29%)	36 (32%)	8 (21%)	0.24
Systolic obliteration-to-cavity-ratio (%)	41 $\pm$ 15	40 $\pm$ 15	44 $\pm$ 14	0.16
Apical displacement PM	120 (80%)	89 (79%)	31 (84%)	0.57
Apical Aneurysm	18 (12%)	13 (12%)	5 (14%)	0.72
Crypt	31 (21%)	23 (20%)	8 (22%)	0.87
LV Mass index	81 $\pm$ 26	85 $\pm$ 26	72 $\pm$ 22	0.008
LVEF (%)	73 $\pm$ 7	73 $\pm$ 7	74 $\pm$ 7	0.57
LVEDV index	69 $\pm$ 16	71 $\pm$ 16	62 $\pm$ 14	0.03
LVESV index	19 $\pm$ 7	19 $\pm$ 7	16 $\pm$ 7	0.04
LVS index	50 $\pm$ 12	52 $\pm$ 12	46 $\pm$ 11	0.009
LA index	13 $\pm$ 4	12.5 $\pm$ 3	14.4 $\pm$ 4	0.006
LGE (+)	109 (73%)	84 (74%)	25 (68%)	0.42

IHD, ischaemic heart disease; HCM, hypertrophic cardiomyopathy; SCD, sudden cardiac death; MWT, maximal wall thickness; PM, papillary muscles; LV, left ventricle; LVEF, left ventricular ejection; LVEDV, left ventricular end diastolic volume; LVESV, left ventricular end systolic volume; LVS index, left ventricular stroke volume; LA, left atrium; LGE, late gadolinium enhancement; Variables are n (%); mean  $\pm$  SD.

### 3. Results

#### 3.1. Patient population

We identified and analysed 150 consecutive patients (113, 75% males and 37, 25% females) with ApHCM. The mean age at diagnosis was  $55 \pm 14$  years [range 16–80]. At presentation 78 (52%) patients had a diagnosis of hypertension, 43 (29%) had dyslipidaemia, 9 (6%) were diabetic, 9 (6%) had established ischaemic heart disease and 9 (6%) patients had atrial fibrillation. With regards to family history, 11 (7%) had a family history of HCM and 14 (9%) had a family history of sudden cardiac death (SCD). The main triggers for evaluation or referral were symptoms ( $n = 88$ , 59%), family screening ( $n = 6$ , 4%), stroke ( $n = 5$ , 3%) and other screening which included referral due to an abnormal ECG performed at non-NHS screening programmes ( $n = 13$ , 9%), pre-operation work-up ( $n = 13$ , 9%) and screening due to an existing medical condition such as hypertension ( $n = 25$ , 17%). The most common symptom that triggered evaluation was chest discomfort ( $n = 59$ , 39%). All patients had an abnormal ECG. Giant and deep T-wave inversion were observed in 41 (27%) and 106 (70%) patients at presentation, respectively. The most common location for deep T wave inversion was leads V4 through V6 ( $n = 99$  of patients with deep T wave inversion, 66%) followed by inversion in lead V1 through V3 ( $n = 53$ , 35%). The mean MWT was  $16 \pm 3$  mm. Most patients had the 'Pure' apical variant ( $n = 106$ , 71%), and the remaining individuals had the mixed type ( $n = 44$ , 29%). Patients with hypertension were more likely to have the 'mixed' type (75% vs 43%,  $p < 0.001$ ) and patients with the 'mixed' phenotype were more frequently hypertensive (33/44, 75% vs 11/44, 25%,  $p < 0.001$ ). An apical aneurysm was present in 18 (12%) patients 2 (11%) of whom also presented with stroke whereas only 3 (2.3%) individuals without apical aneurysm had stroke at presentation. LGE was visually confirmed in 109 (73%) individuals and patients with LGE had higher MWT than those without LGE ( $17 \pm 3$  mm vs  $14 \pm 1$  mm,  $p < 0.001$ ). Crypts (at least one) were observed in 31 (21%) individuals. The mean systolic obliteration to cavity ratio was  $41\% \pm 15$  and apical displacement of papillary muscles was observed in 120 (80%) patients. The mean indexed LA size was  $13 + 4$  cm<sup>2</sup>/m<sup>2</sup>.

Genotype data was available for 31, 20.6% of the patients, of which three had a pathogenic variant, and six had variants of unknown significance. Patients were offered genetic testing according to local criteria at the time of referral to the genetic service.

#### 3.2. Association between sex and ApHCM

Females were diagnosed at an older age ( $63 \pm 12$  vs  $52 \pm 14$  years,  $p < 0.001$ ) and were less likely to have giant (14% vs 32%,  $p = 0.03$ ) or deep (54% vs 75%,  $p = 0.02$ ) T-wave inversion on their ECG at presentation compared to their male counterparts. This was most evident in leads V4 through V6 where females had less deep T wave inversion than males (49% vs 72%,  $p = 0.01$ ).

Women in this cohort were more likely to have a diagnosis of hypertension compared to men (68% vs 47%,  $p = 0.03$ ) (Table 1). Men with hypertension had a significantly higher representation of the 'mixed' type of ApHCM compared to those who had the 'pure' apical phenotype (27/36 (75%) vs. 26/77 (34%),  $p < 0.001$ ).

Females had higher LA area index ( $14.4$  vs  $12.5$  cm<sup>2</sup>/m<sup>2</sup>,  $p = 0.006$ ). They also had lower LV mass index ( $72 \pm 22$  vs  $85 \pm 26$  g/m<sup>2</sup>,  $p = 0.008$ ), LVEDV index ( $62 \pm 14$  vs  $71 \pm 16$  ml/m<sup>2</sup>,  $p = 0.03$ ), LVESV index ( $16 \pm 7$  vs  $19 \pm 7$  ml/m<sup>2</sup>,  $p = 0.04$ ) and LSVV index ( $46 \pm 11$  vs  $52 \pm 12$  ml/m<sup>2</sup>,  $p = 0.009$ ) than males. There was no difference between women and men in MWT ( $16 \pm 3$  mm vs  $17 \pm 3$  mm, 0.16), pattern of hypertrophy ('Pure' apical: 29 (78%) vs 77 (68%),  $p = 0.24$ ), systolic obliteration-to-cavity-ratio (44% vs 40%  $\pm 15$ ,  $p = 0.16$ ), apical displacement of papillary muscles ( $n = 31$ , 84% vs  $n = 89$ , 79%,  $p = 0.57$ ) or presence of myocardial crypts ( $n = 8$ , 22% vs  $n = 23$ , 20%,  $p = 0.87$ ). No difference was observed in the percentage of apical aneurysm

**Table 2**

Clinical characteristics and CMR findings by ethnicity.

Variable	p value	Black (37)	White (55)	Asian (36)	p value
Age at diagnosis	0.85	$55 \pm 13$	$55 \pm 15$	$58 \pm 13$	0.4
Hypertension	0.01	26 (70%)	24 (44%)	20 (56%)	0.27
Dyslipidaemia	0.16	6 (16%)	16 (29%)	17 (47%)	0.08
Diabetes	0.34	1 (3%)	4 (7%)	2 (6%)	0.75
IHD	0.15	3 (8%)	1 (2%)	4 (11%)	0.06
Atrial fibrillation	0.09	1 (3%)	7 (13%)	1 (3%)	0.1
Family history of HCM	0.61	4 (11%)	2 (4%)	4 (11%)	0.32
Giant T wave inversion	0.94	9 (24%)	13 (24%)	12 (33%)	0.31
Deep T wave inversion	0.35	27 (73%)	35 (64%)	26 (72%)	0.39
Symptoms at presentation	0.15	27 (73%)	32 (58%)	22 (61%)	0.78
MWT	0.06	$17 \pm 4$	$16 \pm 3$	$16 \pm 3$	0.85
'Pure' apical	0.04	19 (51%)	44 (80%)	27 (75%)	0.57
'Mixed' type	0.04	18 (49%)	11 (20%)	9 (25%)	0.57
Crypt	0.46	7 (19%)	14 (25%)	5 (14%)	0.18
Apical Aneurysm	0.12	2 (5%)	9 (16%)	5 (14%)	0.8
Apical displacement PM	0.56	30 (81%)	41 (75%)	29 (81%)	0.6
Systolic obliteration-to-cavity-ratio (%)	0.06	$43 \pm 16$	$37 \pm 14$	$43 \pm 15$	0.07
LV Mass index	0.01	$92 \pm 31$	$78 \pm 20$	$72 \pm 22$	0.18
LA index	0.61	$13 \pm 3$	$13 \pm 3$	$13 \pm 3$	0.99
LGE (+)	0.39	26 (70%)	43 (78%)	25 (69%)	0.35

IHD, ischaemic heart disease; HCM, hypertrophic cardiomyopathy; MWT, maximal wall thickness; PM, papillary muscles; LV, left ventricle; LA, left atrium; LGE, late gadolinium enhancement; Variables are n (%); mean  $\pm$  SD.

(women:  $n = 5$ , 14% vs men:  $n = 13$ , 12%,  $p = 0.72$ ) or presence of late gadolinium enhancement (women:  $n = 25$ , 68% vs men:  $n = 84$ , 74%,  $p = 0.42$ ) (Table 1).

#### 3.3. Association between ethnicity and ApHCM

Our study population included patients of White (55, 37%), Black (37, 25%), Asian (36, 24%) and Mixed/Other (22, 15%) ethnicity. Black patients were more likely to have a diagnosis of hypertension at presentation compared to White patients (70% vs 40%,  $p = 0.01$ ) (Table 2), and this finding was also evident when we analysed the male group separately (14/21 (67%) vs 15/41 (37%),  $p = 0.03$ ). There was no difference in age at diagnosis, symptoms at presentation, cardiovascular risk factors, or proportion of deep or giant T wave inversion on 12-lead ECG.

Patients of Black ethnicity were more likely to have the 'mixed' type of ApHCM than White (49% vs 20%,  $p = 0.003$ ) and Asian (49% vs 25%,  $p = 0.04$ ) patients who had a higher proportion of the 'pure' apical type. They also had higher LV mass index compared to white individuals ( $92 \pm 31$  vs  $78 \pm 20$ ,  $p = 0.01$ ) and to patients of Asian ethnicity ( $92 \pm 31$  vs  $72 \pm 22$ ,  $p = 0.002$ ). However, there was no significant difference between the ethnicities in MWT (Black vs White:  $17 \pm 4$  vs  $16 \pm 3$ ,  $p = 0.06$  and Asian vs White:  $16 \pm 3$  vs  $16 \pm 3$ ,  $p = 0.85$ ).

There was no difference between ethnicities in the presence of crypts (Black vs White:  $n = 7$  (19%) vs  $n = 14$  (25%),  $p = 0.46$  and Asian vs White:  $n = 5$  (14%) vs  $n = 14$  (25%),  $p = 0.18$ ), apical aneurysm (Black vs White:  $n = 2$  (5%) vs  $n = 9$  (16%),  $p = 0.12$  and Asian vs White: ( $n = 5$  (14%) vs  $n = 9$  (16%),  $n = 0.8$ ), systolic-obliteration-to-cavity-height ratio (Black vs White:  $43 \pm 16$  vs  $37 \pm 14$ ,  $p = 0.06$  and Asian vs White:  $43 \pm 15$  vs  $37 \pm 14$ ,  $p = 0.07$ ), LA index (Black vs White:  $13 \pm 3$  vs  $13 \pm 3$ ,  $p = 0.61$  and Asian vs White:  $13 \pm 3$  vs  $13 \pm 3$ ,  $p = 0.99$ ) or

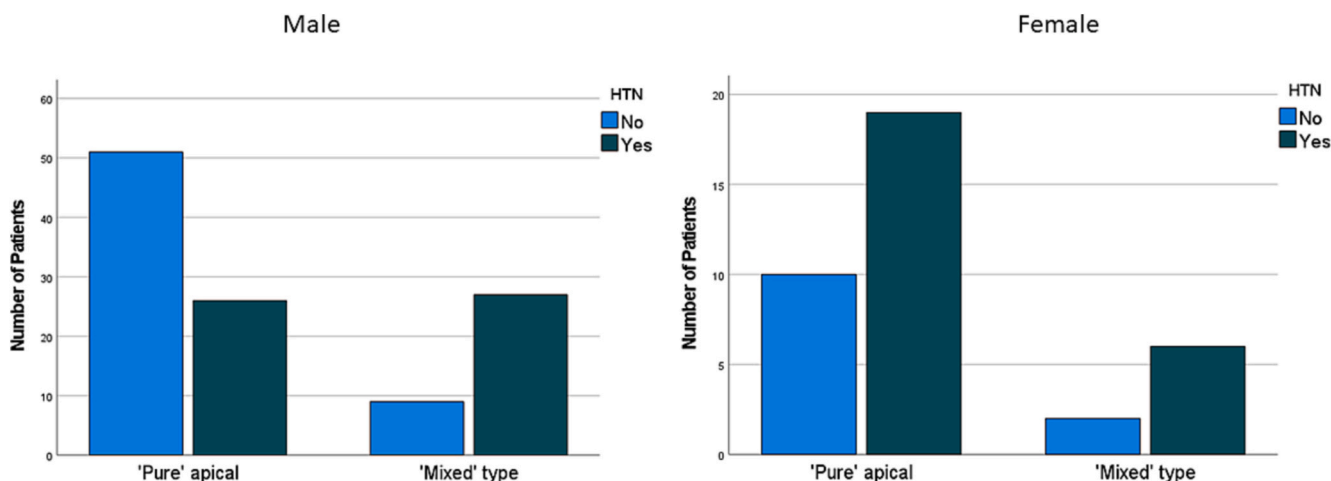


Fig. 2. Pattern of hypertrophy in ApHCM by presence and absence of hypertension. Male patients with hypertension were more likely to have the 'Mixed' type. This relationship was not observed among females in this cohort.

the presence of LGE (Black vs White:  $n = 26$  (70%) vs  $43$  (78%),  $p = 0.39$  and Asian vs White:  $n = 25$  (69%) vs  $43$  (78%),  $p = 0.35$ ) (Table 2).

4. Discussion

This cohort of 150 patients with ApHCM from a single tertiary referral centre helps better understand the phenotypic spectrum of ApHCM and its association with ethnicity and sex.

4.1. Females with ApHCM

Females with ApHCM in this UK-based cohort were diagnosed at an older age compared to men with a mean delay in diagnosis of 11 years. This discrepancy in age at presentation, which has been also reported in

classical HCM [16,17], may partially explain the unexpected observation of male predominance in a disease with an autosomal dominant pattern of inheritance. Multiple factors may contribute to the fact that women were older at the time of diagnosis. Hormonal differences between the sexes may be responsible for delayed manifestation of hypertrophy in women. Indeed, studies in animal models have shown that oestrogen attenuates cardiac hypertrophy [18].

Another factor is under recognition which could be due to social or biologic causes. In our cohort women had significantly less prominent T wave inversion on ECG compared to men. Since the ECG hallmark of ApHCM is the finding of unusually deep T wave inversion [19], its absence in females may have contributed to under recognition of ApHCM and potentially resulted in delayed diagnosis.

Females in this cohort had higher proportion of hypertension and

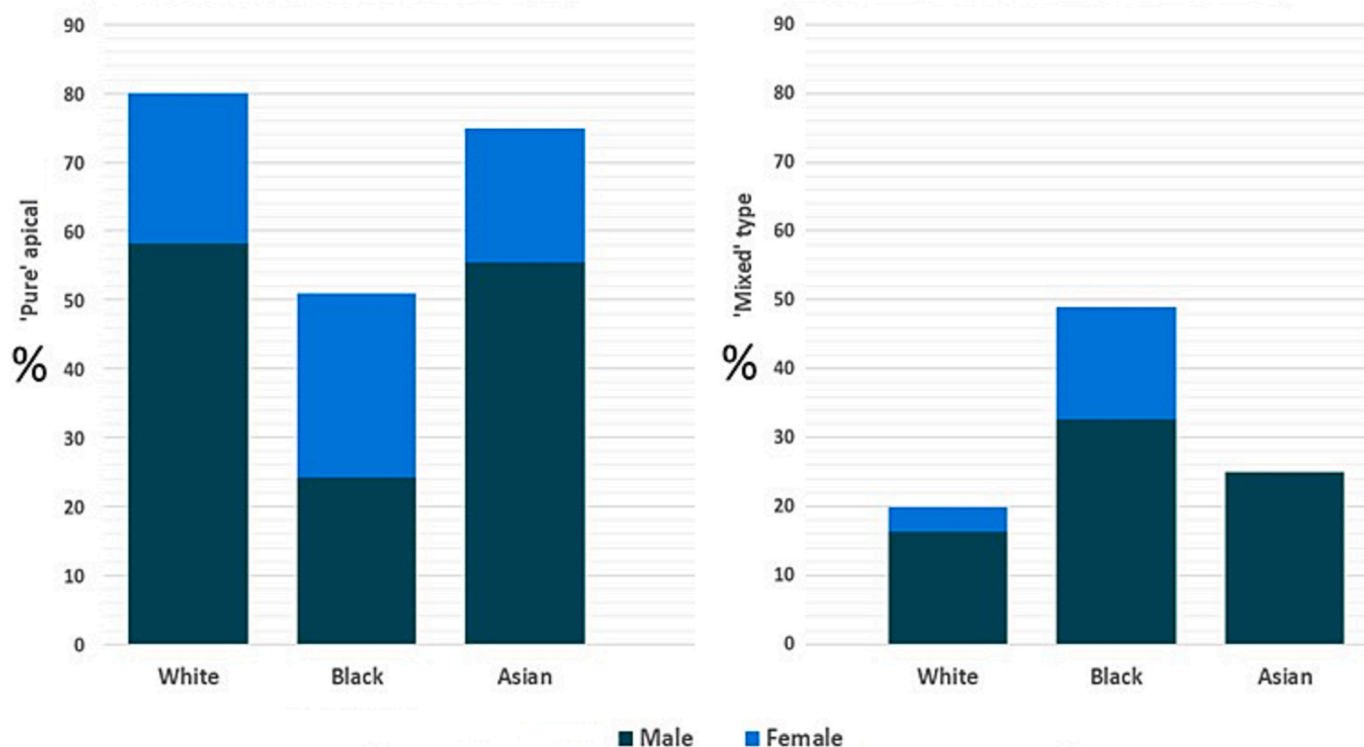


Fig. 3. Pattern of hypertrophy in ApHCM by ethnicity and sex. White and Asian ethnicity had higher proportion of the 'Pure' apical type (left) while Black patients were more likely to have the 'Mixed' type (right).

had higher left atrial area size, both established risk factors for cardiovascular events and atrial fibrillation respectively. Indeed, some studies have suggested that females with HCM have less favourable outcomes than men [6,20]. One study has found that female sex was an independent risk factor for death in ApHCM [21] and females in that study also had a more pronounced LA dilatation and a higher proportion of arterial hypertension and atrial fibrillation than males.

#### 4.2. Hypertension and pattern of hypertrophy

Current data on patterns of hypertrophy in ApHCM is mainly derived from echocardiography studies. To our knowledge this is the first study to rely solely on CMR to evaluate these patterns in relation to ethnicity and sex in ApHCM. Compared to echocardiography, CMR provides a more accurate assessment of left ventricular apical hypertrophy [13].

In our study population, more than two thirds of patients had the 'Pure' apical variant and patients with hypertension had higher proportion of the 'Mixed' type of ApHCM. While predominant apical hypertrophy in the presence of typical T-wave changes on ECG cannot solely be attributed to hypertensive cardiomyopathy, it is likely that arterial hypertension acted as a phenotype modifier in ApHCM patients.

Hypertension is highly prevalent among patients with ApHCM [22]. Basal septal hypertrophy (BSH) is seen in up to 20% of patients with well controlled systemic hypertension [23]. One study has found that patients with mixed ApHCM have higher cardiovascular morbidity [15].

We have found that the association between hypertension and pattern of hypertrophy was clearly demonstrated in the male group but not among females (Fig. 2). Although this could represent a true sex-related difference, it can be merely attributed to the small number of female patients.

#### 4.3. Racial differences in ApHCM

In our cohort, a higher proportion of White and Asian patients had isolated apical hypertrophy whereas patients of Black ethnicity were more likely to have the mixed type compared to other ethnicities (Fig. 3). This pattern of hypertrophy has been associated with a worse prognosis [1].

In agreement with previous studies [9,10], Black patients in our cohort had a higher prevalence of hypertension compared to their White counterparts. Hypertension has been shown to have an adverse effect on outcome in HCM patients irrespective of ethnicity [10].

Some studies on racial differences in HCM have suggested that patients of Black ethnicity have a worse prognosis [9] while others have been less conclusive [24]. Although outcome data on black patients with ApHCM is lacking, our findings highlight that hypertension and pattern of hypertrophy may play an important role in disease manifestation and progression.

#### 4.4. Limitations

This retrospective review intended to enhance our understanding of ApHCM and contribute to improvement in patient care. It was based on real world data from a single tertiary referral centre which could have resulted in referral bias. We therefore encourage other centres to publish their data and examine the generalisability of our findings. The relatively small number of patients in our cohort, especially with regard to female patients, reflects the fact that the apical variant of HCM is an uncommon phenotype and is characterised by male predominance. We have only included patients who had a CMR study and hence our findings may have been subject to selection bias. However, in our centre, CMR is routinely performed in HCM patients and therefore a significant selection bias is less likely (only 7 patients were excluded because they did not undergo a CMR study). Genotype data was not available for all patients.

We included ApHCM patients who had apical hypertrophy of  $\geq 13$

mm although the degree of hypertrophy suggested by guidelines for the diagnosis of ApHCM has been traditionally similar to that of classical HCM (unexplained LVH  $\geq 15$  mm in proband or LVH  $\geq 13$  mm in first degree relative or genotype positive) [12,25] This uniform definition overlooks the fact that the normal myocardium at the apical level is thinner than the basal segments. Furthermore, recent data suggest that patients with ApHCM who fail to reach the diagnostic cut-off of wall thickness  $\geq 15$  mm may not have a benign course as previously believed [26]. Therefore, we have included patients with relative apical hypertrophy ( $13 \leq \text{MWT} < 15$  mm) who also had typical deep T-wave inversion on ECG, which resulted in a lower mean MWT in our study compared to other classical HCM cohorts. This was an observational cross-sectional study; therefore, outcome data was not available.

## 5. Conclusions

This is the first cohort study to use CMR to investigate the association between ethnicity, sex and imaging findings in ApHCM. Both hypertension and ethnicity play an important role in the pattern of hypertrophy in ApHCM. Hypertensive male patients and individuals of Black ethnicity are more likely to present with mixed apical and basal hypertrophy whereas White, Asian and non-hypertensive male patients tend to have hypertrophy limited to the apex. This finding may have prognostic significance and therefore outcome studies are needed.

Females with ApHCM present at an older age and are less likely to have deep T wave inversion on ECG. This should be kept in mind when evaluating females with a suspected diagnosis of ApHCM.

## Declaration of Competing Interest

The authors declare no competing interests.

## Acknowledgments

MTE has received consultancy fees from Bristol-Myer-Squibb and Cytogenetics.

SK has received training grants from the European Society of Cardiology and Israeli Society of Cardiology.

## References

- [1] R.K. Hughes, K.D. Knott, J. Malcolmson, et al., Apical hypertrophic cardiomyopathy: the variant less known, *J. American Heart Assoc.: Cardiovasc. Cerebrovas. Disease*, 9 (5) (2020), <https://doi.org/10.1161/JAHA.119.015294>.
- [2] H. Kitaoka, Y. Doi, S.A. Casey, N. Hitomi, T. Furuno, B.J. Maron, Comparison of prevalence of apical hypertrophic cardiomyopathy in Japan and the United States, *Am. J. Cardiol.* 92 (10) (2003) 1183–1186, <https://doi.org/10.1016/j.amjcard.2003.07.027>.
- [3] J. Binder, S.R. Ommen, B.J. Gersh, et al., Echocardiography-guided genetic testing in hypertrophic cardiomyopathy: septal morphological features predict the presence of myofibrillar mutations, *Mayo Clin. Proc.* 81 (4) (2006) 459–467, <https://doi.org/10.4065/81.4.459>.
- [4] T. Kubo, H. Kitaoka, M. Okawa, et al., Gender-specific differences in the clinical features of hypertrophic cardiomyopathy in a community-based Japanese population: results from Kochi RYOMA study, *J. Cardiol.* 56 (3) (2010) 314–319, <https://doi.org/10.1016/j.jjcc.2010.07.004>.
- [5] P.P. Dimitrov, D. Czarnecka, K.K. Jaszcz, J.S. Dubiel, Sex differences in age at onset of symptoms in patients with hypertrophic cardiomyopathy, *Eur. J. Cardiovasc. Prev. Rehabil.* 4 (1) (1997) 33–35, <https://doi.org/10.1177/174182679700400106>.
- [6] J.B. Geske, K.C. Ong, K.C. Siontis, et al., Women with hypertrophic cardiomyopathy have worse survival, *Eur. Heart J.* 38 (46) (2017) 3434–3440, <https://doi.org/10.1093/eurheartj/ehx527>.
- [7] E.J. Rowin, M.S. Maron, S. Wells, P.P. Patel, B.C. Koethe, B.J. Maron, Impact of sex on clinical course and survival in the contemporary treatment era for hypertrophic cardiomyopathy, *J. Am. Heart Assoc.* 8 (21) (2019), <https://doi.org/10.1161/JAHA.119.012041>.
- [8] Y. Wasserstrum, J.M. Larranaga-Moreira, D. Lotan, et al., Gender variability in the clinical phenotype of hypertrophic cardiomyopathy, *Eur. Heart J.* 41 (Supplement 2) (2020), <https://doi.org/10.1093/ehjci/ehaa946.2089>.
- [9] L.A. Eberly, S.M. Day, E.A. Ashley, et al., Association of Race with disease expression and clinical outcomes among patients with hypertrophic

- cardiomyopathy, *JAMA Cardiol.* 5 (1) (2020) 83–91, <https://doi.org/10.1001/jamacardio.2019.4638>.
- [10] N. Sheikh, M. Papadakis, V.F. Panoulas, et al., Comparison of hypertrophic cardiomyopathy in afro-Caribbean versus white patients in the UK, *Heart.* 102 (22) (2016) 1797–1804, <https://doi.org/10.1136/heartjnl-2016-309843>.
- [11] B.J. Maron, S.R. Ommen, C. Semsarian, P. Spirito, I. Olivotto, M.S. Maron, Hypertrophic cardiomyopathy: present and future, with translation into contemporary cardiovascular medicine, *J. Am. Coll. Cardiol.* 64 (1) (2014) 83–99, <https://doi.org/10.1016/j.jacc.2014.05.003>.
- [12] S.R. Ommen, S. Mital, M.A. Burke, et al., 2020 AHA/ACC guideline for the diagnosis and treatment of patients with hypertrophic cardiomyopathy, *Circulation.* 142 (25) (2020) 558–631, <https://doi.org/10.1161/cir.0000000000000937>.
- [13] R. Fattori, E. Biagini, M. Lorenzini, K. Buttazzi, L. Lovato, C. Rapezzi, Significance of magnetic resonance imaging in apical hypertrophic cardiomyopathy, *Am. J. Cardiol.* 105 (11) (2010) 1592–1596, <https://doi.org/10.1016/j.amjcard.2010.01.020>.
- [14] G. Pons-Lladó, F. Carreras, X. Borrás, J. Palmer, J. Llauger, A. Bayés De Luna, Comparison of morphologic assessment of hypertrophic cardiomyopathy by magnetic resonance versus echocardiographic imaging, *Am. J. Cardiol.* 79 (12) (1997) 1651–1656, [https://doi.org/10.1016/S0002-9149\(97\)00216-6](https://doi.org/10.1016/S0002-9149(97)00216-6).
- [15] C.C. Chen, M.H. Lei, Y.C. Hsu, S.L. Chung, Y.J. Sung, Apical hypertrophic cardiomyopathy: correlations between echocardiographic parameters, angiographic left ventricular morphology, and clinical outcomes, *Clin. Cardiol.* 34 (4) (2011) 233–238, <https://doi.org/10.1002/clc.20874>.
- [16] M.T. Tome Esteban, Gender disease-dose in hypertrophic cardiomyopathy, *Int. J. Cardiol.* 331 (2021) 172–173, <https://doi.org/10.1016/J.IJCARD.2021.01.008>.
- [17] I. Olivotto, M.S. Maron, A.S. Adabag, et al., Gender-related differences in the clinical presentation and outcome of hypertrophic cardiomyopathy, *J. Am. Coll. Cardiol.* 46 (3) (2005) 480–487, <https://doi.org/10.1016/J.JACC.2005.04.043>.
- [18] E. Murphy, Estrogen signaling and cardiovascular disease, *Circ. Res.* 109 (6) (2011) 687–696, <https://doi.org/10.1161/CIRCRESAHA.110.236687>.
- [19] H. Yamaguchi, T. Ishimura, S. Nishiyama, et al., Hypertrophic nonobstructive cardiomyopathy with giant negative T waves (apical hypertrophy): Ventriculographic and echocardiographic features in 30 patients, *Am. J. Cardiol.* 44 (3) (1979) 401–412, [https://doi.org/10.1016/0002-9149\(79\)90388-6](https://doi.org/10.1016/0002-9149(79)90388-6).
- [20] I. Olivotto, M.S. Maron, A.S. Adabag, et al., Gender-related differences in the clinical presentation and outcome of hypertrophic cardiomyopathy, *J. Am. Coll. Cardiol.* 46 (3) (2005) 480–487, <https://doi.org/10.1016/j.jacc.2005.04.043>.
- [21] K.W. Klarich, C.H. Attenhofer Jost, J. Binder, et al., Risk of death in long-term follow-up of patients with apical hypertrophic cardiomyopathy, *Am. J. Cardiol.* 111 (12) (2013) 1784–1791, <https://doi.org/10.1016/j.amjcard.2013.02.040>.
- [22] K.W. Klarich, C.H. Attenhofer Jost, J. Binder, et al., Risk of death in long-term follow-up of patients with apical hypertrophic cardiomyopathy, *Am. J. Cardiol.* 111 (12) (2013) 1784–1791, <https://doi.org/10.1016/j.amjcard.2013.02.040>.
- [23] F. Loncaric, L. Nunno, M. Mimbreno, et al., Basal ventricular septal hypertrophy in systemic hypertension, *Am. J. Cardiol.* 125 (9) (2020) 1339–1346, <https://doi.org/10.1016/j.amjcard.2020.01.045>.
- [24] S. Wells, E.J. Rowin, V. Bhatt, M.S. Maron, B.J. Maron, Association between race and clinical profile of patients referred for hypertrophic cardiomyopathy, *Circulation.* 137 (18) (2018) 1973–1975, <https://doi.org/10.1161/CIRCULATIONAHA.117.032838>.
- [25] J.L. Zamorano, A. Anastasakis, M.A. Borger, et al., 2014 ESC guidelines on diagnosis and management of hypertrophic cardiomyopathy: the task force for the diagnosis and management of hypertrophic cardiomyopathy of the European Society of Cardiology (ESC), *Eur. Heart J.* 35 (39) (2014) 2733–2779, <https://doi.org/10.1093/eurheartj/ehu284>.
- [26] A.S. Flett, V. Maestrini, D. Milliken, et al., Diagnosis of apical hypertrophic cardiomyopathy: T-wave inversion and relative but not absolute apical left ventricular hypertrophy, *Int. J. Cardiol.* 183 (2015) 143–148, <https://doi.org/10.1016/j.ijcard.2015.01.054>.