

Postpartum perineal wound infection and its effect on anal sphincter integrity. Results of a prospective observational study

Nicola Adanna Okeahialam¹ | Ranee Thakar^{1,2} | Abdul H. Sultan^{1,2} ¹Croydon University Hospital, Croydon, UK²St George's University of London, London, UK**Correspondence**

Abdul H. Sultan, Croydon University Hospital, 530 London Road, Thornton Heath, CR7 7YE, UK.

Email: abdulsultan@nhs.net**Abstract**

Introduction: Perineal wound infection can affect tissues at superficial, deep, and organ space levels. Women with obstetric anal sphincter injuries (OASIS) are at risk of infection; however, no study to date has investigated if infection can extend to affect the anal sphincter integrity. The aim of this study was to evaluate the clinical progression of perineal wound infection and its effect on the anal sphincter in women with or without OASIS using three-dimensional endoanal ultrasound (3D-EAUS).

Material and methods: Women were recruited into the Prospective Observational Study Evaluating the Sonographic Appearance of the Anal Sphincter in Women With Perineal Wound Infection Following Vaginal Delivery (PERINEAL Study) between August 2020 and August 2021 (NCT 04480684). 3D-EAUS was performed weekly until complete wound healing. Significant bacterial colonization was diagnosed using the MolecuLight i:X camera. The primary study outcome was a change in a sphincter defect angle from baseline (wound infection) until wound healing. A robust Poisson regression model was used to analyze the effect of significant bacterial loads on the anal sphincter.

Results: Seventy-three women were included. A median of two ultrasound scans were performed in each patient (range 1–16). Five women (6.8%) had an OASI clinically diagnosed at delivery. In total, 250 EAUS were performed. An external anal sphincter defect was found on EAUS in 55 (22.0%) scans ($n = 10$ women). An external anal sphincter and internal anal sphincter defect was found in 26 scans (10.4%) ($n = 3$ women). During the course of the wound healing process, there was no significant change in defect size in wounds with or without significant bacterial colonization. In cases of an intact anal sphincter, wound infection did not disrupt its integrity.

Conclusions: We found that perineal wound infection does not disrupt an intact anal sphincter or OASIS. This new information can provide important information for clinicians and patients. As there are myths frequently encountered in cases of litigation

Abbreviations: 3D, three-dimensional; 4D, four-dimensional; CFU/g, colony-forming units per gram; CI, confidence interval; EAS, external anal sphincter; EAUS, endoanal ultrasound; IAS, internal anal sphincter; IQR, interquartile range; NHS, National Health Service; OASIS, obstetric anal sphincter injuries; TPUS, transperineal ultrasound.

This is an open access article under the terms of the [Creative Commons Attribution-NonCommercial-NoDerivs](https://creativecommons.org/licenses/by-nc-nd/4.0/) License, which permits use and distribution in any medium, provided the original work is properly cited, the use is non-commercial and no modifications or adaptations are made.

© 2023 The Authors. *Acta Obstetrica et Gynecologica Scandinavica* published by John Wiley & Sons Ltd on behalf of Nordic Federation of Societies of Obstetrics and Gynecology (NFOG).

when disruption of sphincter integrity is attributed to perineal infection, the findings of this study should be tested in larger studies in the future.

KEYWORDS

bacterial autofluorescence, endoanal ultrasound, obstetric anal sphincter injury, perineal wound infection, severe perineal laceration, third-degree tears, transperineal ultrasound

1 | INTRODUCTION

Obstetric anal sphincter injuries (OASIS) are a significant cause of anal incontinence and source of medico-legal claims.^{1,2} The National Health Service (NHS) Litigation Authority found in their 10-year analysis (2000–2010) of maternity claims that claims surrounding perineal trauma were the fourth most common, costing over £31 million.² Complications such as wound infection, dehiscence, or delayed healing are causes of severe maternal morbidity.³ In addition, like anal incontinence, wound complications can have a negative psychological and emotional impact on women.^{3,4} Although anal incontinence is multifactorial in etiology, the integrity of the anal sphincter is important in maintaining continence.⁵ However, despite primary repair, approximately 60% of women will have a persistent anal sphincter defect diagnosed on ultrasound and 39% will experience anal incontinence.^{1,6} Wound infection can be superficial but can also extend to disrupt tissue and fascia at a deep and organ space level.⁷ Up to 20% of women with OASIS will experience wound complications such as wound infection or dehiscence following primary repair.⁸ Therefore, as the anal sphincter is deep to the superficial and deep perineal muscles in the posterior plane, we hypothesized that wound infection may potentially disrupt a primary sphincter repair, causing a sphincter defect or increasing the size of a sphincter defect. However, to date, no study has evaluated the clinical progression of perineal wound infection and the effect it may have on anal sphincter integrity following OASI or in cases of an intact anal sphincter.

The aim of this study was to evaluate the clinical progression of perineal wound infection and whether anal sphincter integrity can be disrupted in women with and without OASIS.

2 | MATERIAL AND METHODS

The Prospective Observational Study Evaluating the Sonographic Appearance of the Anal Sphincter in Women With Perineal Wound Infection Following Vaginal Delivery (PERINEAL Study was completed at Croydon University Hospital), which runs a dedicated perineal clinic service where all women with perineal concerns such as perineal wound infection can be referred for review, up to 16 weeks postpartum. Croydon University Hospital has approximately 3700 deliveries per year; however, this perineal clinic service also accepts referrals from local general practitioners and surrounding maternity units. All patients who had been referred to the Croydon University

Key Message

In cases of an intact anal sphincter and obstetric anal sphincter injury, wound infection did not disrupt anal sphincter integrity during the healing process.

Hospital dedicated perineal clinic with perineal wound infection were invited to participate. Women were diagnosed with perineal wound infection if they presented with relevant clinical signs and symptoms, including perineal pain, purulent discharge, or wound dehiscence.⁹ All participants had been reviewed and prescribed appropriate antibiotics before referral to the clinic. Following informed consent, all women underwent perineal assessment, including clinical review, advanced wound imaging using bacterial autofluorescence imaging, and ultrasound assessment of the anal sphincter.

As women received antibiotics before recruitment, wounds were imaged to assess the presence of significant bacterial loads despite antibiotic use, with the hand-held MolecuLight I:X imaging device. This non-contact device stimulates bacteria with a 405-nm violet light and has been shown to be highly predictive in moderate to heavy (significant) bacterial loads ($\geq 10^4$ colony-forming units per gram [CFU/g]), as it causes them to emit a red or cyan fluorescence.¹⁰ With bacterial loads greater than 10^4 CFU/g, although there may be no overt clinical signs of infection, this level of bacterial colonization can suggest persistent infection and delay wound healing.¹¹

Three-dimensional endoanal ultrasound (3D-EAUS) was performed using the Pro-focus 2202 or Flex-focus 500 ultrasound system (BK Medical) fitted with a 12- to 16-MHz anorectal transducer (type 2052; focal point up to 20 mm and focal range 5–45 mm, with 360-degree acquisition). On 3D-EAUS, anal sphincter defect sizes were measured using a three-point angle with images taken at the deep (proximal), superficial (mid), and subcutaneous (distal) levels.¹² An external anal sphincter (EAS) defect was diagnosed if there was any hypoechoic or mixed-echogenic disruption within the hyperechoic muscle. An internal anal sphincter (IAS) defect was diagnosed if there was any hyperechoic disruption within the hypoechoic muscular ring. If 3D-EAUS was declined, then four-dimensional transperitoneal ultrasound (4D-TPUS) was performed using the GE Voluson S10 ultrasound system with a RAB 8- to 4-MHz transducer (GE Medical Systems). Anal sphincter defect size was measured using a three-point angle from slice two to slice seven of the transverse images of the length of the anal sphincter on tomographic

ultrasound imaging. The largest defect angle was taken into account.¹³ The severity of anal sphincter defects was scored using the validated Starck Score, which accounts for depth, length, and size of the defect for both the IAS and EAS, with a range from 0 being no defect to 16 being maximal defect.¹⁴ Image volumes were stored for off-line assessment by two independent experts (RT, AS). As participants were scanned weekly, ultrasound volumes were analyzed with a week's interval and each investigator was blinded to the results of the previous scan to avoid bias due to repeated measurements. Any disagreements between the two independent experts (RT, AS) were resolved with consensus decision.

A missed OASI was diagnosed if an anal sphincter defect was found on EAUS at initial review, but was not diagnosed clinically at the time of birth. Women were reviewed once a week with repeat ultrasound imaging until the wound had healed completely, or up to a maximum of 16 weeks. A wound was deemed to have healed if there was complete wound closure, with no evidence of granulation tissue or signs of infection such as perineal pain, edema or purulent discharge. No local antibiotic or antiseptic treatments were applied to wounds.

The recruitment period was between August 2020 and August 2021. Eligibility criteria were women with childbirth-related perineal injury and wound infection, age 18 years or over, and ability to understand and read the patient information sheet (in English). Exclusion criteria were the inability to give informed consent, fetal or neonatal death or poor neonatal outcome, and immunosuppression (for example HIV infection or pharmacologically induced immunodeficiencies by chemotherapy or steroids).

The primary study outcome was a change in a sphincter defect size, measured using a three-point radial angle from baseline (wound infection) until wound healing. The secondary outcome was a change in sphincter defect severity measured using the Starck Score from baseline (wound infection) until wound healing. As EAUS is considered the reference standard modality for evaluation of the anal sphincter, this was used as the primary outcome measure. Our study exposure was the presence of significant bacterial colonization. As results from microbiological wound swabs take up to 5 days,¹⁵ the presence of significant bacterial colonization in these wounds was assessed using the MolecuLight I:X imaging device. The Strengthening the Reporting of Observational Studies in Epidemiology (STROBE) guidelines were used to ensure the reporting of this observational study.¹⁶

2.1 | Statistical analyses

As we aimed to evaluate whether wound infection could extend to affect the anal sphincter and as the anal sphincter is deep to the superficial and deep perineal muscles, we developed a sample size calculation by estimating the percentage of women that could potentially develop a deep wound infection. A deep wound infection was defined as a wound infection that involves the deep soft tissues (muscle/fascia) and/or was associated with systemic symptoms

such as fever ($>38^{\circ}\text{C}$) based on the Centers for Disease Control and Prevention criteria.¹⁷ Based on the number of referrals to the Croydon University Hospital dedicated perineal clinic in 2019 (120 women), a sample size of 80 women was proposed, taking into account women meeting the inclusion and exclusion criteria and subject attrition. Previous data estimated that up to 24% of women with perineal trauma will experience perineal wound infection.¹⁸ However, 5% may have a deep wound infection.¹⁹ To account for the degree of uncertainty due to lack of previous published data surrounding the effect of wound infection on anal sphincter integrity, with a proposed sample size of 80, a corresponding 95% confidence interval (CI) for the percentage women with a deep wound infection would range between 1% and 12%.

Data were analyzed using SPSS version 26.0.0.0 and STATA version 15.1. The Shapiro–Wilk test was used to check normality of continuous variables including age, body mass index, defect angle size, and Starck Score. Nominal data are expressed as number and percentage. Continuous variables were compared using Student's *t* test, or the Mann–Whitney *U* test where appropriate. Fisher's exact test was used for categorical variables. A Poisson regression model was used to analyze the effect of significant loads of bacteria on the anal sphincter during the wound healing process. As there were multiple measurements from the same patients it is likely the data values were not independent of each other. Based on the assumed distribution of outcome, the regression models were implemented with robust standard errors to allow for the lack of independence within the data. Models initially included the interaction between fluorescence and time. If the interaction term was significant, it was retained in the model and a different relationship for each group was assumed. If the interaction term was not significant, this was omitted from the model and a constant change over time for the two groups was assumed. A corresponding *p*-value less than 0.05 was considered statistically significant. If women were lost to follow up they were excluded from the analysis.

2.2 | Ethics statement

Ethical approval was obtained from NHS Health Research Authority, London—Surrey Research Ethics Committee (20/LO/0304) on April 8, 2020. In addition, the study was registered in <https://clinicaltrials.gov/> (NCT 04480684).

3 | RESULTS

During the recruitment period, 115 women were referred to the dedicated perineal clinic with perineal wound infection, of whom 82 (71.3%) agreed to participate. Two women (2.4%) were lost to follow up; so, the follow-up rate was 97.6%. Four women (5.0%) were diagnosed with a deep wound infection. **Figure 1** shows the participant flow chart. In order to avoid disrupting the postnatal recovery of women with poor neonatal outcomes, they were excluded from

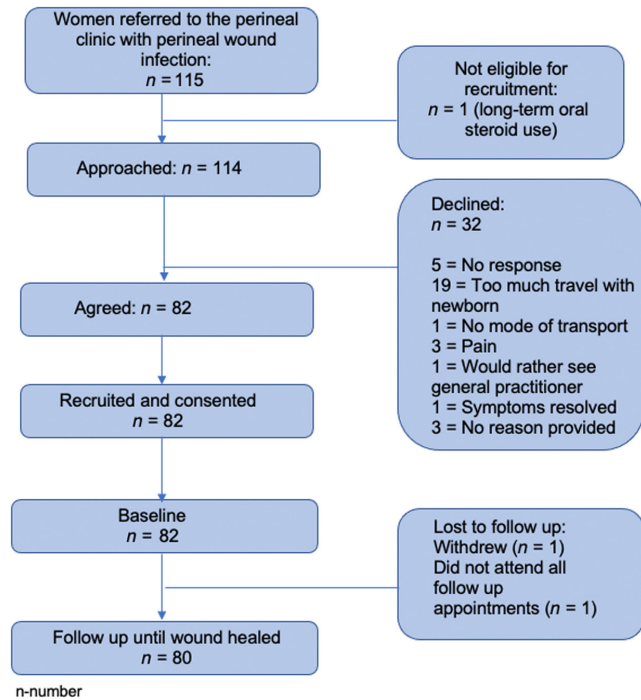


FIGURE 1 Flow chart describing the recruitment and progress of participants in the cohort study.

recruitment because of the sensitive nature of their birth. Of the 15 women that were multiparous, none had a history of a previous OASI.

Women were referred to the perineal clinic a median of 10 days (interquartile range [IQR] 7.0–14.0) following symptom onset and 6 days (IQR 3.0–8.0) from diagnosis and antibiotic receipt. The time to wound infection resolution and complete wound healing ranged between 1 and 16 weeks (median 2 weeks, IQR 1–4 weeks). [Table 1](#) describes the demographic characteristics of the recruited women. Five women (6.3%) had an OASI clinically diagnosed at delivery; of these, 3 (60.0%) had a mediolateral episiotomy.

Of the 80 women, 73 (91.1%) agreed to undergo 3D-EAUS. Of these, five (6.8%) had an OASI diagnosed on ultrasound that was not clinically diagnosed at the time of delivery and 4 (80.0%) had a mediolateral episiotomy. The missed OASIS were not resutured because the superficial perineal muscles had healed and none of the women had fecal incontinence. Patients were made aware of their diagnosis and were informed to return if they developed any symptoms. A median of two ultrasound scans were performed in each patient (range 1–16). Twenty-eight women (38.4%) had bacterial fluorescence within their wound despite antibiotic therapy. In total, 250 EAUS were performed. Of the seven women who declined EAUS and underwent 4D-TPUS, only one had an anal sphincter defect (EAS alone). Her wound did not have bacterial fluorescence and took 4 weeks to heal. The largest defect angle at each time-point is shown in [Figure S1](#).

Among the 73 included women, an EAS defect was found in 55 (22.0%) scans ($n = 10$ women) and both EAS and IAS defects were found in 26 (10.4%) scans ($n = 3$ women). Bacterial fluorescence

was present in the wounds on initial review in four women with an EAS defect ($n = 30$ scans). In those with an IAS defect, three women ($n = 15$ scans) had bacterial fluorescence. In every patient with a sphincter defect on initial review, this persisted on every scan. In patients with an intact anal sphincter, no new defect developed.

In order to analyze the longitudinal change in sphincter defect size during the wound healing process and its relationship to the presence of bacterial fluorescence, analysis was restricted to data from weeks 1 to 6 only, as from week 7 onwards there were measurements from only three women or fewer. The regression model showed that there was no significant difference in EAS or IAS defect angle in wounds with or without fluorescence during wound healing. In addition, no significant difference was found between EAS defect angle ($p = 0.85$) or IAS defect angle ($p = 0.21$) in OASIS sutured or those missed (not sutured). On average, the ratio of EAS angles with fluorescence to those without fluorescence was 1.20 (95% CI 0.32–4.51, $p = 0.78$) ([Figure 2](#)). In addition, the ratio of IAS angle with fluorescence compared with without was 1.16 (95% CI 0.12–11.1, $p = 0.90$) ([Figure 3](#)). However, there was no resulting increase in the Starck Score per week and no difference was found in wounds with or without bacterial fluorescence.

4 | DISCUSSION

This is the first study to evaluate anal sphincter integrity in the context of perineal wound infection. This prospective observational study demonstrated that during the course of wound healing, wound infection did not disrupt an intact anal sphincter or OASIS. In addition, in approximately 7% of patients with wound infection, a diagnosis of OASIS was missed at the time of delivery.

We demonstrated that there was no significant difference between EAS or IAS defect size during the wound healing process between OASIS that were sutured and those missed (not sutured). The EAS is made up of striated muscle whereas the IAS is a thickened continuation of the inner circular smooth muscle of the rectum. Therefore, when injured, the anal sphincter muscles can retract over time. Although this was seen in this study, the increase in defect angle in wounds with or without infection was not significant. However, in comparison to striated muscle, smooth muscle has greater elastic properties, meaning that muscle retraction may be greater with IAS.^{20,21} In addition, over the course of the wound healing process that there was no significant change in defect angle size in the presence of significant bacterial loads. This is an important finding, as anal sphincter defect severity on EAUS has been shown to correlate with anal incontinence severity.²² However, despite wound infection being a known complication occurring following primary OASI repair, no study to date has investigated the effect of wound infection on anal sphincter integrity. Although wound infection can extend to deeper tissues in the presence of wound injury or perforation of a viscus, it does not typically transit through intact muscle fascia. In cases of necrotizing fasciitis, bacteria release enzymes and exotoxins that can spread through fascia, causing cell

TABLE 1 Study population characteristics

	Positive bacterial fluorescence (n = 30) Mean/median /n	SD/IQR/%	Negative bacterial fluorescence (n = 50) Mean/Median /n	SD/IQR/%	p-value
Age (y)	28.0	5.9	30.4	4.4	0.06***
BMI (kg/m ²)	24.5	5.3	24.9	5.1	0.71***
Ethnicity					
White British	12	40.0	27	54.0	0.34*
Asian Indian/Pakistani/other Asian Background/Southeast Asian	14	46.7	18	36.0	
Black African/Caribbean	4	13.3	3	6.0	
Any other ethnic group	0	0	2	4.0	
Parity					
1	23	76.7	42	84.0	0.42**
≥2	7	23.3	8	16.0	
Smoker (n = 7)	4	13.4	3	6.0	0.42*
Non-smoker (n = 73)	26	86.7	47	94.0	
Co-morbidities (n = 18)	10	33.3	8	16.0	0.07**
No co-morbidities (n = 62)	20	66.7	42	84.0	
Mode of delivery					
SVD	20	66.7	31	62.0	0.52*
Forceps	2	6.7	7	14.0	
Ventouse	4	13.3	9	18.0	
Ventouse + Forceps	4	13.3	3	6.0	
OASI ^a (n = 10)	3	10.0	7	14.0	0.74*
No OASI (n = 70)	27	90.0	43	86.0	
Positive wound swab (n = 54)	20	74.1	34	70.8	1.00**
Negative wound swab (n = 21)	7	25.9	14	29.2	
Antibiotics received (n = 76)	29	96.7	47	94.0	0.56*
No antibiotics received (n = 4)	1	3.3	3	6.0	
Days between review and antibiotics	6	3–7	6	3–7	0.35****
Days from symptom onset to perineal clinic review	19	15–26	17	14–22	0.31****

Abbreviations: BMI, body mass index; IQR, interquartile range; OASI, obstetric anal sphincter injury; SD, standard deviation; SVD, spontaneous vaginal delivery.

^aCo-morbidities identified included gestational diabetes, hypothyroidism and rheumatoid arthritis (unmedicated).

*Fisher's exact test; **Chi-squared test; ***Student's t-test; ****Mann–Whitney U-test.

death and necrosis.²³ Necrotizing fasciitis can occur in the perineum and reports of this complication following vaginal birth have been published previously.^{24,25} However, we acknowledge that there were only 10 women in our study with OASIS.

Women with OASIS are at an increased risk of wound infection due to the anatomical location of these tears and their close proximity to the rectum, as wound contamination can occur from organisms on the surrounding perineal skin and endogenous mucosal surfaces. As a result of this risk, the Royal College of Obstetricians and Gynaecologists recommend the use of prophylactic antibiotics during OASI repair.²⁶ It is important for clinicians to appreciate that although OASI increases the risk of wound infection, if infection were to occur despite prophylactic management, this has little effect on anal sphincter integrity.

Perineal wound infection following vaginal birth has been described to often be a major source of anxiety reported by women within the first month following perineal trauma.²⁷ Moreover, OASI and its associated sequelae can cause significant psychosocial distress, particularly feelings of shame and isolation in those experiencing anal incontinence.²⁸ No study previously has evaluated the effect of wound infection on the anal sphincter and it is therefore timely that research surrounding perineal wound infection and OASIS is conducted.

The strengths of this study include that it had a high follow-up rate of 98.3%. Second, the study design, comprised prospective collection of the data and review of the women on a weekly basis, which provided an accurate picture of the clinical progression of wound infection and healing. Moreover, a validated scoring system was used

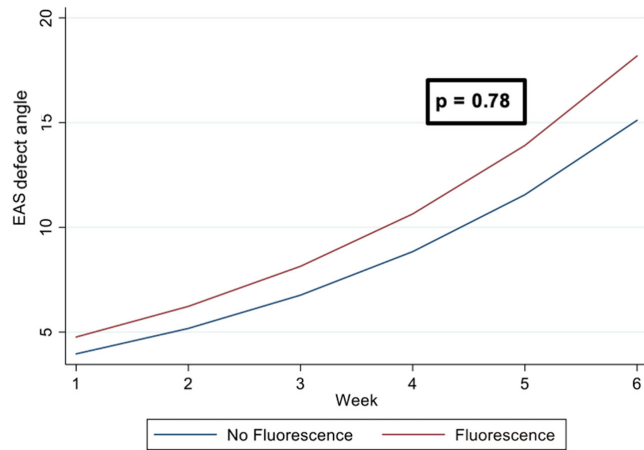


FIGURE 2 External anal sphincter (EAS) angle change over time in wounds with and without bacterial fluorescence using a Poisson regression model. $N = 73$ women (250 scans). Women with no EAS defect were coded as having a defect of 0° . The y-axis represents the predicted count of events from the original scale (EAS defect angle).

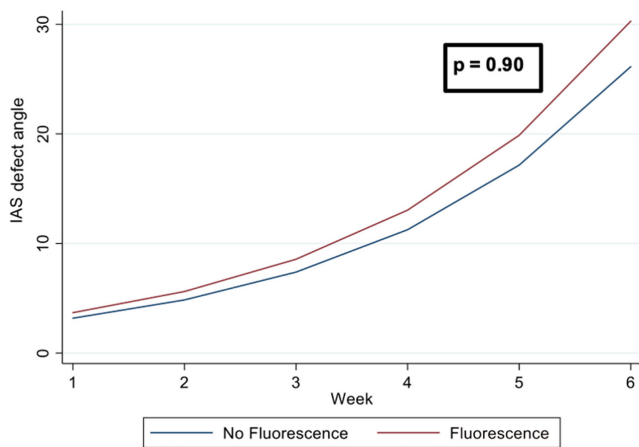


FIGURE 3 Internal anal sphincter (IAS) angle change over time in wounds with and without bacterial fluorescence using a Poisson regression model. $N = 73$ women (250 scans). Women with no IAS defect were coded as having a defect of 0° . The y-axis represents the predicted count of events from the original scale (IAS defect angle).

to assess ultrasound scan findings and all scans were reviewed independently by two reviewers offline (RT, AS), who were blinded to the clinical history to avoid bias. However, limitations should be acknowledged. First, only 10 women had a sphincter defect on EAUS, equating to 55 ultrasound images. However, as it is reported that OASI complicates approximately 3% of vaginal births and the risk of wound infection in the group has been reported to affect up to 20% of women, this is a representative number.^{8,29} However, in this study, it was important that we also included women without OASI because we aimed to evaluate the clinical progression of wound infection and assess if deeper structures, such as the anal sphincter (with or without previous injury) can be affected. As a result of the design of observational studies, the statistical associations we have found may not imply causality.

It is important to note that the baseline EAUS were not performed at the time when perineal wound infection was diagnosed. Wounds were reviewed on average 6 days following diagnosis, which means that our study findings may not truly reflect the effect of wound infection on the anal sphincter. To account for this we performed bacterial fluorescence imaging, which allowed us to diagnose wounds with bacterial loads of more than 10^4 CFU/g (quantitative analysis)/2+ (semi-quantitative analysis) despite antibiotic therapy, which can suggest persistent infection and lead to a delay in wound healing.¹¹ Hurley et al performed a prospective observational study investigating the use of the MolecuLight device in the evaluation of a range of wound types in a plastic surgery outpatient service, in comparison with microbiological swab analysis.³⁰ This study found that when using microbiological analysis of swab results as the reference standard, bacterial autofluorescence imaging had a sensitivity of 100%, a specificity of 78%, a positive predictive value of 95.4%, and a negative predictive value of 100% at predicting the presence of bacteria in wounds.³⁰

5 | CONCLUSION

We found that perineal wound infection does not disrupt an intact anal sphincter or OASIS. This new information can provide important information for clinicians and patients. As there are myths frequently encountered in cases of litigation when disruption of sphincter integrity is attributed to perineal infection, the findings of this study should be tested in larger studies in the future.

AUTHOR CONTRIBUTIONS

NAO contributed to conceptualization, methodology, data curation, investigation, writing the original draft, and visualization. RT and AHS contributed to conceptualization, methodology, resources, investigation, writing—review and editing, and supervision.

ACKNOWLEDGMENTS

We would like to thank P. Bassett at Statsconsultancy Ltd for support with the statistical analysis.

FUNDING INFORMATION

The Croydon Childbirth Charitable Trust has provided an educational grant for the first author.

CONFLICT OF INTEREST

The authors have stated explicitly that there are no conflicts of interest in connection with this article.

ORCID

Abdul H. Sultan  <https://orcid.org/0000-0001-8979-2304>

REFERENCES

1. Sideris M, McCaughey T, Hanrahan JG, et al. Risk of obstetric anal sphincter injuries (OASIS) and anal incontinence: a meta-analysis. *Eur J Obstet Gynecol Reprod Biol.* 2020;252:303-312.

2. NHS Litigation Authority. *Ten Years of Maternity Claims: An Analysis of NHS Litigation Authority Data*. 2012 Accessed February 8, 2021. <http://www.nhs.uk/safety/Documents/Ten%20Years%20of%20Maternity%20Claims%20-%20An%20Analysis%20of%20the%20NHS%20LA%20Data%20-%20October%202012.pdf>
3. Dudley L, Kettle C, Waterfield J, Ismail KMK. Perineal resuturing versus expectant management following vaginal delivery complicated by a dehiscence wound (PREVIEW): a nested qualitative study. *BMJ Open*. 2017;7:e013008.
4. Keighley MRB, Perston Y, Bradshaw E, Hayes J, Keighley DM, Webb S. The social, psychological, emotional morbidity and adjustment techniques for women with anal incontinence following obstetric anal sphincter injury: use of a word picture to identify a hidden syndrome. *BMC Pregnancy Childbirth*. 2016;16:275.
5. Scott SM, Lunniss PJ. Investigations of anorectal function. In: Sultan AH, Thakar R, Fenner DE, eds. *Perineal and Anal Sphincter Trauma: Diagnosis and Clinical Management*. Springer; 2007:102-122.
6. Sultan AH, Thakar R. Third and fourth degree tears. In: Sultan AH, Thakar R, Fenner DE, eds. *Perineal and Anal Sphincter Trauma. Diagnosis and Clinical Management*. Springer; 2007:33-51.
7. European Centre for Disease Prevention and Control. Stockholm. Healthcare-associated infections: surgical site infections. Annual Epidemiological Report for 2017. Published online 2019. https://www.ecdc.europa.eu/sites/default/files/documents/AER_for_2017-SSI.pdf
8. Lewicky-Gaupp C, Leader-Cramer A, Johnson LL, Kenton K, Gossett DR. Wound complications after obstetric anal sphincter injuries. *Obstet Gynecol*. 2015;125:1088-1093.
9. Johnson A, Thakar R, Sultan AH. Obstetric perineal wound infection: is there underreporting? *Brit J Nurs*. 2012;21:S28-S35.
10. Rennie MY, Lindvere-Teene L, Tapang K, Linden R. Point-of-care fluorescence imaging predicts the presence of pathogenic bacteria in wounds: a clinical study. *J Wound Care*. 2017;26:452-460.
11. Xu L, McLennan SV, Lo L, et al. Bacterial load predicts healing rate in neuropathic diabetic foot ulcers. *Diabetes Care*. 2007;30:378-380.
12. Sultan AH, Kamm MA, Hudson CN, Thomas JM, Bartram CI. Anal-sphincter disruption during vaginal delivery. *N Engl J Med*. 1993;329:1905-1911.
13. AIUM/IUGA practice parameter for the performance of Urogynecological ultrasound examinations: developed in collaboration with the ACR, the AUGS, the AUA, and the SRU. *J Ultrasound Med*. 2019;38:851-864.
14. Starck M, Bohe M, Valentin L. Results of endosonographic imaging of the anal sphincter 2-7 days after primary repair of third- or fourth-degree obstetric sphincter tears: endosonographic imaging after anal sphincter tear repair. *Ultrasound Obstet Gynecol*. 2003;22:609-615.
15. Bowler PG, Duerden BI, Armstrong DG. Wound microbiology and associated approaches to wound management. *Clin Microbiol Rev*. 2001;14:244-269.
16. von Elm E, Altman DG, Egger M, Pocock SJ, Gøtzsche PC, Vandenbroucke JP. The strengthening the reporting of observational studies in epidemiology (STROBE) statement: guidelines for reporting observational studies. *Lancet*. 2007;370:1453-1457.
17. Horan TC, Gaynes RP, Martone WJ, Jarvis WR, Emori TG. CDC definitions of nosocomial surgical site infections, 1992: a modification of CDC definitions of surgical wound infections. *Infect Control Hosp Epidemiol*. 1992;13:606-608.
18. Jones K, Webb S, Manresa M, Hodgetts-Morton V, Morris RK. The incidence of wound infection and dehiscence following childbirth-related perineal trauma: a systematic review of the evidence. *Eur J Obstet Gynecol Reprod Biol*. 2019;240:1-8.
19. Knight M, Chiochia V, Partlett C, et al. Prophylactic antibiotics in the prevention of infection after operative vaginal delivery (ANODE): a multicentre randomised controlled trial. *Lancet*. 2019;393:2395-2403.
20. Thakar R, Fenner DE. Anatomy of the perineum and the anal Sphincter. In: Sultan AH, Thakar R, Fenner DE, eds. *Perineal and Anal Sphincter Trauma: Diagnosis and Clinical Management*. Springer; 2007:1-12.
21. Jaslove JM, Nelson CM. Smooth muscle: a stiff sculptor of epithelial shapes. *Phil Trans R Soc B*. 2018;373:20170318.
22. Patton V, Kumar S, Parkin K, Karantanis E, Dinning P. The relationship between residual sphincter damage after primary repair, faecal incontinence, and anal sphincter function in primiparous women with an obstetric anal sphincter injury. *NeuroUroUrodyn*. 2019;38:193-199.
23. Davoudian P, Flint NJ. Necrotizing fasciitis. *Continuing Education in Anaesthesia Critical Care & Pain*. 2012;12:245-250.
24. Almarzouqi F, Grieb G, Klink C, et al. Fatal necrotizing fasciitis following episiotomy. *Case Reports Surg*. 2015;2015:1-4.
25. Medhi R, Rai S, Das A, Ahmed M, Das B. Necrotizing fasciitis - a rare complication following common obstetric operative procedures: report of two cases. *Int J Womens Health*. 2015;7:357-360.
26. Royal College of obstetrics and Gynaecology. Management of third and fourth degree perineal tears. Greentop Guideline number 29. Published online June 2015. Accessed November 11, 2020. <https://www.rcog.org.uk/globalassets/documents/guidelines/gtg-29.pdf>
27. Li WY, Liabsuetrakul T, Stray-Pedersen B. Effect of mode of delivery on perceived risks of maternal health outcomes among expectant parents: a cohort study in Beijing, China. *BMC Pregnancy Childbirth*. 2014;14:12.
28. Darmody E, Bradshaw C, Atkinson S. Women's experience of obstetric anal sphincter injury following childbirth: an integrated review. *Midwifery*. 2020;91:102820.
29. Thiagamoorthy G, Johnson A, Thakar R, Sultan AH. National survey of perineal trauma and its subsequent management in the United Kingdom. *Int Urogynecol J*. 2014;25:1621-1627.
30. Hurley CM, McClusky P, Sugrue RM, Clover JA, Kelly JE. Efficacy of a bacterial fluorescence imaging device in an outpatient wound care clinic: a pilot study. *J Wound Care*. 2019;28:438-443.

SUPPORTING INFORMATION

Additional supporting information can be found online in the Supporting Information section at the end of this article.

How to cite this article: Okeahialam NA, Thakar R, Sultan AH. Postpartum perineal wound infection and its effect on anal sphincter integrity. Results of a prospective observational study. *Acta Obstet Gynecol Scand*. 2023;00:1-7. doi:[10.1111/aogs.14515](https://doi.org/10.1111/aogs.14515)