






Expanding the phenotype of *TAB2* variants and literature review

Emily Woods¹  | Imogen Marson²  | Emanuele Coci^{3,4} | Michael Spiller⁵ |
Ajith Kumar⁶ | Angela Brady⁷ | Tessa Homfray⁸ | Richard Fisher⁹ |
Peter Turnpenny¹⁰ | Julia Rankin¹⁰ | Farah Kanani¹¹  | Konrad Platzer¹² |
Athina Ververi⁶ | Eleftheria Emmanouilidou¹³ | Nourxan Bourbon¹⁴ |
George Giannakoulas¹⁴  | Meena Balasubramanian^{11,15} 

¹Department of Paediatrics, Sheffield Children's Hospital NHS Foundation Trust, Sheffield, UK

²Medical School, University of Sheffield, Sheffield, UK

³Department of Pediatrics, Prignitz Hospital, Brandenburg Medical School, Prignitz, Germany

⁴Department of Clinical Genetics, Copenhagen University Hospital Rigshospitalet, Copenhagen, Denmark

⁵Sheffield Diagnostic Genetics Service, Sheffield Children's NHS Foundation Trust, Sheffield, UK

⁶Department of Clinical Genetics, Great Ormond Street Hospital, London, UK

⁷Clinical Genetics Service, Northwick Park Hospital, London, UK

⁸Clinical Genetics Service, St George's Hospital, London, UK

⁹Northern Genetics Service, Newcastle University Hospital NHS Trust, Newcastle, UK

¹⁰Peninsula Clinical Genetics Service, Royal Devon and Exeter NHS Trust, Exeter, UK

¹¹Sheffield Clinical Genetics Service, Sheffield Children's NHS Foundation Trust, Sheffield, UK

¹²Institute of Human Genetics, University of Leipzig Medical Center, Leipzig, Germany

¹³Department of Paediatrics, General Hospital of Kavala, Kavala, Greece

¹⁴Cardiology Department, AHEPA University Hospital, Aristotle University of Thessaloniki, Thessaloniki, Greece

¹⁵Department of Oncology & Metabolism, University of Sheffield, Sheffield, UK

Correspondence

Meena Balasubramanian, Sheffield Clinical Genetics Service, Sheffield Children's Hospital NHS Foundation Trust, Western Bank, Sheffield S10 2TH, UK.

Email: meena.balasubramanian@nhs.net; balasubramanian@sheffield.ac.uk; m.balasubramanian@sheffield.ac.uk

Funding information

Wellcome

[Correction added on 1 September 2022, after first online publication: The article category was changed.]

Abstract

TAB2 is a gene located on chromosome 6q25.1 and plays a key role in development of the heart. Existing literature describes congenital heart disease as a common recognized phenotype of *TAB2* gene variants, with evidence of a distinct syndromic phenotype also existing beyond this. Here we describe 14 newly identified individuals with nine novel, pathogenic *TAB2* variants. The majority of individuals were identified through the Deciphering Developmental Disorders study through trio whole exome sequencing. Eight individuals had *de novo* variants, the other six individuals were found to have maternally inherited, or likely maternally inherited, variants. Five individuals from the same family were identified following cardiac disease gene panel in the proband and subsequent targeted familial gene sequencing. The clinical features of this cohort were compared to the existing literature. Common clinical features

This is an open access article under the terms of the [Creative Commons Attribution-NonCommercial-NoDerivs](https://creativecommons.org/licenses/by-nc-nd/4.0/) License, which permits use and distribution in any medium, provided the original work is properly cited, the use is non-commercial and no modifications or adaptations are made.

© 2022 The Authors. *American Journal of Medical Genetics Part A* published by Wiley Periodicals LLC.

include distinctive facial features, growth abnormalities, joint hypermobility, hypotonia, and developmental delay. Newly identified features included feeding difficulties, sleep problems, visual problems, genitourinary abnormality, and other anatomical variations. Here we report 14 new individuals, including novel *TAB2* variants, in order to expand the emerging syndromic clinical phenotype and provide further genotype-phenotype correlation.

KEYWORDS

congenital heart disease, developmental delay, facial features, joint hypermobility, syndromal, *TAB2*

1 | INTRODUCTION

TAB2 has proven association with congenital heart defects as part of an emerging wider distinct syndrome, however, it is currently still classified as a cause of nonsyndromic congenital heart disease according to Online Mendelian Inheritance in Man (OMIM #614980). Emerging non-cardiac associations include distinctive facial features, growth abnormalities, hypotonia, developmental delay and connective tissue abnormalities (Cheng et al., 2017), (Caulfield et al., 2018), (Thienpont et al., 2010), (Ritelli et al., 2018). Described facial features include frontal bossing,

short/ narrow palpebral fissures, dental problems, ptosis, and hypertelorism (Cheng et al., 2017), (Wade et al., 2016), (Wade et al., 2017). So far, there has been no distinct difference in phenotype between intragenic variants and deletions (Engwerda et al., 2021).

Some of the existing literature primarily focused on cardiac implications, and provide little clinical information on extra-cardiac features, insufficient to make meaningful comparisons. Here we provide cohort data of 14 patients, in comparison to existing literature, to quantify some of the emerging additional extra-cardiac features with the aim of adding to the larger syndromal picture.

TABLE 1 Interpretation and criteria for pathogenic variants

No	Variant	Criteria	Inheritance	Zygosity	Prediction
1	c.1660C > T p.(Gln554Ter) Chr6:g.149397660C > T DECIPHER ID: 280286	PM2 PVS1 PS2_sup	De novo	Heterozygous	Nonsense, expected to undergo NMD
2	c.712C > T p.(Gln238Ter) Chr6:g.149378627C > T DECIPHER ID: 274309	PM2 PVS1 PS2_mod	De novo	Heterozygous	Nonsense, expected to undergo NMD
3	c.973C > T p.(Gln325Ter) Chr6:g.149378888C > T DECIPHER ID: 265804	PM2 PVS1 PS2_mod	De novo	Heterozygous	Nonsense, expected to undergo NMD
4	c.878C > G p.(Ser293Ter) Chr6:g.149378793C > G DECIPHER ID: 260227	PM2 PVS1 PS2_mod	De novo	Heterozygous	Nonsense, expected to undergo NMD
5	c.1321C > T p.(Arg441Ter) Chr6:g.149379236C > T DECIPHER ID: 305581	PM2 PVS1 PS4_sup PS2_mod	De novo	Heterozygous	Nonsense, expected to undergo NMD
6	c.1636C > T p.(Arg546Ter) Chr6:g.149397636C > T DECIPHER ID: 283585	PM2 PVS1 PS2_mod PP1	De novo	Heterozygous	Nonsense, expected to undergo NMD
7, 8	c.1061C > A p.(Ser354Ter) Chr6:g.149378976C > A DECIPHER ID: 293239	PM2 PVS1	Maternal inheritance	Heterozygous	Nonsense, expected to undergo NMD
9	c.1448del p.(Pro483Leufs*16) Chr6:g.149379359TC > T DECIPHER ID: 436382	PM2 PVS1 PS2_sup	De novo	Heterozygous	Frameshift, expected to undergo NMD
10, 11, 12, 13, 14	c.668del p.(Gly223Valfs*20) No DECIPHER ID	PM2 PVS1 PP1_mod	Possibly maternally inherited in 11, 13. Maternally inherited in 10, 12, 14	Heterozygous	Frameshift, expected to undergo NMD

Note: All variants are annotated using transcript NM_015093.5. Genomic co-ordinates are in build GRCh38. ACMG Criterion applied (Ellard et al., 2020; Richards et al., 2015): PS2: De novo (both maternity and paternity confirmed) in a patient with the disease and no family history. Used at moderate (mod) or supporting (sup) depending on phenotype consistency. PVS1: null variant (nonsense, frameshift, canonical ± 1 or 2 splice sites, initiation codon, single or multiexon deletion) in a gene where LOF is a known mechanism of disease. PM2: Absent from controls in gnomAD database, used at supporting level. PP1_mod: Co-segregation with disease in four affected family members in a gene definitively known to cause the disease. PP4_Patient's phenotype or family history highly specific for a gene. No corresponds to patient number. DECIPHER ID corresponds to entry of open access variant on <https://decipher.sanger.ac.uk> (Database of genomic variation and Phenotype in Humans using Ensembl Resources) (Swaminathan et al., 2012).

TABLE 2 Clinical features of cohort

Patient number	1 (Figure 1)	2 (Figure 2)	3 (Figure 3)	4	5
Age	22 years	4 years 6 months	20 years	12 m	8 m
Sex	M	M	F	F	M
Pregnancy	Complicated	Uncomplicated	Complicated	Complicated	Uncomplicated
Gestation	38 weeks	39 weeks	40 weeks	40 weeks	39 weeks
Birth weight (centile)	7%	2.46 kg (3%)	3.1 kg (23%)	3.3 kg (42%)	3 kg (25%)
Latest growth parameters	Weight 37.5 kg Height 151 cm HC 54 cm (2%–9%)	Weight 0.4%–2% Height <0.4%	Weight 76.5 kg (99%) Height 153.8 cm (2%–9%) HC 51.9 cm (0.4%–9%)	—	Weight, height, HC 1%
Dysmorphic features	Downslanted palpebral fissures Dental crowding Two retained deciduous molars	Anteverted nares Long philtrum Downslanting palpebral fissures Sagging cheeks	Facial asymmetry High forehead Broad nose Upslanting palpebral fissures High-arched palate Dental overcrowding Tapering fingers Wide spaced nipples Pes planus	—	Frontal bossing hypertelorism
Growth abnormality	Short stature	Short stature	Short stature	FTT	FTT
Congenital heart defect	Bicuspid aortic valve Mild mitral regurgitation Detected on screening post-diagnosis	Tricuspid regurgitation mitral valve Detected post-natal period	Thickening of Mitral valve prolapse Moderate mitral regurgitation	Ventricular septal defect Aortic valve stenosis Pulmonary valve stenosis	Ventricular septal defect
Connective tissue abnormality	—	Joint hypermobility	Joint hypermobility Soft doughy skin	—	—
Musculoskeletal abnormality	Hypotonia Normal muscle biopsy	Hypotonia Delayed bone age	Hypotonia Delayed bone age	—	—
Gastrointestinal abnormality	Feeding difficulty Poor Suck	Feeding difficulty, neonatal jaundice, GOR, jejunostomy	Constipation	Feeding difficulty (neonatal)	—
Genitourinary abnormality	Glandular Hypospadias	—	—	—	—
Vision/ hearing	—	Rod-cone dystrophy Night blindness	Left sided hearing loss Strabismus-hypoplastic medial and lateral rectus	—	—
Developmental delay	Global delay	Global delay	Global delay	—	—
Social/ communication	Impaired	—	Impaired	—	—
Intellectual disability	Yes	Yes	Yes	—	—
Educational support	—	—	Yes	—	—
Behavioral/ sleep problems	Yes Self-injurious behavior Poor sleep patterns	—	Yes	—	—
Patient number	6	7 (mother of patient 8) (Figure 4)	8 (Figure 5)	9	10 (familial proband)
Age	6 years 9 months	46 years	12 years 6 months	8 years	19 years
Sex	F	F	M	F	F
Pregnancy	Complicated	Complicated	Complicated	Uncomplicated	Uncomplicated
Gestation	41 weeks	38 weeks	38 weeks	40 weeks	38 weeks
Birth weight (centile)	3.7 kg (75%)	—	3.6 kg (83%)	73%	3.34 kg (50%) HC 65%
Latest growth parameters	Height 1% HC 34%	Height 149.3 cm (0.4% and 2%) HC 75%–90%	Height 149 cm (25%–50%)	Weight 23% Height 13% HC 22%	Height 147 cm Weight 45 kg
Dysmorphic features	Frontal bossing Depressed nasal bridge	Facial asymmetry Mild ptosis Hypertrichosis	Epicanthic folds Mild ptosis 2nd and 5th finger clinodactyly Bifid uvula Pes planus Hypertrichosis	Long downslanting palpebral fissures Prominent middle face Two lower incisors (two missing)	Hypertelorism Downslanted palpebral fissures Epicanthus Dental crowding High-arched palate Low-set ears Broad chest Cubitus valgus
Growth abnormality	Short stature	Short stature	Short stature, now normalized	Short stature	Short stature, FTT as infant
Congenital heart defect	Tricuspid regurgitation	—	—	VSD (patch repair at 8 weeks)	Atrial septal defect Mitral valve prolapse/ regurgitation

(Continues)

TABLE 2 (Continued)

Patient number	6	7 (mother of patient 8) (Figure 4)	8 (Figure 5)	9	10 (familial proband)	
				Tricuspid and mitral valve prolapse Bicuspid aortic valve Pulmonary stenosis Dilated ascending aorta		
Connective tissue abnormality	—	—	—	Joint hypermobility	Wandering spleen, joint hypermobility	
Musculoskeletal abnormality	—	C3 C4 vertebral abnormality Lumbar hyperlordosis	Osseous coalition ankles	Hypotonia	Hypotonia as infant	
Gastrointestinal abnormality	Feeding difficulty	—	—	—	Feeding problems as infant, Stenosis of coeliac artery	
Genitourinary abnormality	—	—	—	—	—	
Vision/ hearing	—	—	Congenital conductive hearing loss	Strabismus	—	
Developmental delay	—	—	—	Global delay	Motor delay	
Social/communication	—	—	—	Impaired	—	
Intellectual disability	—	—	—	Yes	—	
Educational support	—	—	—	Yes	—	
Behavioral/sleep problems	—	—	—	Yes	Sleep apnoea	
Patient number	11 (mother of proband)	12 (brother of proband)	13 (maternal aunt of proband)	14 (cousin of proband - son of 13)	Summary incidence	Cumulative incidence in literature (Table 2 + Table 3)
Age	54 years	32 years	58 years	23 years		
Sex	F	M	F	M		
Pregnancy	—	Uncomplicated	—	—		
Gestation	38 weeks	40 weeks	—	—		
Birth weight/ centile	—	—	—	—		
Latest growth parameters	Height 150 cm	Height 170 cm	Height 165 cm	Height 170 cm		
Dysmorphic features	Hypertelorism Downslanted palpebral fissures Epicanthus Dental crowding Low-set ears Broad chest Cubitus valgus	Hypertelorism Downslanted palpebral fissures Epicanthus Dental crowding Low-set ears	Downslanted palpebral fissures Epicanthus Dental crowding Low-set ears	Hypertelorism Downslanted palpebral fissures Epicanthus Dental crowding High-arched palate Low-set ears Broad chest Cubitus valgus Small hands and feet	13/14	61/81 (75%)
Growth abnormality	Short stature	Short stature	—	Short stature, FTT as an infant and toddler	13/14	48/81 (59%) short stature 6/81 (7%) short limbs
Congenital heart defect	Mitral valve prolapse/ regurgitation	Mitral valve prolapse	Hypertrophic subaortic stenosis	Mitral valve regurgitation	12/14	71/81 (87%)
Connective tissue abnormality	Joint hypermobility	Joint hypermobility	? (unprecipitated subarachnoid hemorrhage)	Joint hypermobility	7/14	37/81 (46%) hypermobility or connective tissue problem
Musculoskeletal abnormality	—	—	—	Congenital hip dislocation Perthes of hip	5/14 Hypotonia 2/14 Delayed bone age 3/14 “Other”	18/81 (22%) hypotonia
Gastrointestinal abnormality	—	—	—	—	6/14 (Feeding difficulty 5/14)	Not previously quantified
Genitourinary abnormalities	—	Cryptorchidism requiring surgery	—	Cryptorchidism	3/14	Not previously quantified
Vision/ hearing	—	—	—	—	3/14 Vision 2/14 Hearing	Vision not previously quantified 21/81 (26%) hearing problem
Developmental delay	—	Motor delay	—	—	6/14	25/81 (30%)
Social/ communication	—	—	—	—	3/14	Not previously quantified

TABLE 2 (Continued)

Patient number	11 (mother of proband)	12 (brother of proband)	13 (maternal aunt of proband)	14 (cousin of proband - son of 13)	Summary incidence	Cumulative incidence in literature (Table 2 + Table 3)
Intellectual disability	—	—	—	—	4/14	Not previously quantified
Educational support	—	—	—	—	2/14	Not previously quantified
Behavioral/ sleep problems	—	—	—	—	3/14 Behavioral 2/14 Sleep problem	Not previously quantified

2 | MATERIALS AND METHODS

Patients 1–8 were identified through the Deciphering Developmental Disorders (DDD) study, recruited via UK regional Clinical Genetics Centres following routine referral. Trio-based whole exome sequencing was performed on the individuals and their parents. This was carried out at the Wellcome Trust Sanger Institute using Agilent 2x1M for array-based comparative genomic hybridization, Illumina 800 K SNP genotyping to identify copy number variants, and Agilent SureSelect 55 MB Exome Plus with Illumina HiSeq for exome sequencing (Wright et al., 2015).

Patient 9 was identified through trio whole exome sequencing following normal microarray. The exome capture was carried out with BGI Exome kit capture (59 M) and the library was then sequenced on a BGISEQ-500, paired-end 100 bp, at BGI laboratory in Shenzhen, China. Analysis of the raw data was performed using the software Varfeed (Limbus, Rostock, Germany) and the variants were annotated and prioritized using the software Varvis (Limbus, Rostock, Germany).

Patient 10 was identified through specific cardiac disease panel comprising 682 genes. Other individuals in the familial cohort (Patients 11–14) were identified using targeted genetic testing of the known identified familial *TAB2* variant.

Table 1 provides information on pathogenic *TAB2* variants reported in this cohort. Table 2 provides detailed clinical description of our current cohort whilst Table 3 provides an overview of published literature on *TAB2* variants. Figures 1–5 demonstrate images of Patient 1, 2, 3, 7 and 8 respectively (see details in figure legends) over the years.

3 | RESULTS OF PATHOGENIC *TAB2* VARIANTS

3.1 | Discussion

TAK1 binding protein 2 (*TAB2*) is a gene (OMIM * 605101) located on chromosome 6q25.1, which encodes for TGF-beta-activated kinase 1 and MAP3K7-binding protein 2, a kinase complex member that participates in activation of nuclear factor kappa-B and activator protein-1 (Takaesu et al., 2000). With over 100 genes identified within 6q25.1, *TAB2* lies within the critical CNV region, therefore has

potential for significant impact on foetal development (Thienpont et al., 2010) (Table 1).

It has been proven that *TAB2* plays a role in Interleukin (IL)-1 pathway and an important role in structural cardiac development and cardiac myocyte function. Research focused on human embryos using immunohistochemistry, revealed cytoplasmic expression of *TAB2* in the cells of the cardiac outflow tracts, aortic valves and ventricular trabeculae (Thienpont et al., 2010). Zebrafish models have shown that there is a dose sensitive role during development; haploinsufficiency of *TAB2* caused developmental defects, with apparent phenotype at dose expression reduction of 41%–58% (Thienpont et al., 2010). More recent cohort studies have shown that individuals with *TAB2* microdeletions predispose to primary cardiomyopathy and reduced systolic function, even in the absence of concurrent congenital structural defects such as valvular or septal defects (Cheng et al., 2017). MAP3K7 regulates myocyte homeostasis by induction of cell apoptosis/ necrosis, therefore when MAP3K7 signaling is reduced as a result of *TAB2*; there is preference for cell death, leading to cardiomyopathy and cardiac dysfunction (Li et al., 2014).

Variability of expressed heart defect has also shown to be apparent, with some individuals with the same variant expressing different cardiovascular complications (Cheng et al., 2017). This is evidenced in patients 10, 11, 12, 13, and 14 who have the same familial *TAB2* variant, with differing cardiac involvement including: hypertrophic subaortic stenosis, atrial septal defect, but 4/5 having a form of mitral valve involvement. Cardiovascular outflow tract defects were in keeping with those previously described in the literature including bicuspid aortic valve, pulmonary, mitral and tricuspid valve abnormalities, septal defects and aortic root dilatation.

Heart defects, short stature, and facial dysmorphism can also be seen in other genetic conditions such as Noonan Syndrome and RASopathies, and should be considered as clinical differentials. Engwerda et al. (2021) recently described 80% of their *TAB2* cohort to have dysmorphisms comparable to Noonan Syndrome. Patient 11 had received a clinical diagnosis of Noonan Syndrome in adolescence before *TAB2* variant was genetically identified later in life. However, valvular anomalies are increasingly seen in *TAB2*, relative to these conditions. There should also be consideration of variant co-occurrence in patients with complex phenotype. In Patient 1, a de novo c.162_163del p.(His54Glnfs*11) *KMT2E* likely pathogenic variant was also identified and thought contributory to a composite phenotype. Overlapping features of

TABLE 3 (Continued)

Paper	Permanyer et al., 2020	Ritelli et al., 2018	Ritelli et al., 2018	Thienpont et al 2010	Wade et al., 2016	Wade et al., 2017	Weiss et al 2015	Vasilescu et al., 2018
Dysmorphic features	Broad foreheads, mild ptosis, elongated facies with characteristic gaze, dental malpositions				Supraorbital ridges, small chin, hypertelorism, downslanting palpebral fissures, wide nasal bridge, flared metaphyses	Prominent supraorbital ridges, hypertelorism, downslanting palpebral fissures, broad nasal bridge, full cheeks, micrognathia		
Growth abnormality	Short stature	1/3 Short stature, 3/3 Short limbs, 2/3 small extremities, 2/3 lumbar/sacral anomalies, 2/3 joint contractures/limitations	Short stature, short limbs		Scoliosis, elbow contractures/dislocated radial head, digital and wrist contractures, under modeled phalanges, broad thumbs and fingers	Scoliosis, ulnar deviation of the hands, long fingers		
Cardiac abnormality	6/6 mitral valve regurgitation, 3/6 tricuspid valve regurgitation, 2/6 bicuspid valve regurgitation, 3/6 pulmonary valve regurgitation.	2/3 Dilated cardiomyopathy, 2/3 arrhythmias 3/3 MV, 2/3 TV, 2/3 AV dystrophy/insufficiency, 1/3 atrial septum aneurysm, 1/3 bicuspid AV, 1/3 aortic root dilatation, 1/3 MNC	Dilated cardiomyopathy, arrhythmias MV + TV + AV dystrophy/insufficiency, atrial septum aneurysm	2/3 have aortic stenosis, 2/3 tachycardia, 1/3 AF, 1/3 sick sinus syndrome			1/3 SVT and AF 1/3 aortic valve stenosis, 1/3 bicuspid aortic valve, 3/3 mitral valve defect, 3/3 tricuspid valve defect, 1/3 VSD, 1/3 Tetralogy of Fallot	Dilated cardiomyopathy
Connective tissue abnormality		2/3 Joint hypermobility	Joint hypermobility					
Muscle abnormality								
Developmental delay								
Intellectual disability	None							
Hearing loss		3/3 Hearing loss	Hearing loss		Hearing loss	Hearing loss		

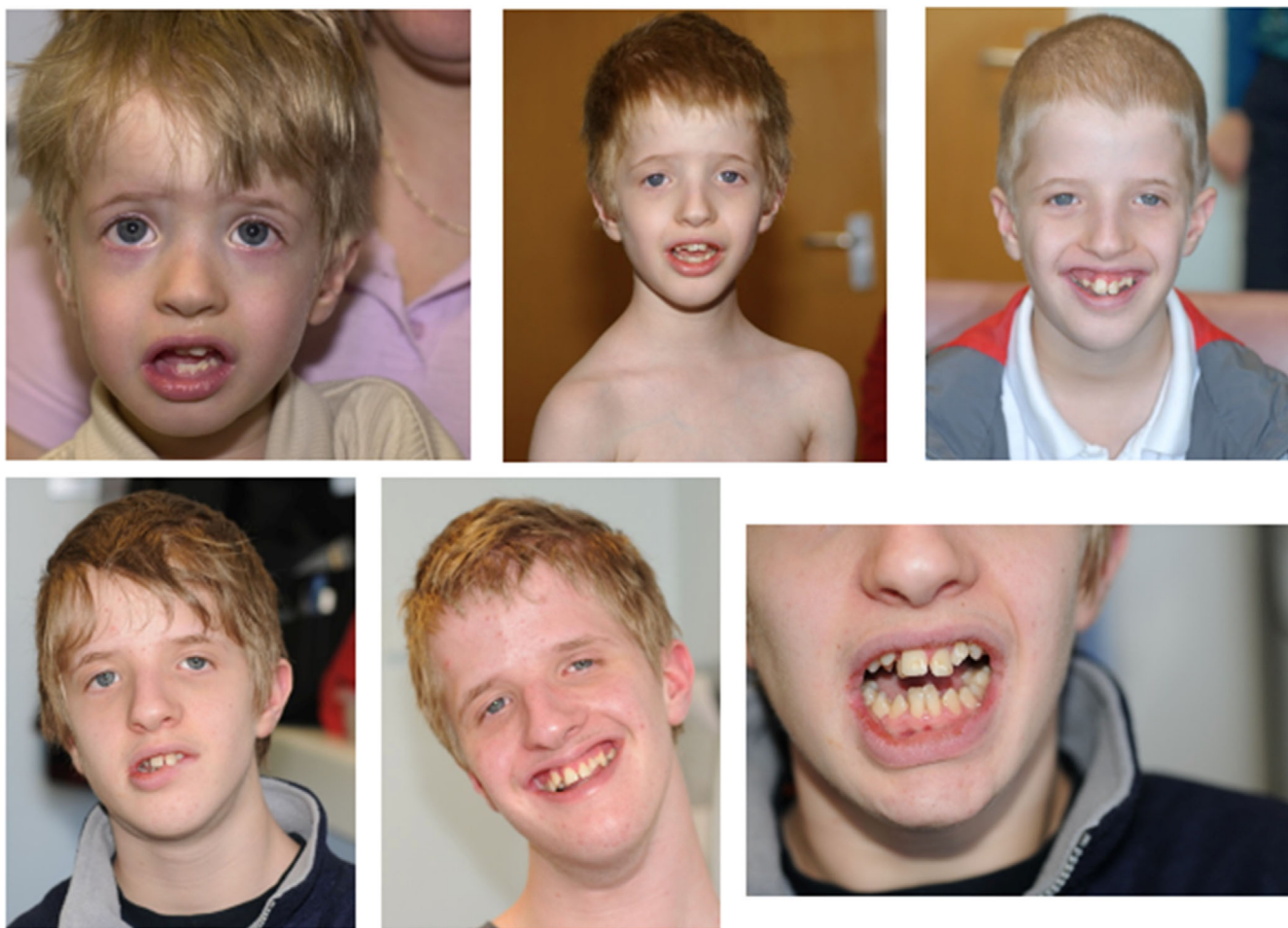

FIGURE 1 Patient 1 at 3, 8, 11, 14, and 19 years of age demonstrating facial dysmorphism of downslanting palpebral fissures and dental crowding

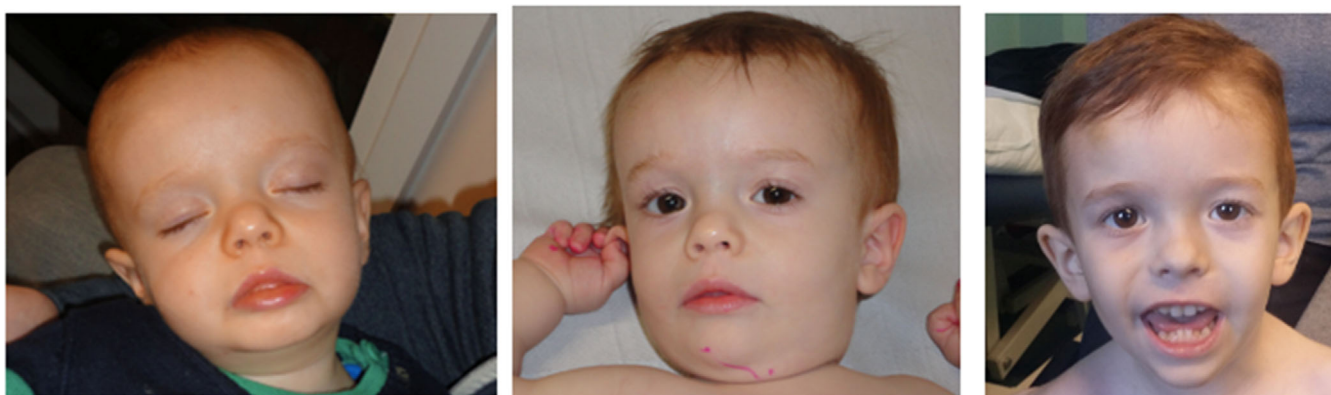

FIGURE 2 Patient 2 aged 7 months, 20 months, and 4 years 5 months demonstrating anteverted nares, long philtrum, and downslanting palpebral fissures

both genetic variants included hypotonia, developmental delay, and intellectual disability. Microcephaly could be attributed to *KMT2E*, whereas facial phenotype and cardiac problems were attributed to *TAB2*. There were no other patients with dual diagnosis in our cohort.

Heart defects can also be seen in connective tissue disorders, such as Marfan syndrome, which indicates the cross-over pathology of both cardiac and connective tissue phenotype seen in *TAB2*. For example, TGF-beta pathway signaling has been indicated in some connective tissue disorders and in *TAB2* (Ackerman

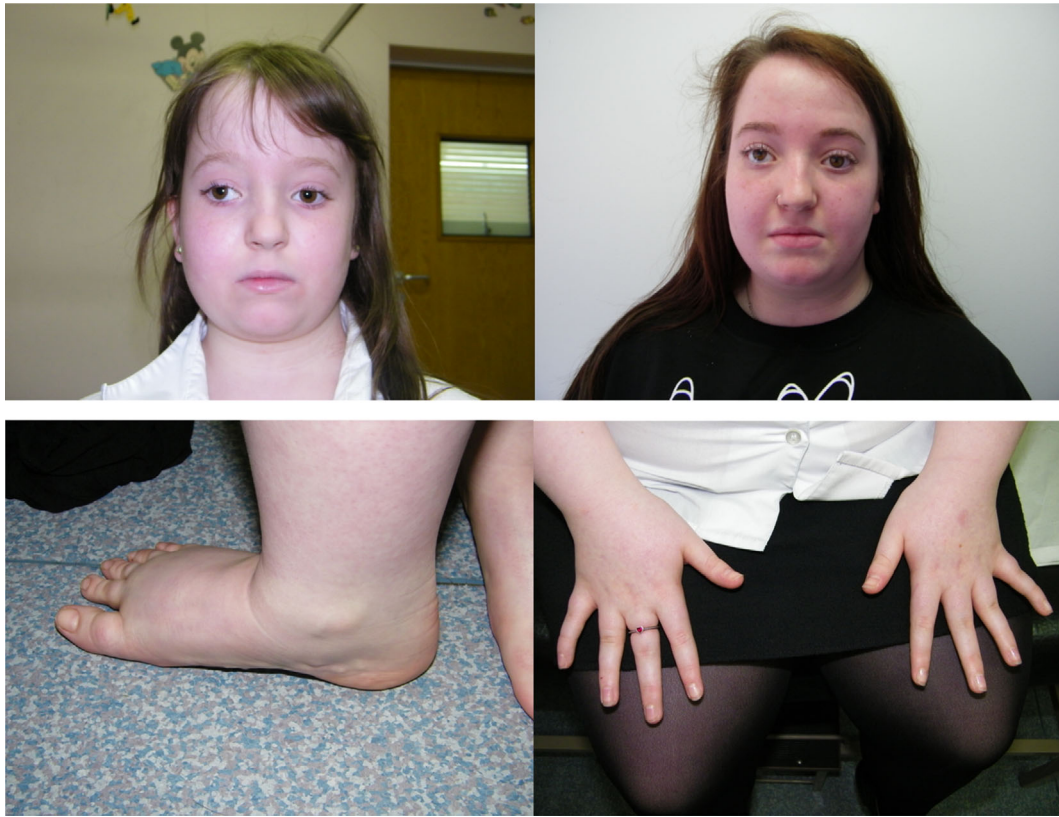

FIGURE 3 (a) Patient 3 showing pes planus and wide spaced fingers. Patient 3 at age 12 years 9 months and age 20 years showing facial asymmetry and strabismus

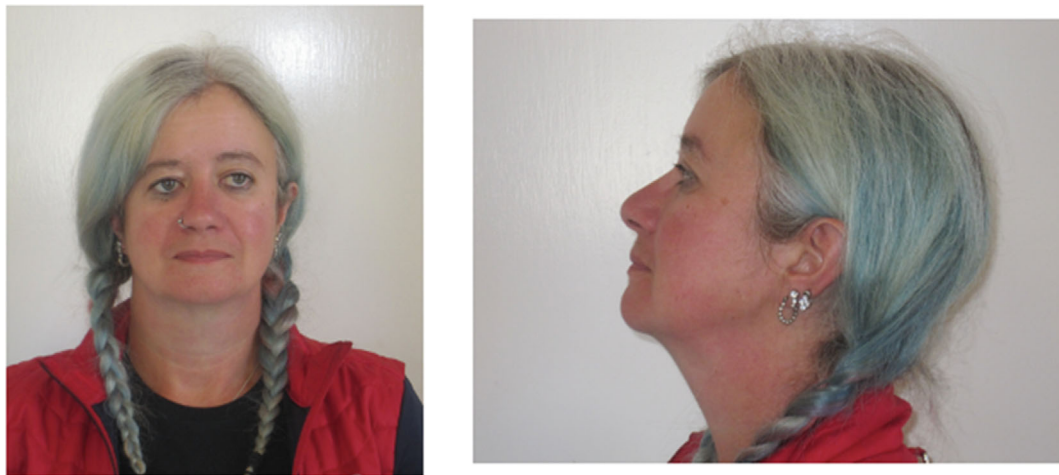

FIGURE 4 Patient 7 age 46 years demonstrating facial asymmetry, mild ptosis, and hypertrichosis

et al., 2016). However, there is clear heterogeneity of extra-cardiac connective tissue involvement. Joint hypermobility is a commonly described feature, however, does not necessarily equate to connective tissue disease. Other previously described features signifying possible connective tissue disease include high-arched palate and dislocatable joints (Caulfield et al., 2018). In our patient cohort, 7/14 (50%) had evidence of joint hypermobility, and 3/14 (21%) had high-arched palate, but all in the

absence of underlying diagnosed connective tissue disorder. One patient had 'wandering spleen' (absence of splenic ligament) which has not been previously described in the literature, and may or may not be attributed to *TAB2*. One patient had an acute unprecipitated subarachnoid hemorrhage, the occurrence of which can be occasionally associated with underlying connective tissue disorder, however there was no known underlying precipitating cause in this patient.

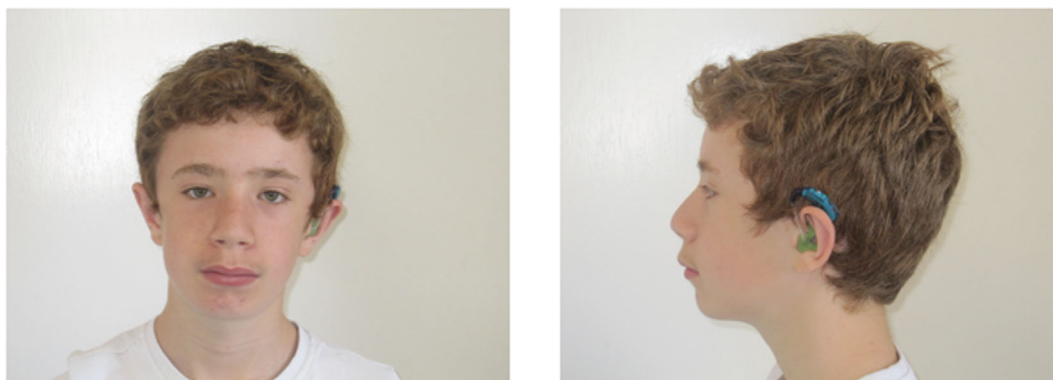

FIGURE 5 Patient 8 aged 12 years 6 months demonstrating facial dysmorphism including epicanthic folds and mild ptosis

Previously unreported feeding problems during infancy were seen in 5/14 (36%) of our patient cohort, mainly co-existing with hypotonia. Our cohort had higher incidence of hypotonia than published cumulative cohorts (Tables 2, 3). Musculoskeletal problems and soft, hyperextensible skin have been previously reported in *TAB2*, and described as partially comparable to an Ehlers-Danlos Syndrome phenotype (Ritelli et al., 2018). The skin of one patient had a soft and doughy texture, similar to what has been previously described in *TAB2*, but there were no other skin abnormalities identified. The range of skeletal abnormalities presented in our cohort were varied; delayed bone age, abnormalities of digits and clinodactyly, cubitus valgus, congenital dislocation of the hip, Perthe's disease, lumbar hyperlordosis and abnormal C3 and C4 vertebrae. One patient had pes planus explained by osseous and fibrocartilaginous coalition of the joints of the foot. In our cohort, 13/14 (92%) had failure to thrive (FTT) at some point during infancy, or had subsequent short stature, which is a higher incidence than previous reports.

Tooth abnormalities were also a common finding in our cohort (50%), commonly with dental overcrowding, and one patient with missing lower lateral incisors, and one patient with deciduous molars. This has not been previously described as a common feature, although fibromuscular dysplasia has also been reported in *TAB2* gain-of-function variants, which causes progressive skeletal dysplasia of long bones and cranium (Wade et al., 2016), (Wade et al., 2017). Cranial abnormalities identified in our cohort were two individuals with frontal bossing.

In our patient cohort, 6/14 (43%) showed developmental delay, ranging from isolated motor delay to global developmental delay. Although intellectual disability has been a previously underreported finding in *TAB2*, our findings are similar and in keeping with a recent cohort study that found that 53% displayed developmental delay; the precursor of intellectual disability (Hanson et al., 2021). All of our patients with global developmental delay went on to have a diagnosis of intellectual disability. Unlike previous cohorts, our cohort also described some evidence of social communication difficulties, educational difficulties, and behavioral problems in association with global delay/ intellectual disability. One patient showed self-injurious behaviors. Sleep difficulties are another feature not previously reported in

the literature. In our cohort, there was one patient with poor sleep patterns, and one patient with a diagnosis of sleep apnoea.

Dysmorphic features seen within our cohort that have not been previously described in the literature include bifid uvula and hypertrichosis. Dysmorphic features were described in 13/14 (92%) of our cohort (Table 2). Features varied between each individual, but common features included dental crowding, frontal bossing, low-set ears, high-arched palate, hypertelorism, and downslanting palpebral fissures. A variety of facial dysmorphisms have been previously described with common features including frontal bossing, short/ narrow palpebral fissures and retrognathia (Table 3).

Hearing and visual loss have been previously reported with degrees of varying incidence. Two individuals in our cohort had hearing loss. Two patients in our cohort had strabismus, which has been previously reported in one patient in the literature (Hori et al., 2021). An additional visual problem was seen in one individual in our cohort of rod-cone dystrophy causing night blindness. Causation of visual problems as part of *TAB2* phenotype is currently unclear with current limited further clinical detail from other cohorts.

Additional newly described anatomical features seen in our cohort included two patients with cryptorchidism and one with glandular hypospadias. Vascular anatomical variations also seen in our cohort included one patient with coeliac artery stenosis and one patient with congenital stenosis of femoral arterial tree, detected on imaging for post-surgical thrombus.

4 | CONCLUSION

Here we describe the details of 14 individuals with nine novel pathogenic *TAB2* variants, in comparison to the existing literature, to add to the descriptive and quantifiable data for both cardiac and extra-cardiac manifestations in this emerging distinct syndrome.

This cohort shared similar phenotype with what is already known about *TAB2*, including high incidence of cardiac involvement, short stature, hypermobility, and intellectual disability. Facial features were variable, with common facial dysmorphism including dental crowding, frontal bossing, and hypertelorism and downslanting palpebral

fissures. Other features included musculoskeletal problems and poor feeding during infancy.

We also describe some novel features not previously reported including 'wandering spleen' (absence of splenic ligament), cryptorchidism, and glandular hypospadias. Vascular anatomical variations detected were coeliac artery stenosis and congenital stenosis of the femoral arterial tree. Newly described dysmorphic features include bifid uvula and hypertrichosis. We also describe a high proportion of developmental delay, with associated difficulties including social, behavioral, and emotional elements. Feeding difficulties during infancy were not previously reported and were newly quantified in this cohort. Previously undescribed sleep issues were an issue for two individuals in this cohort; one had poor sleep pattern and one had sleep apnoea.

Our patient information adds to the emerging *TAB2* syndrome. Therefore, consideration of *TAB2* should be given in individuals with structural heart defect, or cardiomyopathy, in the presence of other syndromic features. Further cohort data and case reports will continue to expand the described genotype-phenotype and provide information on additional associated features in order to further understand the expressivity of this condition.

AUTHOR CONTRIBUTIONS

EW wrote the manuscript, IM collated data; all authors contributed to data collection and approved final manuscript; MB as senior author supervised the project and co-ordinated all the data collection.

ACKNOWLEDGMENTS

The DDD study presents independent research commissioned by the Health Innovation Challenge Fund [grant number HICF-1009-003]. This study makes use of DECIPHER (<http://www.deciphergenomics.org>), which is funded by Wellcome. See Nature PMID: 25533962 or www.ddduk.org/access.html for full acknowledgement. We would also like to thank the families for consenting to this publication.

CONFLICT OF INTEREST

None to declare.

DATA AVAILABILITY STATEMENT

Data sharing is not applicable to this article as no new data were created or analyzed in this study.

ORCID

Emily Woods  <https://orcid.org/0000-0003-2349-2688>

Imogen Marson  <https://orcid.org/0000-0001-7441-831X>

Farah Kanani  <https://orcid.org/0000-0003-4388-0290>

George Giannakoulas  <https://orcid.org/0000-0001-7491-6319>

Meena Balasubramanian  <https://orcid.org/0000-0003-1488-3695>

REFERENCES

Ackerman, J. P., Smestad, J. A., Tester, D. J., Qureshi, M. Y., Crabb, B. A., Mendelsohn, N. J., & Ackerman, M. J. (2016). Whole exome sequencing, familial genomic triangulation, and systems biology converge to

identify a novel nonsense mutation in *TAB2*-encoded TGF-beta activated kinase 1 in a child with polyvalvular syndrome. *Congenital Heart Disease*, 11(5), 452–461.

Caulfield, T. R., Richter, J. E., Jr., Brown, E. E., Mohammad, A. N., Judge, D. P., & Atwal, P. S. (2018). Protein molecular modeling techniques investigating novel *TAB2* variant R347X causing cardiomyopathy and congenital heart defects in multigenerational family. *Molecular Genetics & Genomic Medicine*, 6(4), 666–672.

Chen, J., Yuan, H., Xie, K., Wang, X., Tan, L., Zou, Y., Yang, Y., Pan, L., Xiao, J., Chen, G., & Liu, Y. (2020). A novel *TAB2* nonsense mutation (p.S149X) causing autosomal dominant congenital heart defects: A case report of a Chinese family. *BMC Cardiovascular Disorders*, 20(1), 27.

Cheng, A., Dinulos, M. B. P., Neufeld-Kaiser, W., Rosenfeld, J., Kyriakos, M. K., Madan-Khetarpal, S., Risheg, H., Byers, P. H., & Liu, Y. J. (2017). 6q25.1 (*TAB2*) microdeletion syndrome: Congenital heart defects and cardiomyopathy. *American Journal of Medical Genetics Part A*, 173(7), 1848–1857.

Ellard, S., Baple, E.L., Callaway A., Berry, I., Forrester, N., Turnbull, C., Owens, M., Eccles, D.M., Abbs, S., Scott, R., Deans, Z.C., Lester, T., Campbell, J., Newman, W.G (2020). ACGS best practice guidelines for variant classification in rare disease 2020: <https://www.acgs.uk.com/media/11631/uk-practice-guidelines-for-variant-classification-v4-01-2020.pdf>

Engwerda, A., Leenders, E. K. S. M., Frenzt, B., Terhal, P. A., Löhner, K., de Vries, B. B. A., ... Kerstjens-Frederikse, W. S. (2021). *TAB2* deletions and variants cause a highly recognisable syndrome with mitral valve disease, cardiomyopathy, short stature and hypermobility. *European Journal of Human Genetics*, 11, 1669–1676.

Hanson, J., Brezavar, D., Hughes, S., Amudhavalli, S., Fleming, E., Zhou, D., Alaimo, J. T., & Bonnen, P. E. (2021). *TAB2* variants cause cardiovascular heart disease, connective tissue disorder, and developmental delay. *Clinical Genetics*, 101, 214–220. <https://doi.org/10.1111/cge.14085>

Hori, A., Migita, O., Kawaguchi-Kawata, R., Narumi-Kishimoto, Y., Takada, F., & Hata, K. (2021). A novel *TAB2* mutation detected in a putative case of frontometaphyseal dysplasia. *Human Genome Variation*, 8, 40.

Li, L., Chen, Y., Doan, J., Murray, J., Molkentin, J. D., & Liu, Q. (2014). Transforming growth factor β -activated kinase 1 signaling pathway critically regulates myocardial survival and remodeling. *Circulation* 9; 130(24):2162-72, 130, 2162–2172.

Permanyer, E., Laurie, S., Blasco-Lucas, A., Maldonado, G., Amador-Catalan, A., Ferrer-Curriu, G., Fuste, B., Perez, M. L., Gonzalez-Alujas, T., Beltran, S., Comas-Riu, J., Bardaji, A., Evangelista, A., & Galiñanes, M. (2020). A single nucleotide deletion resulting in a frameshift in exon 4 of *TAB2* is associated with a polyvalvular syndrome. *European Journal of Medical Genetics*, 63(4), 103854.

Richards, S., Aziz, N., Bale, S., Bick, D., Das, S., Gastier-Foster, J., Grody, W. W., Hegde, M., Lyon, E., Spector, E., Voelkerding, K., & Rehm, H. L. (2015). ACMG laboratory quality assurance committee. Standards and guidelines for the interpretation of sequence variants: A joint consensus recommendation of the American College of Medical Genetics and Genomics and the Association for Molecular Pathology. *Genetics in Medicine*, 17(5), 405–424.

Ritelli, M., Morlino, S., Giacomuzzi, E., Bernardini, L., Torres, B., Santoro, G., Ravasio, V., Chiarelli, N., D'Angelantonio, D., Novelli, A., Grammatico, P., Colombi, M., & Castori, M. (2018). A recognizable systemic connective tissue disorder with polyvalvular heart dystrophy and dysmorphism associated with *TAB2* mutations. *Clinical Genetics*, 93(1), 126–133.

Swaminathan, G. J., Bragin, E., Chatzimichali, E. A., Corpas, M., Bevan, A. P., Wright, C. F., Carter, N. P., Hurles, M. E., & Firth, H. V. (2012). DECIPHER: web-based, community resource for clinical interpretation of rare variants in developmental disorders. *Human Molecular Genetics*, 21(R1), R37–R44. <https://doi.org/10.1093/hmg/dd3362>

- Takaesu, G., Kishida, S., Hiyama, A., Yamaguchi, K., Shibuya, H., Irie, K., Ninomiya-Tsuji, J., & Matsumoto, K. (2000). TAB2, a novel adaptor protein, mediates activation of TAK1 MAPKKK by linking TAK1 to TRAF6 in the IL-1 signal transduction pathway. *Molecular Cell*, *5*, 649–658.
- Thienpont, B., Zhang, L., Postma, A. V., Breckpot, J., Tranchevent, L. C., van Loo, P., Møllgård, K., Tommerup, N., Bache, I., Tümer, Z., van Engelen, K., Menten, B., Mortier, G., Waggoner, D., Gewillig, M., Moreau, Y., Devriendt, K., & Larsen, L. A. (2010). Haploinsufficiency of TAB2 causes congenital heart defects in humans. *The American Journal of Human Genetics*, *86*(6), 839–849.
- Vasilescu, C., Ojala, T. H., Brillhante, V., Ojanen, S., Hinterding, H. M., Palin, E., Alastalo, T. P., Koskenvuo, J., Hiiippala, A., Jokinen, E., Jahnukainen, T., Lohi, J., Pihkala, J., Tyni, T. A., Carroll, C. J., & Suomalainen, A. (2018). Genetic basis of severe childhood-onset cardiomyopathies. *Journal of the American College of Cardiology*, *72*(19), 2324–2338.
- Wade, E. M., Daniel, P. B., Jenkins, Z. A., McInerney-Leo, A., Leo, P., Morgan, T., Addor, M. C., Adès, L. C., Bertola, D., Bohring, A., Carter, E., Cho, T. J., Duba, H. C., Fletcher, E., Kim, C. A., Krakow, D., Morava, E., Neuhann, T., Superti-Furga, A., Veenstra-Knol, I., ... Robertson, S. P. (2016). Mutations in MAP3K7 that alter the activity of the TAK1 signaling complex causing frontometaphyseal dysplasia. *American Journal of Human Genetics*, *99*, 392–406.
- Wade, E. M., Jenkins, Z. A., Daniel, P. B., Morgan, T., Addor, M. C., Adès, L. C., Bertola, D., Bohring, A., Carter, E., Cho, T. J., de Geus, C. M., Duba, H. C., Fletcher, E., Hadziev, K., Hennekam, R., Kim, C. A., Krakow, D., Morava, E., Neuhann, T., Sillence, D., ... Robertson, S. P. (2017). Autosomal dominant frontometaphyseal dysplasia: Delineation of the clinical phenotype. *American Journal of Medical Genetics. Part A*, *9999*, 1–8.
- Wright, C. F., Fitzgerald, T. W., Jones, W. D., Clayton, S., McRae, J. F., van Kogelenberg, M., King, D. A., Ambridge, K., Barrett, D. M., Bayzatinova, T., Bevan, A. P., Bragin, E., Chatzimichali, E. A., Gribble, S., Jones, P., Krishnappa, N., Mason, L. E., Miller, R., Morley, K. I., Parthiban, V., ... DDD study. (2015). Genetic diagnosis of developmental disorders in the DDD study: A scalable analysis of genome-wide research data. *The Lancet*, *385*(9975), 1305–1314.

How to cite this article: Woods, E., Marson, I., Coci, E., Spiller, M., Kumar, A., Brady, A., Homfray, T., Fisher, R., Turnpenny, P., Rankin, J., Kanani, F., Platzer, K., Ververi, A., Emmanouilidou, E., Bourbonn, N., Giannakoulas, G., & Balasubramanian, M. (2022). Expanding the phenotype of TAB2 variants and literature review. *American Journal of Medical Genetics Part A*, *188A*:3331–3342. <https://doi.org/10.1002/ajmg.a.62949>