

# Subacute left main stem thrombus in COVID-19: a case report

Zaki Akhtar <sup>1,2\*</sup>, Lisa W.M. Leung<sup>2</sup>, Mark M. Gallagher <sup>1,2</sup>, and Sumeet Sharma <sup>1</sup>

<sup>1</sup>Department of Cardiology, Ashford and St Peter's Hospitals NHS trust, Guildford road, Surrey, KT16 0PZ, UK; and <sup>2</sup>Department of Cardiology, St George's University Hospital, Blackshaw road, London, SW17 0RE, UK

Received 22 February 2021; first decision 22 March 2021; accepted 18 May 2021

A 47-year-old south-east Asian gentleman treated for COVID-19 (Figure 1) was re-admitted 2 days after discharge with an ST-elevation myocardial infarction (STEMI) (Figure 2). Emergency percutaneous coronary intervention revealed thrombus in the left main stem (LMS) extending down the left anterior descending, circumflex, and intermediate coronary arteries, compromising flow; the right coronary artery was unobstructed (Video 1). Aspiration thrombectomy was performed: using a 6-Fr Extra Back-Up 3.5 guide catheter (Medtronic, USA) and a ChoICE PT extra floppy guidewire (Boston

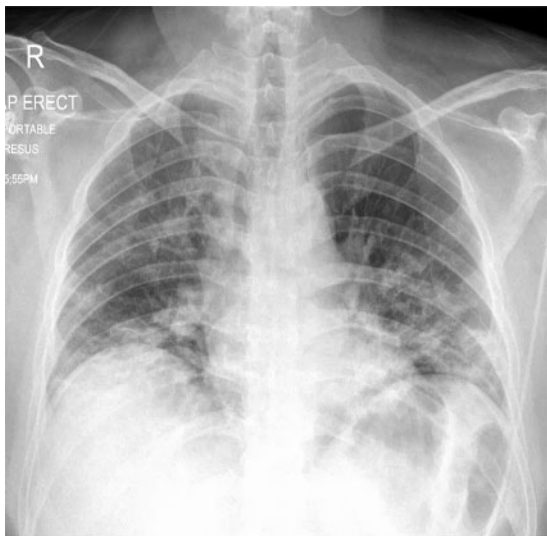Scientific, USA), an Export aspiration catheter (Medtronic, USA) was railroaded to aspirate thrombus from the LMS, restoring coronary flow. In addition to the dual anti-platelet (DAPT) regime, a 12-hour tirofiban infusion was completed followed by a heparin infusion for 24-hours and then addition of a direct oral anticoagulant (DOAC) to the DAPT. A subsequent multi-disciplinary team discussion with cardiac surgeons advised a repeat assessment of the coronary vessels. This was performed 2 weeks later with intravascular ultrasound (Video 2) and revealed a significant reduction in thrombus burden with normal flow in all affected coronary arteries. The echocardiogram on admission demonstrated left ventricle (LV) function impairment and akinesia of the ventricular apex (Video 3). He was discharged on triple therapy (DAPT and DOAC) with planned Aspirin discontinuation after 2 weeks. He remains well to date with some LV function improvement at 3-month follow-up.

Thromboembolism is a significant manifestation of the COVID-19 disease and associated with an increased risk of mortality.<sup>1</sup> Arterial thrombosis causing major vascular events have been reported with increasing prevalence.<sup>2</sup> LMS thrombus-mediated STEMI is life-threatening but rare in COVID-19. There is delayed risk of thrombosis in SARS-Cov-2 infection<sup>3</sup> and our case highlights this risk exists in the arterial system which extends beyond the period of hospitalization.

## Conclusion

COVID-19 illness is a prothrombotic state increasing the risk of a life-threatening myocardial infarction.

**Consent:** The authors confirm that written consent for submission and publication of this case report including images and associated text has been obtained from the patient in line with COPE guidance.



**Figure 1:** Chest radiograph demonstrating bilateral consolidation consistent with COVID-19.

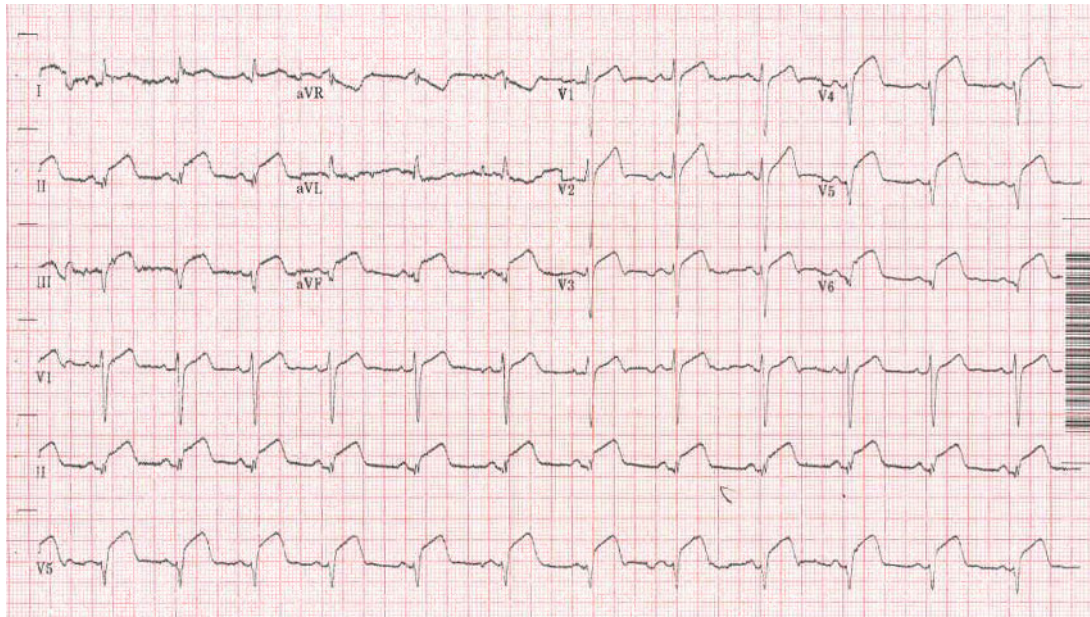
\* Corresponding author. Tel: +44 1932 722282, Email: zakiakhtar@nhs.net

Handling Editor: Aref Bin Abdulhak

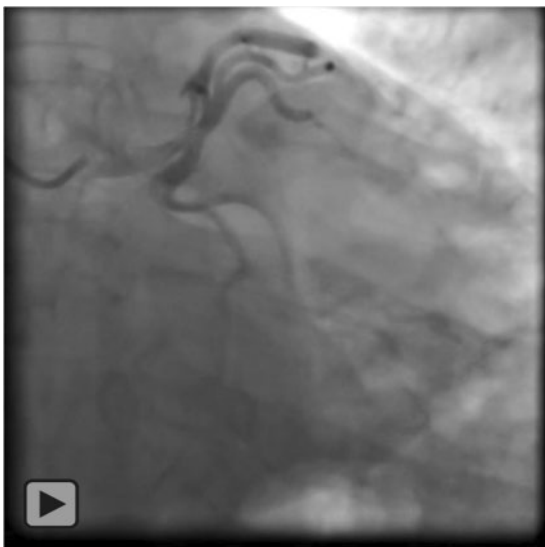
Peer-reviewers: Carlos Cortes

© The Author(s) 2021. Published by Oxford University Press on behalf of the European Society of Cardiology.

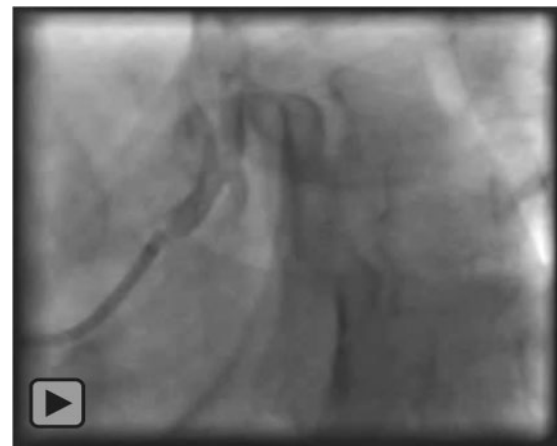This is an Open Access article distributed under the terms of the Creative Commons Attribution Non-Commercial License (<http://creativecommons.org/licenses/by-nc/4.0/>), which permits non-commercial re-use, distribution, and reproduction in any medium, provided the original work is properly cited. For commercial re-use, please contact [journals.permissions@oup.com](mailto:journals.permissions@oup.com)



**Figure 2:** Electrocardiogram on admission demonstrating ST-elevation consistent with the ST-elevation myocardial infarction.



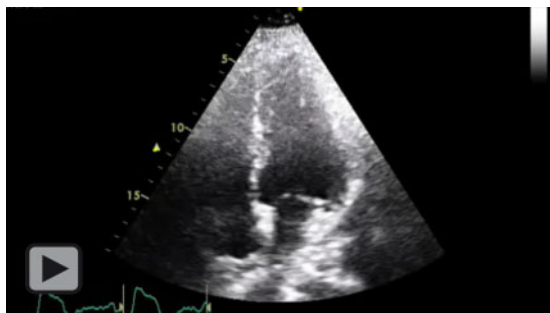
**Video 1:** Primary percutaneous coronary intervention treating left main stem thrombus with thrombectomy. ST-elevation myocardial infarction with acute left main stem thrombus (red arrow) treated with coronary thrombectomy; some residual thrombus remains at the end of the procedure (red circle).



**Video 2:** Repeat coronary angiogram following thrombectomy and pharmacotherapy. There is significant resolution of the thrombus burden with normal coronary flow. Intravascular ultrasound: pull-back from the proximal left anterior descending; there is residual thrombus remaining (green arrow) in the left main stem which is 6 mm in diameter. The minimum luminal cross-sectional area was 21 mm<sup>2</sup> with minimal clot burden in the distal portion of the vessel.

**Conflict of interest:** M.M.G. has received research funding from Attune Medical and has acted as a consultant and a paid speaker for Boston Scientific and Cook Medical

S.S. has received educational grants and has acted as a paid speaker for Boston Scientific, BAYER, Abbott Medical, Pfizer, and Bristol-Myers Squibb. All other authors declared no conflict of interest.



**Video 3:** Echocardiography following percutaneous coronary intervention. (A) Echocardiogram following primary percutaneous coronary intervention demonstrating left ventricle impairment with an estimated left ventricle ejection fraction of 30–35%; the apical septum and true apex appear hypokinetic and akinetic. (B) At 3-month follow-up study, there is some recovery of left ventricle function with an estimated left ventricle ejection fraction of 45–50%; the true apex is akinetic.

**Funding:** None declared.

## References

1. Abou-Ismaïl MY, Diamond A, Kapoor S, Arafah Y, Nayak L. The hypercoagulable state in COVID-19: incidence, pathophysiology, and management. *Thromb Res* 2020;**194**:101–115.
2. Gonzalez Cañas E, Gimenez Gaibar A, Rodriguez Lorenzo L, Castro Rios JG, Martinez Toiran A, Bella Cueto MR et al. Acute peripheral arterial thrombosis in COVID-19. Role of endothelial inflammation. *Br J Surg* 2020;**107**:e444–e445.
3. Kanso M, Cardi T, Marzak H, Schatz A, Faucher L, Grunebaum L et al. Delayed pulmonary embolism after COVID-19 pneumonia: a case report. *Eur Heart J Case Rep* 2020;**4**:1–4.