

# Temporal Variant Frontotemporal Dementia Is Associated with Globular Glial Tauopathy

Camilla N. Clark, MRCP,\* Tammaryn Lashley, PhD,† Colin J. Mahoney, BSc,\*  
Jason D. Warren, PhD,\* Tamas Revesz, MD, FRCPath,† and Jonathan D. Rohrer, PhD\*

**Abstract:** Frontotemporal dementia (FTD) is a clinically and pathologically heterogeneous neurodegenerative disorder associated with atrophy of the frontal and temporal lobes. Most patients with focal temporal lobe atrophy present with either the semantic dementia subtype of FTD or the behavioral variant subtype. For patients with temporal variant FTD, the most common cause found on post-mortem examination has been a TDP-43 (transactive response DNA-binding protein 43 kDa) proteinopathy, but tauopathies have also been described, including Pick's disease and mutations in the microtubule-associated protein tau (*MAPT*) gene. We report the clinical and imaging features of 2 patients with temporal variant FTD associated with a rare frontotemporal lobar degeneration pathology known as globular glial tauopathy. The pathologic diagnosis of globular glial tauopathy should be considered in patients with temporal variant FTD, particularly those who have atypical semantic dementia or an atypical parkinsonian syndrome in association with the right temporal variant.

**Key Words:** tauopathy, frontotemporal dementia, parkinsonism  
(*Cogn Behav Neurol* 2015;28:92–97)

Received for publication July 22, 2014; accepted December 31, 2014.  
From the \*Dementia Research Centre; and †Queen Square Brain Bank for Neurological Disorders, University College London, Institute of Neurology, London, United Kingdom.

C.N.C. and T.L. contributed equally to the work.

Funded by the Wellcome Trust, United Kingdom Medical Research Council, and National Institute for Health Research (NIHR) Queen Square Dementia Biomedical Research Unit. Support for the Dementia Research Centre, Department of Neurodegenerative Disease, University College London Institute of Neurology, comes from Alzheimer's Research UK, Brain Research Trust, and The Wolfson Foundation. The Queen Square Brain Bank for Neurological Disorders is supported by the Reta Lila Weston Trust for Medical Research. J.D.R. is supported by an NIHR Rare Disease Initiative Postdoctoral Fellowship. J.D.W. is supported by a Wellcome Trust Senior Clinical Fellowship (Grant No 091673/Z/10/Z).

The authors declare no conflicts of interest.

Reprints: Jonathan D. Rohrer, PhD, Dementia Research Centre, Institute of Neurology, Queen Square, London WC1N 3BG, United Kingdom (e-mail: j.rohrer@ucl.ac.uk).

Supplemental Digital Content is available for this article. Direct URL citations appear in the printed text and are provided in the HTML and PDF versions of this article on the journal's Website, www.cogbehavneurol.com.

Copyright © 2015 Wolters Kluwer Health, Inc. All rights reserved. This is an open-access article distributed under the terms of the Creative Commons Attribution-NonCommercial License 4.0 International (CCBY-NC 4.0), where it is permissible to download, share, remix, transform, and build up the work provided it is properly cited. The work cannot be used commercially.

**bvFTD** = behavioral variant frontotemporal dementia. **FTD** = frontotemporal dementia. **FTLD** = frontotemporal lobar degeneration. **GGT** = globular glial tauopathy. **4R** = 4-repeat. **TDP-43** = transactive response DNA-binding protein 43 kDa.

Frontotemporal dementia (FTD) is a common early-onset dementia, usually presenting with behavioral or language impairment and associated with atrophy of the frontal and/or temporal lobes (Seelaar et al, 2011). Most patients with focal temporal lobe atrophy present clinically with either the semantic dementia subtype of FTD or the behavioral variant (bvFTD) subtype. When temporal atrophy is asymmetric and left side-predominant, the clinical diagnosis is usually semantic dementia, but when the atrophy is predominantly right-sided, the initial symptoms are usually behavioral (Seeley et al, 2005).

In addition to variation in clinical presentation, FTD is heterogeneous pathologically. In temporal variant FTD, a TDP-43 (transactive response DNA-binding protein 43 kDa) proteinopathy has been the most common cause found at post-mortem examination, but tauopathies have also been described, including Pick's disease and mutations in the microtubule-associated protein tau gene (*MAPT*) (Josephs et al, 2009).

The term *globular glial tauopathy* (GGT) was recently coined (Ahmed et al, 2011, 2013) to describe a group of neurodegenerative disorders characterized by globular glial and neuronal tau-immunoreactive cytoplasmic inclusions. In all GGT subtypes, significant degeneration of the white matter is also a characteristic feature (Ahmed et al, 2011, 2013). At present, GGTs comprise 3 subgroups, named Types I, II, and III.

Here we report our evaluation of the clinical, imaging, and pathologic features of 2 patients with temporal variant FTD associated with frontotemporal lobar degeneration (FTLD)-tau pathology corresponding to GGT Type I.

## CASE REPORTS

### Patient 1

A 77-year-old woman attended our clinic with a 3-year history of change in behavior (Table 1). She had become apathetic and socially withdrawn, with abnormal eating behavior (often cramming food into her mouth), disinhibition (once removing all her clothes in public), and hypersexuality.

**TABLE 1.** Comparison of the Patients' Demographic, Clinical, Behavioral, Cognitive, and Imaging Features

	Patient 1	Patient 2
<b>Demographics</b>		
Sex	Female	Female
Age at onset (years)	74	75
Age at death (years)	77	83
<b>Clinical features</b>		
Main syndrome	Behavioral variant frontotemporal dementia	Atypical semantic dementia
Extrapyramidal features	+	–
Pyramidal features	–	–
<b>Behavioral features</b>		
Disinhibition	+	+
Apathy	+	+
Abnormal eating behavior	+	–
<b>Cognitive features</b>		
Executive dysfunction	+	+
Language impairment	–	+
Episodic memory impairment	+	+
Parietal lobe dysfunction	–	+
<b>Imaging features</b>		
Symmetry of atrophy	Right > Left	Left > Right

One year before we saw her, her family noted that her thinking had become slower and her memory impaired. Six months before we saw her, she had started walking more slowly than before, with stiffness and difficulty using her left arm and leg. Over the few months before we saw her, she started to fall more often than before, mostly backward. She had no family history of note.

When we evaluated the patient, she had a Mini-Mental State Examination (Folstein et al, 1975) score of 23/30, losing points on orientation to place and time, sentence repetition, copying, and sentence writing. Further psychometric testing revealed marked executive dysfunction, profound slowing of information processing speed, and impaired recognition memory for faces; however, she had relatively intact memory for words.

She was hypomimic and hypophonic. She had difficulty initiating saccades and a slowing of vertical saccadic eye movements, particularly in downgaze. There was asymmetric bradykinesia and rigidity in the limbs, worse on the left side, without a tremor. She had myoclonus and apraxia in the upper limbs, worse on the left. She had a stooped posture with axial rigidity, and a slow, shuffling gait.

The clinical diagnosis was bvFTD with an atypical parkinsonian disorder. Magnetic resonance imaging of the patient's brain showed focal right temporal lobe atrophy, particularly anteriorly (Figure 1). She had a trial of levodopa, with no improvement. Her condition deteriorated and she died 6 months later.

## Patient 2

A 78-year-old woman attended our clinic with a 3-year history of word-finding difficulties (Table 1). She had

been noted to be mildly disinhibited and inappropriately jocular. Her mother had a late-onset dementia, but there was no other notable family history.

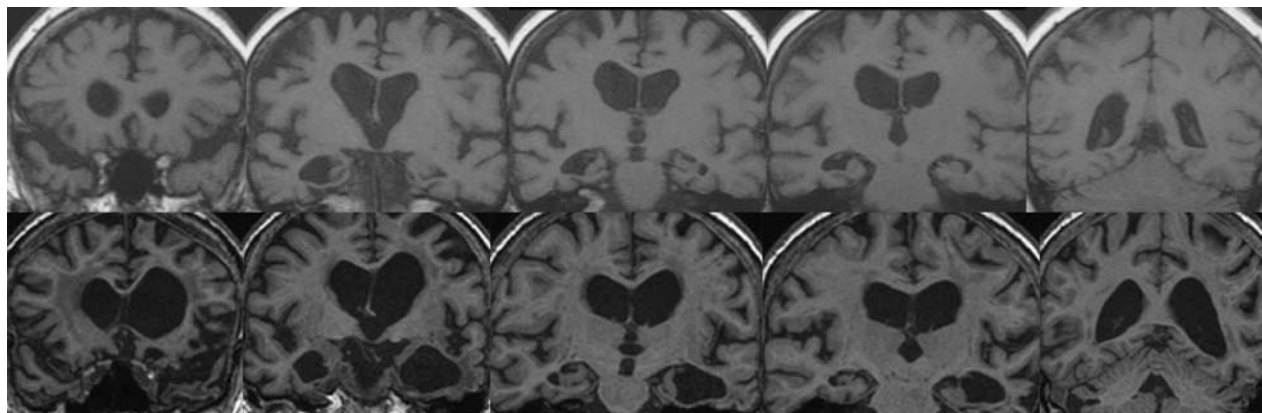
When we evaluated the patient, she had a Mini-Mental State Examination score of 21/30, losing points on orientation, recall, sentence writing, and copying. Further psychometric testing revealed a profound anomia, dyscalculia, impairment on the vocabulary subtest of the Wechsler Adult Intelligence Scale<sup>®</sup>–Third Edition (Wechsler, 1997), executive dysfunction, and impaired recognition memory for both faces and words. She had evidence of limb apraxia, but an otherwise normal neurologic examination.

A clinical diagnosis of semantic dementia was made, although it was felt to be atypical because of her dyscalculia and limb apraxia. Magnetic resonance imaging of her brain (Figure 1) showed temporal lobe atrophy, particularly anteriorly, and worse on the left side than the right. She also had white matter changes that were thought to be secondary to associated small-vessel disease.

Over the next year she became almost mute, able to say only “yes” and “no,” and she laughed in response to most questions. She continued to decline over the next 2 years, becoming abulic and incontinent of both bladder and bowel. When we last evaluated her, 3 years after our initial assessment, she was still able to walk, although her gait was apraxic. She was not seen again in the clinic. She died 2 years after our last assessment.

## PATHOLOGY

With appropriate consents, the 2 patients' brains were donated to the Queen Square Brain Bank for Neurological Disorders, Department of Molecular Neuroscience,



**FIGURE 1.** Coronal T1 magnetic resonance scans in our patients, performed 3 years after symptom onset. In Patient 1 (upper panel), there is focal right anteromedial temporal lobe atrophy. In Patient 2 (lower panel), there is anteromedial temporal lobe atrophy, left more severe than right.

University College London. The protocols used by the Brain Bank have been approved by a London Multicentre Ethics Committee, and tissue is stored under a license from the Human Tissue Authority.

## Gross Pathology

### Patient 1

We examined Patient 1's right half brain, which weighed 609 g (Table 2). We found severe dilatation of the right lateral ventricle. There was moderate cortical atrophy, which involved the entire frontal lobe (including the motor strip and gyri of its medial surface) and the temporal lobe. The body of the caudate nucleus was mildly reduced in bulk, and there was severe atrophy of the amygdala and hippocampus. The substantia nigra was pale.

### Patient 2

Patient 2's left half brain, weighing 506 g, showed severe frontotemporal atrophy with focally narrow gyri (Table 2). The cortical atrophy was severe in the prefrontal region and the temporal lobe, and also involved the fusiform and parahippocampal gyri. The deep white matter of the anterior frontal lobe and anterior temporal lobe was severely reduced in bulk and had a granular surface. There was also a reduction in bulk of the caudate nucleus, severe atrophy of the amygdala and hippocampus, and pallor of the substantia nigra and locus coeruleus.

## Microscopic Findings

Microscopic assessment revealed a "primary" 4-repeat (4R) tauopathy in both patients, with morphologic appearances in keeping with GGT Type I.

### Patient 1

Our findings in Patient 1 are described in Table 2 and illustrated in Supplemental Digital Content 1 (<http://links.lww.com/CBN/A60>) Panels D–G, I, and J.

Patient 1 had marked anterior frontal and temporal cortical nerve cell loss, accompanied by severe 4R-tau de-

posits in both cerebral cortex and subcortical and deep white matter. Also among the most severely affected regions were the temporal pole and medial temporal lobe structures, including the hippocampus, amygdala, and parahippocampal and fusiform gyri. Similar pathology was present in the basal ganglia, including the subthalamic nucleus and globus pallidus, and in brain stem structures.

The tau-positive neuronal cytoplasmic inclusions, seen in affected cerebral cortices, basal ganglia, and brain stem nuclei, were represented either by diffuse cytoplasmic immunoreactivity, often with appearances of pretangles, or by coarse globular 4R-tau-positive cytoplasmic deposits (globular neuronal inclusions), occasionally mimicking the morphologic appearances of Pick bodies.

There was astrocytic tau pathology in affected gray matter structures, with the tau-positive astrocytes showing a granular staining pattern or containing small globular deposits (Supplemental Digital Content 1, <http://links.lww.com/CBN/A60>, Panel G). These appearances were strikingly different from those seen in tufted astrocytes, which possess delicate filamentous processes. Importantly, the astrocytic inclusions remained unstained on Gallyas silver preparations.

Tau-positive neuropil threads and oligodendroglial cytoplasmic inclusions with appearances of either typical globular oligodendroglial inclusions or coiled bodies were numerous in the subcortical and hemispheric deep white matter, including the centrum semiovale; the internal, external, and extreme capsules; and the anterior commissure (Supplemental Digital Content 1, <http://links.lww.com/CBN/A60>, Panels D, F, I, and J), as well as the frontopontine and temporopontine tracts in the cerebral peduncle.

The CA1 hippocampal subregion and subiculum showed severe loss of neurons, accompanied by astrogliosis (hippocampal sclerosis), with remaining neurons containing tau-positive neuronal cytoplasmic inclusions. The locus coeruleus showed mild depletion of neurons, and several of the remaining neurons contained tau-positive neuronal cytoplasmic inclusions, including globular neuronal inclusions. The tegmentum of the medulla contained neurofibrillary tangles and coarse neuronal tau-positive deposits.

TABLE 2. Summary of the Pathologic Findings for the 2 Patients

Anatomic Region	White Matter Pallor		Neuron Loss		Diffuse Neuronal Cytoplasmic Tau Immunoreactivity		Globular Neuronal Inclusions		Neurofibrillary Tangles		Globular and Granular Astrocytic Inclusions		Globular Oligodendroglial Inclusions		Coiled Bodies		Amyloid $\beta$ Plaques	
	1	2	1	2	1	2	1	2	1	2	1	2	1	2	1	2	1	2
Frontal	GM WM	NA ++	++ NA	++ NA	± NA	0 NA	++ NA	++ NA	0 NA	0 NA	++ 0	++ 0	+	+++	+	+	±	0
Temporal	GM WM	NA +++	+	+++	+	0	++ NA	++ NA	0 NA	0 NA	++ 0	++ 0	+	+++	+	+	+	0
Parietal	GM WM	NA 0	0 NA	±	NA	0 NA	0 NA	0 NA	0 NA	0 NA	++ 0	++ 0	±	+	+	+	+	0
Occipital	GM WM	NA 0	0 NA	0 NA	0 NA	0 NA	0 NA	0 NA	0 NA	0 NA	0 0	0 0	0	0	0	0	nav	nav
CA1		NA	+++	+++	+	0	++	+	+	+	+	+	+	+	+	+	0	0
Subiculum		NA	+++	+++	0	0	+	+	+	+	+	++	++	0	0	0	0	0
Entorhinal	GM WM	NA ±	++ NA	++ NA	+	0	+	++	0	0	++ 0	++ 0	+	+++	+	+	+	0
Amygdala		NA	+++	+++	++	0	+	+	0	0	±	+	+	+	+	+	0	0
Caudate		NA	±	++	+	0	+	++	0	0	±	±	+	+	+	+	0	0
Putamen		NA	0	±	+	0	+	+	0	0	+	±	+	+	+	+	0	0
Globus pallidus		NA	0	±	+	0	+	+	0	0	0	0	+	+	+	+	0	0
Subthalamic nucleus		NA	0	0	0	±	±	+	+	0	0	0	+	+	±	0	nav	nav
Substantia nigra		NA	++	+	±	0	++	+	±	0	0	0	+	+	+	0	nav	nav
Locus coeruleus		NA	±	+	±	±	++	+	+	0	0	0	0	0	0	0	nav	0
Inferior olivary nucleus		nav	0	nav	nav	±	nav	±	nav	0	0	0	0	0	nav	0	nav	0
Dentate nucleus		NA	0	0	+	+	+	±	+	0	0	0	0	0	0	0	nav	0

GM = gray matter. WM = subcortical white matter. NA = not applicable. nav = not available. ± = occasional/very mild. + = sparse/mild. ++ = moderate/moderately severe. +++ = severe.

## Patient 2

Our findings in Patient 2 are described in Table 2 and illustrated in Supplemental Digital Content 1 (<http://links.lww.com/CBN/A60>) Panels A–C and H.

Patient 2's frontal and temporal lobes showed severe disruption of the normal cortical architecture, with spongiosis of cortical neuropil affecting all cortical laminae in the most affected areas. The cortical involvement was distributed in a pattern that is often seen in cases of FTLT, in that the posterior part of the superior temporal gyrus was better preserved, while all of the temporal gyri were severely affected in the anterior temporal lobe. There was also marked pallor of the white matter underlying affected cerebral cortices in the temporal and prefrontal regions, accompanied by astrogliosis.

Like Patient 1, Patient 2 had 4R-tau-positive neuronal cytoplasmic inclusions, including globular neuronal inclusions and pretangle-type inclusions, as well as glial (both oligodendroglial and astrocytic) inclusions (Supplemental Digital Content 1, <http://links.lww.com/CBN/A60>, Panels B, C, and H). The oligodendroglial inclusions were mostly of the globular type and were particularly numerous in the white matter areas showing pallor (Panel B). The tau-positive astrocytic inclusions, seen in affected gray matter structures, showed either a globular or a finely punctate staining pattern (Panel H), and were negative for Gallyas silver staining. Fine tau-positive neuropil threads and small dots were also seen in the gray matter structures.

The tau pathology involving the cerebral cortex was less severe than that in the underlying white matter (Panel C). The CA1 hippocampal subregion and subiculum showed severe neuronal depletion, accompanied by astrogliosis (Panel A). Tau-positive neurons were seen in the granule cells of the dentate fascia, CA1 hippocampal subregion, subiculum, and parahippocampus.

Involvement of the white matter by globular oligodendroglial inclusions was severe throughout the medial temporal lobe structures. Neuronal cytoplasmic inclusions were seen in the striatum, with involvement of the pencil fibers by tau-positive globular oligodendroglial inclusions. The subthalamic nucleus showed no significant cell loss, with minimal loss in the globus pallidus. Tau-positive neuronal cytoplasmic inclusions were seen in both structures, and the globus pallidus also had globular oligodendroglial inclusions. There was modest neuronal loss in the substantia nigra, with neuropil threads, neuronal cytoplasmic inclusions, and globular oligodendroglial inclusions seen here as well as the midbrain and pontine tegmentum. The locus coeruleus showed considerable nerve cell loss.

There was no significant loss of neurons in the inferior olivary nucleus, which contained modest numbers of tau-positive neuropil threads and occasional pretangle-type neuronal cytoplasmic inclusions.

In both patients, the cerebellar cortex showed only very mild loss of Purkinje cells, and the neuronal population of the dentate nucleus was well preserved. Both patients had sparse globular oligodendroglial inclusions in the cerebellar

white matter and occasional pretangle-type neuronal cytoplasmic inclusions and globular neuronal inclusions in the dentate nucleus. Patient 1 had occasional ballooned neurons in prefrontal and limbic areas.

Neither patient had astrocytic plaques or argyrophilic grains. Patient 1 showed additional amyloid  $\beta$ -positive pathology in the temporal and parietal cortices and the entorhinal cortex, corresponding to Thal phase 2. Patient 2 showed a moderate degree of cerebral amyloid angiopathy in the frontal region.

Neither patient had evidence of TDP-43 pathology in any brain area.

## DISCUSSION

Both of our patients had clinical and imaging features suggestive of asymmetric focal temporal lobe involvement. Furthermore, at post-mortem, both showed morphologic features of FTLT, with microscopic evidence of GGT Type I. On the basis of the morphologic findings, including abundant globular oligodendroglial and astrocytic inclusions, the pathology in our patients could be differentiated unequivocally from other forms of FTLT-tau such as Pick's disease, corticobasal degeneration, and progressive supranuclear palsy.

As noted in the introduction, the term GGT was recently coined by Ahmed et al (2011, 2013) for a group of 4R-tauopathies, which, among other pathologic changes, are characterized by globular glial (both oligodendroglial and astrocytic) cytoplasmic tau inclusions. At present, 3 pathologic subgroups are recognized. The Type I subgroup is represented by cases that were previously reported as "sporadic multiple system tauopathy with dementia" and "white matter tauopathy with globular glial inclusions" (Ahmed et al, 2011; Bigio et al, 2001; Kovacs et al, 2008), and are characterized by a frontotemporal predominance of globular oligodendroglial inclusions. The 2 patients reported here met the diagnostic criteria for Type I GGT. Type II cases, in which the motor cortex and corticospinal tract are severely affected, were previously reported as "atypical progressive supranuclear palsy with corticospinal tract degeneration" (Josephs et al, 2006). In Type III cases, in addition to severe frontotemporal lobar involvement, the motor cortex and corticospinal tract also show severe tau pathology, including globular oligodendroglial inclusions (Fu et al, 2010).

In patients with a pathologic diagnosis of GGT, the clinical diagnoses have been bvFTD, atypical parkinsonian disorders (including progressive supranuclear palsy and corticobasal syndrome), and motor neuron disease (including the upper motor neuron variant primary lateral sclerosis). A number of patients have had features of > 1 of these syndromes. Our Patient 1 presented initially with bvFTD, and then developed atypical parkinsonian features without any clinical evidence of motor neuron disease. Our Patient 2 had a progressive language disorder within the FTD spectrum.

Focal right temporal lobe atrophy has been described in a number of patients with FTD, usually presenting with either bvFTD or semantic dementia (Chan et al, 2009; Josephs et al, 2009). In 2009, Josephs et al found that these 2 clinical presentations segregated with the underlying pathology in that patients diagnosed with bvFTD had underlying tau pathology (either Pick's disease or mutations in the tau gene), while patients with semantic dementia had underlying TDP-43 pathology, corresponding to FTLD-TDP Type C in the "harmonized" classification of FTLDs (Mackenzie et al, 2011). The patients with bvFTD (and FTLD-tau) were more likely to develop parkinsonism and abnormal eating behavior, but less likely to develop prosopagnosia or topographagnosia, consistent with our Patient 1.

In 2012, Coon et al described a further subtype of right temporal variant FTD in patients who had associated motor neuron disease. However, all of these patients had FTLD-TDP Type B pathology (Mackenzie et al, 2011). Focal left temporal lobe atrophy is usually associated with semantic dementia and underlying TDP-43 Type C pathology (Rohrer et al, 2010), but there have been reports of patients with focal left temporal lobe atrophy having tauopathies such as Pick's disease, particularly when the patients have atypical features, eg, neuropsychological abnormalities suggesting parietal lobe involvement (Rohrer et al, 2011).

In summary, the pathologic diagnosis of GGT should be considered in patients with temporal variant FTD, particularly in those with semantic dementia who have atypical features and in those with the right temporal variant who have an atypical parkinsonian syndrome.

## REFERENCES

- Ahmed Z, Bigio EH, Budka H, et al. 2013. Globular glial tauopathies (GGT): consensus recommendations. *Acta Neuropathol.* 126:537–544.
- Ahmed Z, Doherty KM, Silveira-Moriyama L, et al. 2011. Globular glial tauopathies (GGT) presenting with motor neuron disease or frontotemporal dementia: an emerging group of 4-repeat tauopathies. *Acta Neuropathol.* 122:415–428.
- Bigio EH, Lipton AM, Yen SH, et al. 2001. Frontal lobe dementia with novel tauopathy: sporadic multiple system tauopathy with dementia. *J Neuropathol Exp Neurol.* 60:328–341.
- Chan D, Anderson V, Pijnenburg Y, et al. 2009. The clinical profile of right temporal lobe atrophy. *Brain.* 132(pt 5):1287–1298.
- Coon EA, Whitwell JL, Parisi JE, et al. 2012. Right temporal variant frontotemporal dementia with motor neuron disease. *J Clin Neurosci.* 19:85–91.
- Folstein MF, Folstein SE, McHugh PR. 1975. "Mini-mental state": a practical method for grading the cognitive state of patients for the clinician. *J Psychiatr Res.* 12:189–198.
- Fu YJ, Nishihira Y, Kuroda S, et al. 2010. Sporadic four-repeat tauopathy with frontotemporal lobar degeneration, Parkinsonism, and motor neuron disease: a distinct clinicopathological and biochemical disease entity. *Acta Neuropathol.* 120:21–32.
- Josephs KA, Katsuse O, Beccano-Kelly DA, et al. 2006. Atypical progressive supranuclear palsy with corticospinal tract degeneration. *J Neuropathol Exp Neurol.* 65:396–405.
- Josephs KA, Whitwell JL, Knopman DS, et al. 2009. Two distinct subtypes of right temporal variant frontotemporal dementia. *Neurology.* 73:1443–1450.
- Kovacs GG, Majtenyi K, Spina S, et al. 2008. White matter tauopathy with globular glial inclusions: a distinct sporadic frontotemporal lobar degeneration. *J Neuropathol Exp Neurol.* 67:963–975.
- Mackenzie IR, Neumann M, Baborie A, et al. 2011. A harmonized classification system for FTLD-TDP pathology. *Acta Neuropathol.* 122:111–113.
- Rohrer JD, Geser F, Zhou J, et al. 2010. TDP-43 subtypes are associated with distinct atrophy patterns in frontotemporal dementia. *Neurology.* 75:2204–2211.
- Rohrer JD, Lashley T, Schott JM, et al. 2011. Clinical and neuro-anatomical signatures of tissue pathology in frontotemporal lobar degeneration. *Brain.* 134(pt 9):2565–2581.
- Seelaar H, Rohrer JD, Pijnenburg YA, et al. 2011. Clinical, genetic and pathological heterogeneity of frontotemporal dementia: a review. *J Neurol Neurosurg Psychiatry.* 82:476–486.
- Seeley WW, Bauer AM, Miller BL, et al. 2005. The natural history of temporal variant frontotemporal dementia. *Neurology.* 64:1384–1390.
- Wechsler D. 1997. *Wechsler Adult Intelligence Scale*,<sup>®</sup> Third Edition. San Antonio, Texas: Psychological Corporation.