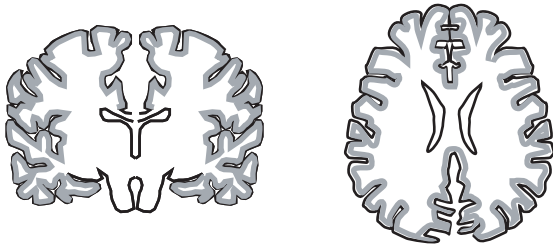
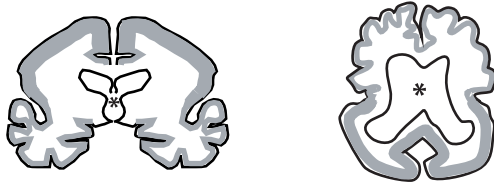

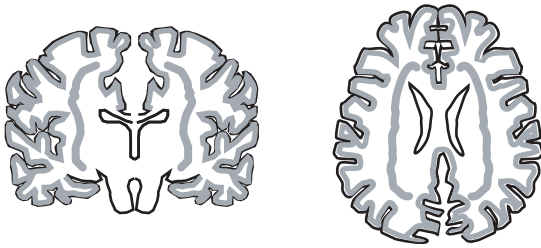
A Normal



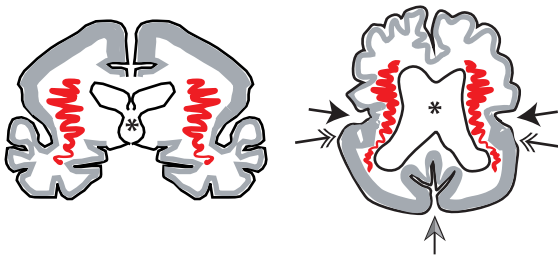
B P>A Lissencephaly



C Double Cortex (Female)



D APC2 variant Lissencephaly



- * Ventriculomegaly
- ← Abrupt transition anterior to posterior
- ←← Reduced white matter
- ← Posterior infolding