

# Clinical case: heart failure and ischaemic heart disease

Giuseppe M.C. Rosano<sup>1,2\*</sup>

<sup>1</sup>Cardiovascular Clinical Academic Group, St George's Hospitals NHS Trust University of London, Cranmer Terrace, London SW17 0RE, UK; and

<sup>2</sup>Department of Medical Sciences, IRCCS San Raffaele Roma, Roma, Italy

**KEYWORDS:** Heart failure; Cardiac rehabilitation; Diuretic therapy; Elderly

## Learning points

- Patients with ischaemic heart disease that develop heart failure should be treated as per appropriate European Society of Cardiology/Heart Failure Association (ESC/HFA) guidelines.
- Glucose control in diabetic patients with heart failure should be more lenient than in patients without cardiovascular disease.
- Optimization of cardiac metabolism and control of heart rate should be a priority for the treatment of angina in patients with heart failure of ischaemic origin.

## Introduction

This clinical case refers to an 83-year-old man with moderate chronic obstructive pulmonary disease and shows that implementation of appropriate medical therapy according to the European Society of Cardiology/Heart Failure Association (ESC/HFA) guidelines improves symptoms and quality of life.<sup>1</sup> The case also illustrates that optimization of glucose metabolism with a more lenient glucose control was most probably important in improving the overall clinical status and functional capacity.

## Case presentation

The patient has family history of coronary artery disease as his brother had suffered an acute myocardial infarction (AMI) at the age of 64 and his sister had received coronary

artery by-pass. He also has a 14-year diagnosis of arterial hypertension, and he is diabetic on oral glucose-lowering agents since 12 years. He smokes 30 cigarettes per day since childhood.

In February 2009, after 2 weeks of angina for moderate efforts, he suffered an acute anterior myocardial infarction. He presented late (after 14 h since symptom onset) at the hospital where he had been treated conservatively and had been discharged on medical therapy: Atenolol 50 mg o.d., Amlodipine 2.5 mg o.d., Aspirin 100 mg o.d., Atorvastatin 20 mg o.d., Metformin 500 mg tds, Gliclazide 30 mg o.d., Salmeterol 50, and Fluticasone 500 mg oral inhalers.

Four weeks after discharge, he underwent a planned electrocardiogram (ECG) stress test that documented silent effort-induced ST-segment depression (1.5 mm in V4-V6) at 50 W.

He underwent a coronary angiography (June 2009) and left ventriculography that showed a not dilated left ventricle with apical dyskinesia, normal left ventricular ejection fraction (LVEF, 52%); occlusion of proximal LAD, 60% stenosis of circumflex (CX), and 60% stenosis of distal right coronary artery (RCA). An attempt to cross the occluded left anterior descending (LAD) was unsuccessful.

He was therefore discharged on medical therapy with: Atenolol 50 mg o.d., Atorvastatin 20 mg o.d., Amlodipine 2.5 mg o.d., Perindopril 4 mg o.d., oral isosorbide mononitrate (ISMN) 60 mg o.d., Aspirin 100 mg o.d., metformin 850 mg tds, Gliclazide 30 mg o.d., Salmeterol 50 mcg, and Fluticasone 500 mcg b.i.d. oral inhalers.

He had been well for a few months but in March 2010 he started to complain of retrosternal constriction associated to dyspnoea for moderate efforts (New York Heart Association (NYHA) II-III, Canadian Class II).

\*Corresponding author. Tel: 02087252763, Email: grosano@sgul.ac.uk

**Table 1** Clinical parameters during follow-up visits

	December 2012	March 2013	September 2013	January 2014	January 2015
Weight (kg)	72	71	74	70	68
Height (cm)	170	170	170	170	170
BMI	24.9	24.9	25.1	24.9	24.8
JVP	+2 cm H <sub>2</sub> O	+2 cm H <sub>2</sub> O	+2 cm H <sub>2</sub> O	Normal	Normal
Oedema	Bilateral oedema up to mid shins	Bilateral pretibial oedema (2+)	Bilateral pretibial oedema (3+)	No pedal oedema	No pedal oedema
Blood pressure (mmHg)	115/80	115/75	110/60	110/70	112/68
Pulse (bpm)	88	86	92	68	56
Auscultation					
Heart	Systolic murmur 4/6 at apex, III sound	Systolic murmur 4/6 at apex, III sound	Systolic murmur 4/6 at apex, III sound	Systolic murmur 4/6 at apex	Systolic murmur 4/6 at apex
Lungs	Bilateral fine basilar crackles	Bilateral fine basilar crackles	Bilateral fine basilar and mid lung crackles	Clear	Clear
Laboratory findings					
FPG (mg/dL)	100	98	96	106	112
HbA1c (%)	6.8	6.7	6.6	7	7.3
Plasma creatinine (mg/dL)	1.1	1.2	1.5	1.1	1.2
Triglycerides	118 mg/dL	NA	NA	107 mg/dL	114 mg/dL
Total cholesterol	146 mg/dL	NA	NA	142 mg/dL	148 mg/dL
LDL-C	68 mg/dL	NA	NA	64 mg/dL	68 mg/dL
HDL-C	51 mg/dL	NA	NA	48 mg/dL	54 mg/dL
BNP	NA	862	1670	276	244
LVEF	19		20	32	32

For this reason, he was prescribed a second coronary angiography that showed progression of atherosclerosis with 80% stenosis on the circumflex (after the I obtuse marginal branch) and distal RCA. The LAD was still occluded.

After consultation with the heart team, CABG was avoided because surgical the risk was deemed too high and the patient underwent palliative percutaneous coronary intervention (PCI) of CX and RCA. It was again attempted to cross the occlusion on the LAD. But this attempt was, again, unsuccessful. Collateral circulation from posterior interventricular artery (PDL) to the LAD was found. The pre-PCI echocardiogram documented moderate left ventricular dysfunction (EF 38%), the pre-discharge echocardiogram documented a LVEF of 34%. Because of the reduced LVEF, atenolol was changed for Bisoprolol (5 mg o.d.).

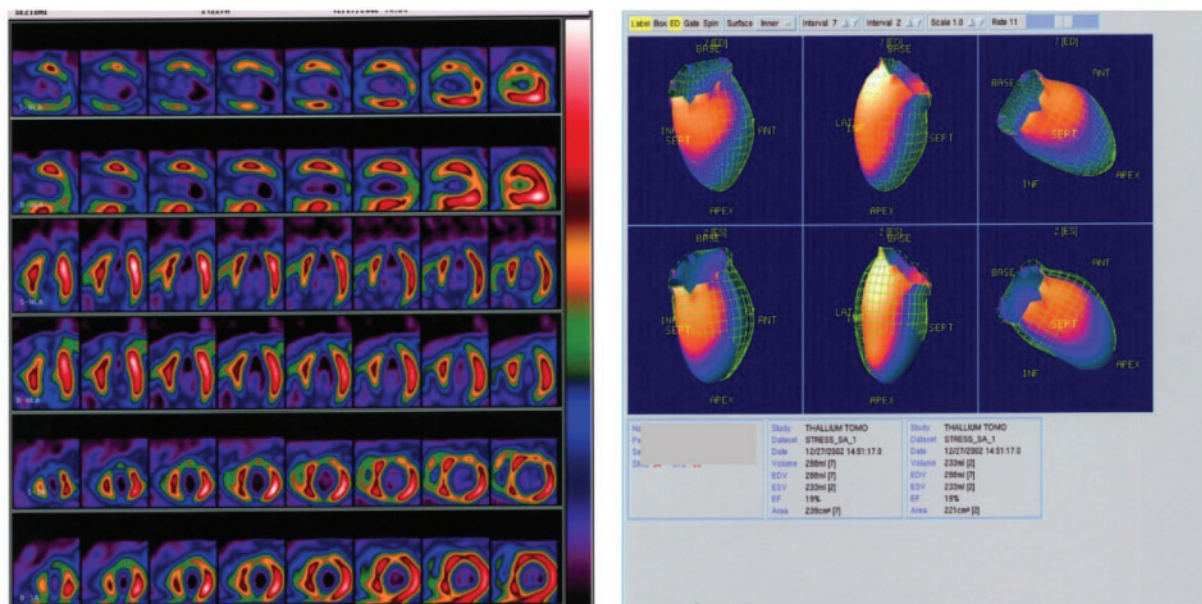
At follow-up visit in December 2012, the clinical status and the haemodynamic conditions had deteriorated. He complained of worsening effort-induced dyspnoea/angina that now occurred for less than a flight of stairs (NYHA III). On clinical examination clear signs of worsening heart failure were detected (*Table 1*). His medical therapy was modified to: Bisoprolol 5 mg o.d., Atorvastatin 20 mg o.d., Amlodipine 2.5 mg o.d., Perindopril 5 mg o.d., ISMN 60 mg o.d., Aspirin 100 mg o.d., Metformin 500 mg tds, Furosemide 50 mg o.d., Gliclazide 30 mg o.d., Salmeterol 50 mcg oral inhaler, and Fluticasone 500 mcg oral inhaler. A stress perfusion cardiac scintigraphy was requested and revealed dilated ventricles with LVEF 19%, fixed apical

perfusion defect and reversible perfusion defect of the antero-septal wall (ischaemic burden <10%, *Figure 1*). He was admitted, and an ICD was implanted.

In March 2013, he felt slightly better but still complained of effort-induced dyspnoea/angina (NYHA III, *Table 1*). Medical therapy was updated with bisoprolol changed with Nebivolol 5 mg o.d. and perindopril changed to Enalapril 10 mg b.i.d. The switch from bisoprolol to nebivolol was undertaken because of the better tolerability and outcome data with nebivolol in elderly patients with heart failure. Perindopril was switched to enalapril because the first one has no indication for the treatment of heart failure.

In September 2013, the clinical conditions were unchanged, he still complained of effort-induced dyspnoea/angina (NYHA III) and did not notice any change in his exercise capacity. His BNP was 1670. He was referred for a 3-month cycle of cardiac rehabilitation during which his medical therapy was changed to: Nebivolol 5 mg o.d., Ivabradine 5 mg b.i.d., uptitrated in October to 7.5 b.i.d., Trimetazidine 20 mg tds, Furosemide 50 mg, Metolazone 5 mg o.d., K-canrenoate 50 mg, Enalapril 10 mg b.i.d., Clopidogrel 75 mg o.d., Atorvastatin 40 mg o.d., Metformin 500 mg b.i.d., Salmeterol 50 mcg oral inhaler, and Fluticasone 500 mcg oral inhaler.

At the follow-up visit in January 2014, he felt much better and had symptomatically, he no longer complained of angina, nor dyspnoea (NYHA Class II, *Table 1*). Trimetazidine was added because of its benefits in heart failure patients of ischaemic origin and because of its



**Figure 1** Myocardial perfusion scintigraphy and left ventriculography showing dilated left ventricle with left ventricular ejection fraction 19%. Reversible perfusion defects on the antero-septal wall and fixed apical perfusion defect.

effect on functional capacity. Ivabradine was added to reduce heart rate since it was felt that increasing nebivolol, that was already titrated to an effective dose, would have had led to hypotension.

He missed his follow-up visits in June and October 2014 because he was feeling well and he had decided to spend some time at his house in the south of Italy. In January and June 2015, he was well, asymptomatic (NYHA I-II) and able to attend his daily activities. He did not complain of angina nor dyspnoea and reported no limitations in his daily activities. Unfortunately, in November 2015 he was hit by a moped while on the zebra crossing in Rome and he later died in hospital as a consequence of the trauma.

## Discussion

This case highlights the need of optimizing both the heart failure and the anti-anginal medications in patients with heart failure of ischaemic origin. This patient has improved dramatically after the up-titration of diuretics, the control of heart rate with nebivolol and ivabradine and the additional use of trimetazidine.<sup>1-3</sup> All these drugs have contributed to improve the clinical status together with a more lenient control of glucose metabolism.<sup>4</sup> This is another crucial point to take into account in diabetic patients, especially if elderly, with heart failure in whom aggressive glucose control is detrimental for their functional capacity and long-term prognosis.<sup>5</sup>

## Funding

IRCCS San Raffaele - Ricerca corrente Ministero della Salute 2018.

**Conflict of interest:** none declared. The authors didn't receive any financial support in terms of honorarium by Servier for the supplement articles.

## References

- Ponikowski P, Voors AA, Anker SD, Bueno H, Cleland JG, Coats AJ, Falk V, González-Juanatey JR, Harjola VP, Jankowska EA, Jessup M, Linde C, Nihoyannopoulos P, Parissis JT, Pieske B, Riley JP, Rosano GM, Ruilope LM, Ruschitzka F, Rutten FH, van der Meer P; Authors/Task Force Members. 2016 ESC Guidelines for the diagnosis and treatment of acute and chronic heart failure: the Task Force for the diagnosis and treatment of acute and chronic heart failure of the European Society of Cardiology (ESC) Developed with the Special Contribution of the Heart Failure Association (HFA) of the ESC. *Eur J Heart Fail* 2016;**18**:891-975.
- Rosano GM, Vitale C. Metabolic modulation of cardiac metabolism in heart failure. *Card Fail Rev* 2018;**4**:99-103.
- Vitale C, Ilaria S, Rosano GM. Pharmacological interventions effective in improving exercise capacity in heart failure. *Card Fail Rev* 2018;**4**:1-27.
- Seferović PM, Petrie MC, Filippatos GS, Anker SD, Rosano G, Bauersachs J, Paulus WJ, Komajda M, Cosentino F, de Boer RA, Farmakis D, Doehner W, Lambrinou E, Lopatin Y, Piepoli MF, Theodorakis MJ, Wiggers H, Lekakis J, Mebazaa A, Mamas MA, Tschöpe C, Hoes AW, Seferović JP, Logue J, McDonagh T, Riley JP, Milinković I, Polovina M, van Veldhuisen DJ, Lainscak M, Maggioni AP, Ruschitzka F, McMurray JJV. Type 2 diabetes mellitus and heart failure: a position statement from the Heart Failure Association of the European Society of Cardiology. *Eur J Heart Fail* 2018;**20**:853-872.
- Vitale C, Spoletini I, Rosano GM. Frailty in heart failure: implications for management. *Card Fail Rev* 2018;**4**:104-106.