

Accepted Manuscript

Comparing the diagnostic accuracy of three ultrasound modalities for diagnosing obstetric anal sphincter injuries

Annika Taithongchai, MB ChB, Isabelle M.A. van Gruting, MD, Ingrid Volløyhaug, PhD, Linda P. Arendsen, MD, Abdul H. Sultan, FRCOG, Raneer Thakar, FRCOG



PII: S0002-9378(19)30569-1

DOI: <https://doi.org/10.1016/j.ajog.2019.04.009>

Reference: YMOB 12638

To appear in: *American Journal of Obstetrics and Gynecology*

Received Date: 19 December 2018

Revised Date: 18 March 2019

Accepted Date: 8 April 2019

Please cite this article as: Taithongchai A, van Gruting IMA, Volløyhaug I, Arendsen LP, Sultan AH, Thakar R, Comparing the diagnostic accuracy of three ultrasound modalities for diagnosing obstetric anal sphincter injuries, *American Journal of Obstetrics and Gynecology* (2019), doi: <https://doi.org/10.1016/j.ajog.2019.04.009>.

This is a PDF file of an unedited manuscript that has been accepted for publication. As a service to our customers we are providing this early version of the manuscript. The manuscript will undergo copyediting, typesetting, and review of the resulting proof before it is published in its final form. Please note that during the production process errors may be discovered which could affect the content, and all legal disclaimers that apply to the journal pertain.

1 **Comparing the diagnostic accuracy of three ultrasound modalities for**
2 **diagnosing obstetric anal sphincter injuries**

3 Annika TAITHONGCHAI MB ChB, Obstetrics and Gynecology, Croydon University
4 Hospital, London, United Kingdom

5 Isabelle M.A. VAN GRUTING MD, Obstetrics and Gynecology, Croydon University
6 Hospital, London, United Kingdom

7 Ingrid VOLLØYHAUG PhD, Department of Clinical and Molecular Medicine,
8 Norwegian University of Science and Technology, Trondheim, Norway, Department
9 of Obstetrics and Gynecology, Trondheim University Hospital, Norway

10 Linda P. ARENDSSEN MD, Obstetrics and Gynecology, Croydon University Hospital,
11 London, United Kingdom

12 Abdul H SULTAN FRCOG, Obstetrics and Gynecology, Croydon University Hospital,
13 London, United Kingdom

14 Raneer THAKAR FRCOG, Obstetrics and Gynecology, Croydon University Hospital,
15 London, United Kingdom

16 **The authors report no conflict of interest.**

17 This study was funded by the Mayday Charity Fund, they had no involvement in
18 study design, collection of data, writing of the report or decision to submit the article.

19 **Clinical Trial Registration:** Registered in clinicaltrials.gov; NCT 02655900;

20 <https://clinicaltrials.gov/ct2/show/NCT02655900?term=02655900&rank=1>

21 **Paper presentations:** British Society of Urogynecology (BSUG) Annual Meeting,
22 London UK, 9th November 2018. International Urogynaecology Association (IUGA)
23 Meeting 2016 41st Annual Meeting, Cape Town, South Africa, 2-6th August 2016

24 **Corresponding author:**

25 Miss Ranee Thakar

26 Department of Obstetrics and Gynecology, Croydon University Hospital

27 520 London Road, Croydon, London

28 Telephone: 02084013161

29 e-mail: ranee.thakar@nhs.net

30

31

32

33

34

35

36

37

38

39 **Word Count: Abstract 467; Main Text 3000**

40 **Condensation**

41 Endoanal ultrasound remains the reference standard for diagnosing sphincter
42 defects, but three-dimensional introital or transperineal ultrasound can screen for an
43 intact sphincter when advising mode of delivery in a subsequent pregnancy after
44 obstetric sphincter injury.

45 **Short version of title:**

46 Ultrasound diagnosis of anal sphincter defects

47 **AJOG at a Glance (130)**

- 48 • A. Endoanal ultrasound is regarded as the reference standard for imaging the
49 anal sphincter morphology. Alternatives which are more widely available and
50 accepted by patients include three-dimensional introital and transperineal
51 ultrasound. However, it is unknown whether they are accurate enough to
52 replace endoanal ultrasound.
- 53 • B. Three-dimensional introital and transperineal ultrasound provide suitable
54 screening tools for an intact anal sphincter, but are not sensitive enough to
55 accurately detect defects. Onward referral for endoanal ultrasound would be
56 required if a defect is seen, as this remains the reference standard and
57 correlates best with symptoms.
- 58 • C. The cut-off for an external anal sphincter defect on tomographic ultrasound
59 imaging is $\geq 3/7$ slices and for an internal anal sphincter defect is $\geq 2/7$ slices,
60 providing standardization within the field for reporting and clinical use.

61

62 C. Abstract

63 **Background:** The optimal imaging modality of obstetric anal sphincter injuries
64 (OASIs) needs to take into consideration convenience, availability and ability to
65 assess the sphincter morphology. Endoanal ultrasound is currently regarded as the
66 reference standard but is not widely available in obstetric units. Exoanal alternatives
67 exist, such as three-dimensional (3D) introital or transperineal ultrasound, which are
68 already readily available in most obstetrics and gynecology units.

69 **Objectives:** The primary objective was to evaluate the diagnostic accuracy of 3D
70 introital and 3D transperineal ultrasound compared to 3D endoanal ultrasound as the
71 reference standard for the detection of anal sphincter defects in women who
72 sustained obstetric anal sphincter injuries. The secondary objective was to correlate
73 diagnosis of anal sphincter defect on imaging to symptoms of anal incontinence, and
74 to assess patient discomfort experienced for each imaging modality

75 **Study Design:** A cross-sectional study of 250 women who sustained OASIs, all
76 underwent 3D introital, transperineal and endoanal ultrasound. Introital and
77 transperineal ultrasound were assessed using tomographic ultrasound imaging. All
78 completed a validated modified St Mark's Score and Visual Analogue Score for
79 discomfort. Optimal cut-off values for a significant defect on tomographic ultrasound
80 imaging were defined as those with the greatest sensitivity and specificity based on
81 Receiver Operating Characteristic curves with endoanal ultrasound as reference
82 standard. Diagnostic test characteristics of introital and transperineal ultrasound
83 using these optimal cut-offs were calculated.

84 **Results:** Optimal cut-off for a significant external anal sphincter defect was $\geq 3/7$
85 slices; sensitivity and specificity were 0.65 and 0.75 on introital and 0.70 and 0.69 on

86 transperineal ultrasound respectively. Optimal cut-off for a significant internal anal
87 sphincter defect was $\geq 2/5$ slices; sensitivity and specificity were 0.59 and 0.84 on
88 introital and 0.43 and 0.97 on transperineal ultrasound. The Area Under the Curve
89 for diagnosing external and internal anal sphincter defects ranged from 0.70 - 0.74
90 ($p < 0.001$) for introital and transperineal. Positive predictive value for external and
91 internal sphincter defects ranged from 0.37-0.63 and negative predictive value
92 ranged from 0.85-0.93 for transperineal and introital ultrasound.

93 Endoanal ultrasound was the only modality for a defect to correlate with symptoms;
94 mean modified St Mark's score 2.4 (SD 4.1) for defect sphincter and 0.9 (SD 2.7) for
95 intact sphincter ($p < 0.01$). Introital and transperineal ultrasound were associated with
96 less discomfort than endoanal ultrasound.

97 **Conclusion:** Endoanal ultrasound remains the most accurate diagnostic imaging
98 modality. With low positive predictive values, introital and transperineal ultrasound
99 are not suitable for identifying sphincter defects; however high negative predictive
100 values show a good ability to detect an intact sphincter. The optimal cut-off number
101 of slices on tomographic ultrasound imaging for external and internal anal sphincters
102 allows for standardisation of a significant defect. In women with a history of OASI,
103 introital and transperineal ultrasound are suitable to screen for an intact sphincter if
104 endoanal ultrasound is not available. Women with defects seen should then have
105 endoanal ultrasound to verify the diagnosis.

106

107 **Key words:** Anal canal, diagnostic test accuracy, endoanal ultrasound, gynecology,
108 introital ultrasound, obstetrics, obstetric anal sphincter injury, OASI, ROC curve,

109 sensitivity and specificity, transperineal, ultrasonography

ACCEPTED MANUSCRIPT

110 **D. Text**

111 **Introduction:**

112 Obstetric anal sphincter injury (OASI) is one of the main causes of anal incontinence,
113 occurring in up to 35% of vaginal deliveries.¹⁻³ It can significantly impact women's
114 social, psychological and physical quality of life, and is increasingly associated with
115 litigation.⁴ Endoanal ultrasound (EAUS) assessment of the anal sphincters following
116 OASI has been shown to be useful particularly in counselling regarding mode of
117 delivery in a subsequent pregnancy.⁵⁻⁷ Clinical examination is associated with poor
118 detection of sphincter damage⁸; ultrasound diagnostic accuracy is better.⁹

119 There has been increasing interest in the optimal imaging modality of OASIs, taking
120 into account convenience, availability and ability to assess the sphincter morphology.
121 To date, most research has been carried out using the EAUS technique,^{1,3,10}
122 currently regarded as the reference standard.^{9,11} However, it requires a trained
123 operator, expensive specialised equipment and it is relatively intrusive to the patient.
124 Furthermore, it may distend the muscular anatomy of the anal canal.¹² Alternative
125 exoanal approaches include introital (IUS)^{12,13} and transperineal ultrasound
126 (TPUS)¹⁴⁻¹⁷, visualising the sphincter in an undisturbed state. Moreover, the
127 equipment for these scans is readily available in most obstetric and gynecology
128 units.

129 With ultrasound advances, three and four dimensional (3D/4D) technology is also
130 becoming increasingly popular. Advantages include multiplanar imaging, short
131 examination times and digital volume storage allowing for later re-analysis.^{16,17}

132 The primary aim of this study was to evaluate the diagnostic test accuracy of 3D IUS
133 and 3D TPUS compared to 3D EAUS as reference standard for the detection of anal
134 sphincter defects in women who sustained OASIs. The secondary aim was to
135 correlate diagnosis of anal sphincter defect on imaging to symptoms of faecal
136 incontinence, and to assess patient discomfort experienced for each imaging
137 modality.

138

139 **Materials and Methods**

140 This was a cross-sectional study of 250 consecutive women who had sustained
141 OASIs and undergone primary repairs of the anal sphincter. They were recruited
142 from the perineal clinic of the tertiary urogynaecology centre of Croydon University
143 Hospital (CUH), United Kingdom. All the women were referred from within CUH or
144 the surrounding regions for assessment 6 to 12 weeks post-partum or seen in a
145 subsequent pregnancy for counselling regarding mode of delivery. Women were
146 recruited prospectively from October 2013 to August 2015. Women aged 18 years or
147 older who could read and understand English were eligible. The study was approved
148 by the National Research Ethics Service South East London Committee (REC
149 number 13/LO/0232), and local research and development department; IRAS project
150 number 122213 and registered in clinicaltrials.gov (NCT 02655900). All study
151 participants gave written informed consent.

152 Demographic data (age, BMI, ethnicity and parity) of each patient was collected.
153 Each patient completed a validated modified St Mark's score¹⁸, this is a 24-point
154 scoring system for anal incontinence symptoms; accounting for faecal urgency, flatal

155 incontinence, liquid and solid faecal incontinence, impact on lifestyle as well as the
156 use of incontinence pads or constipating medication. For each patient all ultrasound
157 assessments were performed on the same day. EAUS was performed at rest using
158 the Pro-focus 2202 and Flex-focus 500 ultrasound systems (BK medical, Herlev,
159 Denmark) fitted with a 12 - 16 MHz anorectal transducer (type 2052; focal point up to
160 20 mm and focal range 5 - 45 mm, with 360° acquisition). With the patient lying in the
161 left lateral position, the probe was inserted along the axis of the anal canal and the
162 3D cube imaged the full length of the anal sphincter; starting proximally at the
163 puborectalis muscle to the most distal aspect of the subcutaneous level of the
164 external anal sphincter (EAS). IUS and TPUS were performed using the GE Voluson
165 I system (GE medical systems, Zipf, Austria). Both were performed at rest with the
166 patient in the supine position. IUS was performed using a 3D 5-9 MHz endocavity
167 probe placed with low pressure on the posterior fourchette in a vertical axis towards
168 the anal sphincter complex. TPUS was performed using a 3D 4-8.5 MHz curved
169 array abdominal probe. The probe was placed transversely on the perineum and
170 inclined to visualize the "U" shape of the puborectalis muscle and angulated to
171 visualize the full length of the sphincter. Both modalities had an acquisition angle of
172 85°. All ultrasound examinations were performed by an investigator experienced in
173 imaging of the anal sphincter (lvG).

174 The 3D image volumes of all three modalities were stored for off-line assessment.
175 Image analysis was performed using the 3D BK viewing programme (version 5.19,
176 BK Medical) for EAUS and the 4D View software (version 10.2, GE Medical
177 Systems) for IUS and TPUS by three independent investigators who were blinded to
178 clinical and other imaging findings. Every investigator analysed 30 volumes of each

179 modality, and intra-class correlation analysis was performed to assess agreement.
180 After substantial agreement was found, the remaining volumes were analysed by a
181 single investigator independently (AT analysed EAUS, IV IUS and LA TPUS).

182 The 3D EAUS cube was assessed by rating the sphincter complex integrity at three
183 levels starting after the “U” shape of the puborectalis muscle; (1) the deep level, up
184 to where the EAS muscle forms anteriorly in the midline, (2) the superficial level,
185 where the IAS (hypoechoic) and EAS (hyperechoic) should be seen as complete
186 rings and (3) the subcutaneous level of the EAS, where the IAS is no longer present
187 (Figure 1a).

188 IUS and TPUS were both assessed using tomographic ultrasound imaging (TUI).
189 The TUI was adjusted to have 8 slices, with the inter-slice interval varying according
190 to individual sphincter length. EAS (slices 2-8) and IAS (slices 2-6) were evaluated in
191 the same TUI. Slice 1 corresponds with the puborectalis level. Slice 2 was adjusted
192 to be the most cranial aspect of the EAS (deep level), where the muscle comes
193 together in the midline, with the superficial level ending at slice 6. Slices 7 and 8
194 covered the subcutaneous level (Figure 1b and 1c).

195 Defect sizes were measured for all three modalities using a 3-point angle, with the
196 angle vertex in the middle of the anal canal. The 3D EAUS cube was assessed in the
197 deep, superficial and subcutaneous levels for defects, with manipulation of the cube
198 in the axial, coronal and sagittal planes to aid diagnosis. Any defect of ≥ 30 degrees
199 of partial or full thickness was measured for IAS and EAS and considered significant
200 if present at ≥ 1 level¹⁷ (figure 2a). The same cut-off angle for EAS and IAS defect
201 was also used for IUS and TPUS for consistency in analysis (figure 2b and 2c). The
202 EAS was evaluated both with and without the subcutaneous level to assess whether

203 diagnostic performance would be affected by the inclusion of this level. In addition,
204 we looked at the deep level independently and calculated sensitivity and specificity
205 of IUS and TPUS in detecting a defect at this level, as this can be the most
206 challenging level to diagnose defects accurately in view of anatomical variations.

207 Norderval score was calculated for all three ultrasound modalities (Table 1),
208 accounting for the length, depth and size of both EAS and IAS defects, with 0 being
209 no defect and 7 maximal defect.¹⁹

210 Following each scan, women were asked to complete a visual analogue pain
211 assessment tool to determine the discomfort of each modality, ranging from 0 (no
212 discomfort) to 10 (severe discomfort).

213

214 *Statistical Analysis*

215 The mean values for demographic variables were calculated. Inter class correlation
216 (ICC) analysis (absolute agreement between the mean of k raters, 2-way random-
217 effects model) between the three investigators was performed for the Norderval
218 scores of 30 volumes for each imaging modality. Based on the 95% confident
219 interval of the ICC estimate, values less than 0.50 indicate poor, 0.50 to 0.75
220 moderate, 0.75 to 0.90 good, and greater than 0.90 excellent reliability.^{20,21}

221 Spearman's rank correlation was used to test correlation of Norderval scores
222 between different imaging methods. The sensitivity and specificity of IUS and TPUS
223 was calculated using EAUS as the reference standard and receiver operating
224 characteristic (ROC) curves were created.²² The area under the ROC curve (AUC)
225 was calculated, where 0.50 denotes no clinical application as a test, 0.60-0.70 poor,

226 0.70-0.80 fair, 0.80-0.90 good and >0.90 an excellent test.²³ This was done including
227 all levels for the EAS (slices 2-8) and IAS (slices 2-6) and subsequently excluding
228 the subcutaneous level of the EAS (slices 2-6). The number of slices with the best
229 diagnostic performance was selected to define the best cut-off value for the detection
230 of a significant EAS and IAS defect within a population of known OASI. Diagnostic
231 test characteristics for these cut-offs were calculated. Mann-Whitney U test was
232 used to test the modified St Mark's Score against intact or defect sphincters for each
233 imaging modality using the new cut-off values. Mann-Whitney U test was used to
234 assess the difference in visual analogue scores of discomfort for IUS and TPUS
235 compared to EAUS.

236 Sample size calculation was based on the assumption of a 30% prevalence of anal
237 sphincter defects in the population of interest.¹⁶ A sample size of 200 women would
238 provide 60 women with sphincter defects. 60 women with a sphincter defect would
239 give a confidence interval of 0.50 to 0.75, assuming a true rate of sensitivity of 0.64.
240 140 women with an intact sphincter would provide a confidence interval of 0.78 to
241 0.90 when assuming a specificity of 0.85. Recruiting 250 women would allow for
242 unusable volumes for analysis or incomplete data sets.

243 Statistical analysis was performed with IBM SPSS statistics version 23 software (IBM
244 SPSS, Armonk, NY, USA). A p -value <0.05 was considered statistically significant
245 for all analyses.

246

247 **Results**

248 In total, 250 women were examined at a median of 5 (range 1-137) months after the
249 index (OASI) delivery of whom 88 were pregnant with a subsequent pregnancy at
250 the time of examination. Average age was 31.5 years (SD 4.5), mean BMI was 25.3
251 kg/m² (SD 4.7) and 183/248 (74%) had a parity of 1. The main ethnic group was
252 Caucasian 116 (46%) with other ethnicities being: Indian 55 (22%), other Asian 35
253 (14%), black 27 (11%) and 17 (7%) of mixed or unknown ethnicity.

254 The ICC of the Norderval score among the 3 analysers for 30 volumes showed a
255 significant correlation: 0.83 (95% CI 0.70-0.92, $p < 0.01$) for EAUS, 0.76 (95% CI
256 0.57-0.88, $p < 0.01$) for IUS and 0.86 (95% CI 0.74-0.93, $p < 0.01$) for TPUS.

257 A defect of ≥ 30 degrees in ≥ 1 level was present in 79/248 (32%) women on EAUS,
258 in 134/246 (55%) on IUS and in 118/243 (49%) on TPUS. Two volumes were
259 missing for different women, and not all volumes had complete data to fully assess
260 the EAS or IAS for IUS or TPUS. The mean (SD) Norderval scores for EAUS, IUS
261 and TPUS were 1.2 (2.0), 1.8 (1.9) and 1.1 (1.5) respectively. The correlation of
262 Norderval scores was moderate; between EAUS and IUS it was $r_s = 0.42$, $p < 0.001$
263 and between EAUS and TPUS it was $r_s = 0.47$, $p < 0.001$.

264 The AUC for IUS and TPUS and the sensitivities and specificities for each number of
265 TUI slices for diagnosing EAS and IAS defects are indicated in Table 2. The number
266 of slices with the best diagnostic performance for a significant EAS defect was ≥ 3 of
267 7 slices; sensitivity and specificity 0.65 and 0.75 on IUS and 0.70 and 0.69 on TPUS.
268 Optimal cut-off for significant IAS defect was ≥ 2 of 5 slices; sensitivity and specificity
269 0.59 and 0.84 on IUS and 0.43 and 0.97 on TPUS. The ROC curves for diagnosis of
270 EAS and IAS defects on IUS and TPUS are presented in Figure 3a and 3b. The AUC
271 for EAS defects (with subcutaneous level included) on IUS was 0.74 (95% CI 0.66-

272 0.81, $p < 0.001$) and on TPUS 0.72 (95% CI 0.64-0.79, $p < 0.001$). The AUC for IAS
273 defects on IUS was 0.72 (95% CI 0.62-0.83, $p < 0.001$) and on TPUS 0.70 (95%CI
274 0.57-0.82, $p = 0.001$). Both IUS and TPUS had greater AUC for EAS defects when the
275 subcutaneous level was included, although not statistically significant. Table 3 shows
276 a summary of the diagnostic test characteristics of both IUS and TPUS using the
277 optimal cut-off values.

278 Sixty-one women had anal incontinence symptoms, of whom 30 had a defect on
279 EAUS. Endoanal ultrasound was the only modality for a defect to correlate with the
280 modified St Mark's Score; mean score 2.4 (SD 4.1) for defect sphincter and 0.9 (SD
281 2.7) for intact sphincter ($p < 0.01$). There was no difference in mean modified St
282 Mark's Score between intact or defect sphincter for either IUS or TPUS; 1.1 (SD 2.5)
283 vs 1.8 (SD 3.8) $p = 0.40$ and 1.1 (SD 2.6) vs 1.6 (SD 3.5), $p = 0.17$ respectively.

284 Discomfort scores of the imaging technique were documented for 238/250 patients.
285 The median discomfort scores for IUS (1.0, SD 1.8) and TPUS (0.0, SD 1.3) were
286 significantly lower when compared to EAUS (4.0, SD 2.3) (both $p < 0.001$).

287 **Comment:**

288 The study aim was to assess diagnostic test accuracy of 3D IUS and TPUS
289 compared to 3D EAUS as reference standard for the detection of anal sphincter
290 defects in women who sustained OASIs. Optimal cut-off for a significant EAS defect
291 was ≥ 3 of 7 slices and for significant IAS defect ≥ 2 of 5 slices on TUI. Both IUS and
292 TPUS had AUC showing fair ability to diagnose EAS and IAS defects. Both had high
293 NPV suggesting good ability to identify an intact sphincter; but low PPV indicating
294 poor detection of sphincter defects. EAUS was the only modality to correlate with

295 anal incontinence symptoms. IUS and TPUS were associated with less discomfort
296 than EAUS.

297 When first described, IUS suggested good correlation with EAUS.²⁴ Later, a larger
298 study showed in fact low sensitivity, with high specificity²⁵; comparable to our
299 findings. 2D IUS and TPUS have been compared to EAUS in a large study;
300 concluding that 2D TPUS could identify an intact sphincter, but lacked sensitivity to
301 detect defects.¹⁶ Our study found higher sensitivity values using 3D, suggesting 3D
302 can offer improved detection compared to 2D. The only other study comparing all 3D
303 modalities had 55 patients; they substantiated that 3D technology with TPUS
304 improves the test accuracy compared to 2D and that 3D TPUS has potential in
305 screening,²⁶ similar to other studies.^{27, 28} With our significantly larger study, we
306 confidently agree that (with AUC values between 0.70-0.74) 3D IUS and TPUS are
307 not suitable diagnostic tests to substitute EAUS.

308 The development of optimal cut-off values for a significant EAS and IAS defect on
309 TUI allows for standardized reporting, in clinical and research settings. Although a
310 cut-off of $\geq 4/6$ slices on TUI has been validated against symptoms in urogynaecology
311 patients²⁹, we are aiming for a cut-off to detect a sphincter defect in women known to
312 have OASI. We know the majority of women with OASI will not have symptoms until
313 later in life, if at all, and therefore a defect can be significant even if not associated
314 with symptoms. There has been debate about whether the subcutaneous component
315 of the EAS should play a part in defining a defect.²⁹ We found that its inclusion led
316 towards improved diagnostic performance, although not statistically significant. The
317 subcutaneous part of the EAS contributes to a significant proportion of the sphincter
318 and thus should be included. In the deep level it was more difficult to accurately

319 diagnose a defect on IUS or TPUS compared to EAUS, indicated by lower AUC for
320 this level when isolated. This demonstrates the poor ability of distinguishing a defect
321 from anatomical variation at this level.

322 We believe that this is the most adequately powered study to date comparing these
323 three 3D imaging modalities to be able to draw firm conclusions. We also used
324 validated scoring systems for symptoms and scan findings. In addition, the study
325 population is generalizable and there is low risk of detection bias as all examiners
326 were blinded to other scan results and clinical history. However, using three
327 examiners, even with good ICC, may have introduced bias. We acknowledge that
328 the quality of the scanning machine for EAUS was superior to that used for IUS and
329 TPUS. It is possible that accuracy could be improved with a new generation scanner.
330 We also acknowledge the heterogeneity of this study population, as some women
331 were pregnant. In addition there was a large range in follow-up time. Although
332 presence of anal incontinence symptoms may change with time and pregnancy
333 status, these two confounders have no effect on sphincter defects or morphology.^{3, 30}
334 Therefore as all scans were performed on the same day for each woman, the
335 diagnostic accuracy of each modality or correlation with symptoms should not be
336 affected.

337 Patient acceptability should be considered. As expected, the less intrusive nature of
338 IUS and TPUS led to reduced discomfort. The IUS probe requires pressure on the
339 posterior fourchette, this and hence tissue proximity could result in reduced visibility
340 of distal defects at 12 o'clock. This may support the use of TPUS over IUS.

341 When evaluating applicability, cost and equipment availability are important. IUS and
342 TPUS probes are already used widely by obstetricians and gynaecologists; providing

343 a cheaper alternative to the more specialised endoanal probe. However, one must
344 appreciate that the interpretation of all techniques requires training and expertise.

345 This study was carried out in a cohort with a high prevalence of sphincter defects,
346 therefore the NPV would be expected to be even higher in an unselected cohort of
347 postpartum women. This would support their use to screen for an intact sphincter on
348 labour ward, immediately after delivery. Although likely to be highly accepted by
349 patients and reduce undetected OASI, it would require widespread training of
350 obstetricians, instead of improving examination skills. Likely, the most appropriate
351 place for these modalities is in the antenatal setting, assessing women in
352 subsequent pregnancies after OASI to advise mode of delivery.

353 In conclusion, 3D EAUS remains the most accurate method for the diagnosis of anal
354 sphincter defects, correlating best with symptoms, and cannot be substituted by IUS
355 or TPUS. High NPV indicate that, in women with a history of OASI, IUS and TPUS
356 are useful for screening an intact sphincter in situations where EAUS is not available.
357 However, with a low PPV, women with defects on IUS or TPUS would need referral
358 for EAUS to verify the diagnosis.

359

360 **Acknowledgements:** Acknowledgments to Mr M. Naidu for setting up the study.
361 Employed at Croydon University Hospital, funded by National Health Service and no
362 compensation received.

363

ACCEPTED MANUSCRIPT

364 **E. References**

- 365 1. Sorensen M, Tetzschner T, Rasmussen OO, Bjarnesen J, Christiansen J.
366 Sphincter rupture in childbirth. *Br J Surg*, 1993; 80(3):392-4.
- 367 2. Sultan AH, Kamm MA, Hudson CN, Bartram CI. Third degree obstetric anal
368 sphincter tears: risk factors and outcome of primary repair. *BMJ* 1994; 308:887-91.
- 369 3. Sultan AH, Kamm MA, Hudson CN, Thomas JM, Bartram CI. Anal sphincter
370 disruption during vaginal delivery. *N Engl J Med* 1993; 329: 1905-11.
- 371 4. Leigh RJ and Turnberg LA. Faecal incontinence: the unvoiced symptom. *Lancet*,
372 1982; 1(8285):1349-51.
- 373 5. Scheer I, Thakar R, and Sultan AH. Mode of delivery after previous obstetric anal
374 sphincter injuries (OASIS)--a reappraisal? *Int Urogynecol J Pelvic Floor Dysfunct*,
375 2009; 20(9):1095-101.
- 376 6. Jordan PA, Naidu M, Thakar R, Sultan AH. Effect of subsequent vaginal delivery
377 on bowel symptoms and anorectal function in women who sustained a previous
378 obstetric anal sphincter injury. *Int Urogynecol J* (2018)
379 <https://doi.org/10.1007/s00192-018-3601-y> (Epub ahead of print)
- 380 7. Fitzpatrick M, Cassidy M, Barassaud ML, Hehir MP, Hanly AM, O'Connell PR,
381 O'Herlihy C. Does anal sphincter injury preclude subsequent vaginal delivery? *Eur J*
382 *Obstet Gynecol Reprod Biol*. 2016; 198: 30-4
- 383 8. Roos AM, Abdool Z, Thakar R, Sultan AH. Predicting anal sphincter defects: the
384 value of clinical examination and manometry. *Int Urogynecol J* 2012; 23(6):755-63

- 385 19. Abdool Z, Sultan AH, Thakar R. Ultrasound imaging of the anal sphincter
386 complex: a review. *Br J Radiol.* 2012; 85(1015):865-875
- 387 10. Andrews V, Sultan AH, Thakar R, Jones PW. Occult anal sphincter injuries- myth
388 or reality? *BJOG* 2006; 113:195-200
- 389 11. Sultan AH, Kamm MA, Talbot IC, Nicholls RJ, Bartram CI. Anal endosonography
390 for identifying external sphincter defects confirmed histologically. *Br J Surg* 1994;
391 81:463-5
- 392 12. Sultan AH, Loder PB, Bartram CI, Kamm MA, Hudson CN. Vaginal
393 endosonography. New approach to image the undisturbed anal sphincter. *Dis Colon*
394 *Rectum* 1994; 37(12):1296–1299
- 395 13. Meriwether KV, Hall RJ, Leeman LM, Migliaccio L, Qualls C, Rogers RG. Anal
396 sphincter complex: 2D and 3D endoanal and translabial ultrasound measurement
397 variation in normal postpartum measurements. *Int Urogynecol J.* 2015; 26(4):511-7
- 398 14. Valsky DV, Cohen SM, Lipschutz M, Hochner-Ceilnikier D, Yagel S. Three-
399 dimensional transperineal ultrasound findings associated with anal incontinence after
400 intrapartum sphincter tears in primiparous women. *Ultrasound Obstet Gynecol* 2012;
401 39(1):83-90.
- 402 15. Weinstein MM, Pretorius DH, Jung SA, Hager CW, Mittal RK. Transperineal
403 three-dimensional ultrasound imaging for detection of anatomic defects in the anal
404 sphincter complex muscles. *Clin Gastroenterol Hepatol* 2009; 7(2):205-11.

- 405 16. Roos AM, Abdool Z, Sultan AH, Thakar R. The diagnostic accuracy of
406 endovaginal and transperineal ultrasound for detecting anal sphincter defects: The
407 PREDICT study. *Clin Radiol* 2011; 66(7):597-604.
- 408 17. Dietz HP Exoanal imaging of the anal sphincter. *J Ultrasound Med* 2018; 37:263-
409 280
- 410 18. Roos AM, Sultan AH, Thakar R. St. Mark's incontinence score for assessment of
411 anal incontinence following obstetric anal sphincter injuries (OASIS). *Int Urogynecol*
412 *J Pelvic Floor Dysfunct.* 2009 Apr;20(4):407-10.
- 413 19. Norderval S, Markskog A, Røssaak K, et al. Correlation between anal
414 sphincter defects and anal incontinence following obstetric sphincter
415 tears: assessment using scoring systems for sonographic classification of
416 defects. *Ultrasound Obstet Gynecol* 2008; 31:78
- 417 20. Koo TK, Li MY. A Guideline of selecting and reporting intraclass correlation
418 coefficients for reliability research. *Journal of Chiropractic Medicine* 2016; 15:155-
419 163
- 420 21. Gisev N, Bell JS, Chen TF. Interrater agreement and inter-rater reliability: Key
421 concepts, approaches, and applications. *Research in Social and Administrative*
422 *Pharmacy.* 2013; 9:330–338
- 423 22. Griner PF, Mayewski RJ, Mushlin AI, Greenland P Selection and interpretation of
424 diagnostic tests and procedures. *Annals of Internal Medicine* 1981; 94:555-600

- 425 23. The Area Under an ROC Curve <http://gim.unmc.edu/dxtests/roc3.htm> Accessed
426 20th September 2018
- 427 24. Sultan AH, Nicholls RJ, Kamm MA, Hudson CN, Beynon J, Bartram CI. Anal
428 endosonography and correlation with in vitro and in vivo anatomy. *Br J Surg*, 1993.
429 80(4):508-11
- 430 25. Frudinger A, Bartram CI, Kamm MA. Transvaginal versus anal endosonography
431 for detecting damage to the anal sphincter. *Am J Roentgenol* 1997; 168:1435–1438
- 432 26. Ros C, Martinez-Franco E, Wozniak MM, Cassado J, Santoro GA, Elias N,
433 Lopez M, Palacio M, Wieczorek AP, Espuna-Pons M. Postpartum two- and three-
434 dimensional ultrasound evaluation of anal sphincter complex in women with obstetric
435 anal sphincter injury. *Ultrasound Obstet Gynecol* 2017; 49:508-514
- 436 27. Garcia-Majido JA, Palomino LG, Palacin AF, Sainz-Bueno JA. Applicability of
437 3/4D transperineal ultrasound for the diagnosis of anal sphincter injury during the
438 immediate postpartum. *Ciugia y Cirujanos* 2017;85(1);80-86
- 439 28. Oom D M, West R L, Schouten W R, Steensma A B. Detection of anal sphincter
440 defects in female patients with fecal incontinence: a comparison of 3-dimensional
441 transperineal ultrasound and 2-dimensional endoanal ultrasound. *Dis Colon*
442 *Rectum*. 2012; 55(6):646–652
- 443 29. Guzman Rojas RA, Kamisan AI, Shek KL, Dietz HP. Anal sphincter trauma and
444 anal incontinence in urogynaecological patients. *Ultrasound Obstet Gynecol*. 2015;
445 46(3):363-6

446 30. Sultan AH, Kamm MA, Hudson CN, Bartram CI Effect of pregnancy on anal
447 sphincter morphology and function. Int J Colorectal Dis 1993; 8(4):206-9

448

ACCEPTED MANUSCRIPT

449 **F. Tables**450 **Table 1** Norderval scoring system for anal sphincter defects.¹⁹

	Score 0	Score 1	Score 2	Score 3
<i>External anal sphincter</i>				
Length of defect	≤50%	≥50%		
Depth of defect	None	Partial	Total and ≤90° radial extension	Total and > 90° radial extension
<i>Internal anal sphincter</i>				
Length of defect	≤50%	≥50%		
Depth of defect	None	Total and ≤90° radial extension	Total and > 90° radial extension	

451

452 Total score is calculated from adding the total length and depth score for both

453 external and internal anal sphincter.

454

455 **Table 2**

456 Sensitivity and specificity per number of tomographic ultrasound imaging slices for
 457 detection of external and internal anal sphincter defects using introital and
 458 transperineal ultrasound compared to endoanal ultrasound as the reference standard
 459 using Receiver Operator Characteristic curves.

Number of TUI slices		Sensitivity	Specificity	AUC	95% CI	p
<i>EAS without subcutaneous level</i>						
IUS	1	0.76	0.63	0.70	0.63-0.77	<0.001
	2	0.68	0.69			
	3	0.53	0.76			
	4	0.41	0.81			
	5	0.18	0.90			
TPUS	1	0.69	0.63	0.68	0.61-0.76	<0.001
	2	0.66	0.65			
	3	0.64	0.69			
	4	0.61	0.73			
	5	0.54	0.78			
<i>EAS with subcutaneous level included</i>						
IUS	1	0.82	0.61	0.74	0.66-0.81	<0.001
	2	0.77	0.65			
	3	0.65	0.75			
	4	0.55	0.80			
	5	0.34	0.86			
	6	0.23	0.89			
	7	0.13	0.93			
TPUS	1	0.73	0.63	0.72	0.64-0.79	<0.001
	2	0.73	0.66			
	3	0.70	0.69			
	4	0.66	0.73			
	5	0.61	0.76			
	6	0.49	0.82			
	7	0.37	0.87			
<i>IAS</i>						
IUS	1	0.63	0.81	0.72	0.62-0.83	<0.001
	2	0.59	0.84			
	3	0.47	0.88			
	4	0.19	0.94			
	5	0.30	0.99			
TPUS	1	0.43	0.96	0.70	0.57-0.82	0.001
	2	0.43	0.97			
	3	0.39	0.98			
	4	0.29	0.98			
	5	0.21	0.99			
<i>ANY EAS and/or IAS defect in the deep level (slice 2)</i>						
IUS		0.36	0.84	0.60	0.52-0.69	0.02
TPUS		0.64	0.69	0.67	0.59-0.75	<0.001

460 TUI, tomographic ultrasound imaging; EAS, external anal sphincter; IAS, internal
461 anal sphincter; IUS, introital ultrasound; TPUS transperineal ultrasound; AUC, area
462 under the curve

463

ACCEPTED MANUSCRIPT

464 **Table 3**

465 Diagnostic test characteristics of introital and transperineal ultrasound for diagnosis
 466 of external and internal anal sphincter defects using endoanal ultrasound as
 467 reference standard in 250 women who sustained obstetric anal sphincter injury.

Anal sphincter	Imaging Modality	Defect[§] n/N (%)	Sensitivity	Specificity	PPV	NPV	LR+	LR-
EAS	EAUS N=248*	73/248 (29.4)	n/a	n/a	n/a	n/a	n/a	n/a
	IUS N=248*	80/223 [‡] (35.9)	0.65	0.75	0.50	0.86	2.60	0.47
	TPUS N=246*	96/227 [†] (42.3)	0.70	0.69	0.51	0.85	2.26	0.43
IAS	EAUS N=248*	34/248 (13.7)	n/a	n/a	n/a	n/a	n/a	n/a
	IUS N=248*	52/241 [‡] (21.6)	0.59	0.84	0.63	0.93	3.69	0.49
	TPUS N=246*	19/238 [†] (8.0)	0.43	0.97	0.37	0.93	14.33	0.59

468 EAS, external anal sphincter; IAS, internal anal sphincter; EAUS, endoanal

469 ultrasound; IUS, introital ultrasound; TPUS transperineal ultrasound; PPV, positive

470 predictive value; NPV, negative predictive value; LR+, positive likelihood ratio; LR-,
471 negative likelihood ratio; n/a, not applicable.

472

473 [§]Using the cut off values of ≥ 1 level for EAUS, $\geq 3/7$ slices for EAS or $\geq 2/5$ slices for
474 IAS on IUS/TPUS * Two volumes for different women were missing

475 [‡]22 volumes had incomplete data to fully assess EAS and or IAS

476 [†] 23 volumes had incomplete data to fully assess EAS and or IAS

477

478 **G. Figure Legends**

479 **Figure 1 – Intact anal sphincter**

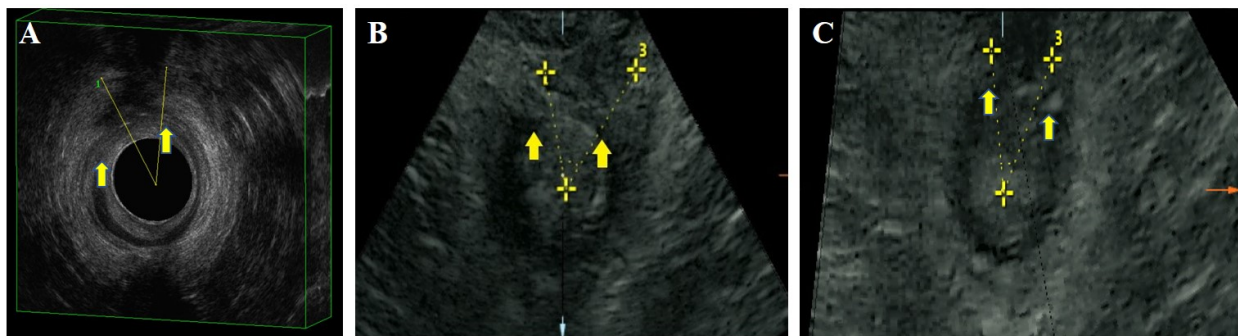- 480 A. Three-dimensional endoanal ultrasound images of an intact sphincter with the
481 external anal sphincter seen as the complete hyperechoic ring encircling the
482 complete hypoechoic ring of the internal anal sphincter. The puborectalis (1),
483 deep (2), superficial (3) and subcutaneous (4) levels are shown.
- 484 B. Introital Tomographic ultrasound imaging (TUI) demonstrating an intact
485 external (slices 2-9) and internal (slices 2-7) anal sphincter.
- 486 C. Transperineal TUI demonstrating an intact external (slices 2-9) and internal
487 (slices 2-7) anal sphincter.

488 **Figure 2 – Defect anal sphincter**

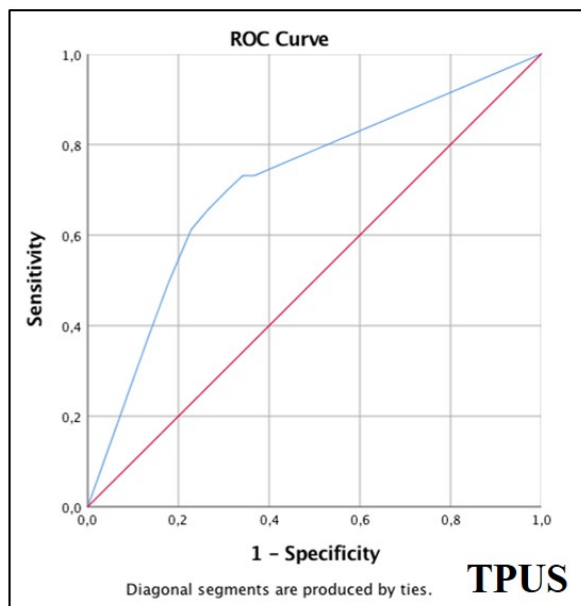
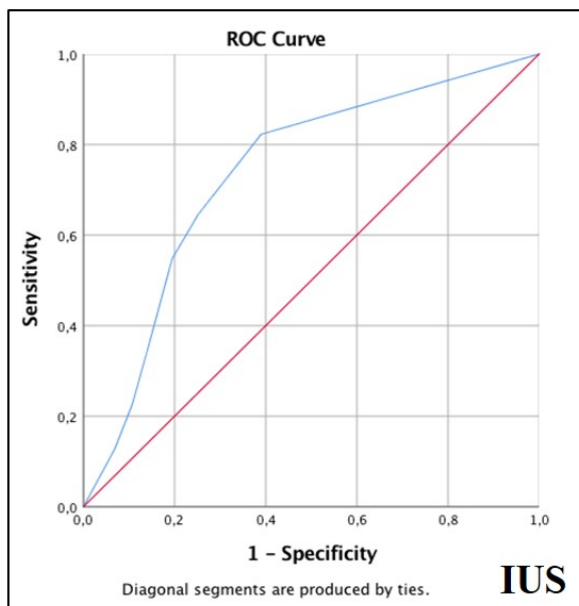
- 489 A. Superficial level of Endoanal ultrasound demonstrating a defect in the external
490 (shown by the angles) (EAS) and internal anal sphincter (shown by the
491 arrows) (IAS).
- 492 B. Superficial level (slice 4) of introital tomographic ultrasound imaging (TUI)
493 demonstrating a defect in the EAS (shown by the angles) and IAS (shown by
494 the arrows).
- 495 C. Superficial level (slice 4) of transperineal TUI demonstrating a defect in the
496 EAS (shown by the angles) and IAS (shown by the arrows).

497 **Figure 3 – Receiver operator characteristic (ROC) curves**

- 498 A. ROC curves for 3D introital tomographic ultrasound imaging (TUI) (left) and
499 3D transperineal TUI (right) for diagnosis of external anal sphincter defects
500 (with inclusion of subcutaneous level).
- 501 B. ROC curves for 3D introital TUI (left) and 3D transperineal TUI (right) for
502 diagnosis of internal anal sphincter defects.



ACCEPTED MANUSCRIPT

A**B**