

Takotsubo Syndrome's Pathophysiology: Still a Mystery?

Francesco Pelliccia^{1,*}, Juan Carlos Kaski², Paolo G. Camici³

¹Sapienza University, Rome, Italy;

²St George's University of London, UK;

³Vita-Salute University and San Raffaele Hospital, Milan, Italy.

Word count: 499 words

References: 3

Numbers of figures: 1

* Corresponding author:

Francesco Pelliccia, MD, PhD,

Sapienza University,

Viale del Policlinico 155, 00166 Rome - IT

E-mail: *f.pelliccia@mclink.it*

The consensus document on takotsubo syndrome (TTS) by Ghadri *et al.*¹ represents an important attempt to increase awareness regarding this intriguing condition. The authors propose newer diagnostic criteria which will hopefully improve the identification and characterization of TTS patients. Differently from earlier proposals, Ghadri *et al.* propose that pheochromocytoma should be considered to represent a cause of TTS, as phaeochromocytoma can trigger a catecholaminergic storm that may result in cardiac abnormalities that are indistinguishable from TTS.¹ We respectfully disagree with their suggestion, as although conditions characterized by excessive catecholamine release such as pheochromocytoma² and neurogenic stunned myocardium³ share some characteristics, they do differ from TTS in their clinical presentation, electrocardiographic changes and pattern of left ventricular wall motion abnormalities. Moreover, in pheochromocytoma, but not TTS, recurrent catecholamine surges lead to histological changes characterised by inflammation, foci of necrosis, and reparative fibrosis which are commonly documented by cardiac magnetic resonance late gadolinium enhancement.² As we recently proposed,³ it might be more appropriate to consider that they represent TTS 'phenocopies'.

Ghadri *et al.*¹ also postulate that the mechanism through which catecholamine excess precipitates myocardial stunning in TTS is "unknown". We disagree, however, that the pathophysiology of TTS is a "mystery". Being a syndrome and not a disease, TTS can be triggered by different mechanisms, as postulated in our recent review.³ Specifically, the increased concentration of catecholamines occurring in the acute phase of TTS can induce direct myocardial injury and/or coronary microvascular vasoconstriction, together with an increased cardiac workload, all of which may contribute to an acute 'supply-demand mismatch' followed by post-ischemic stunning (*Figure 1*).³

Conflict of interest: none declared

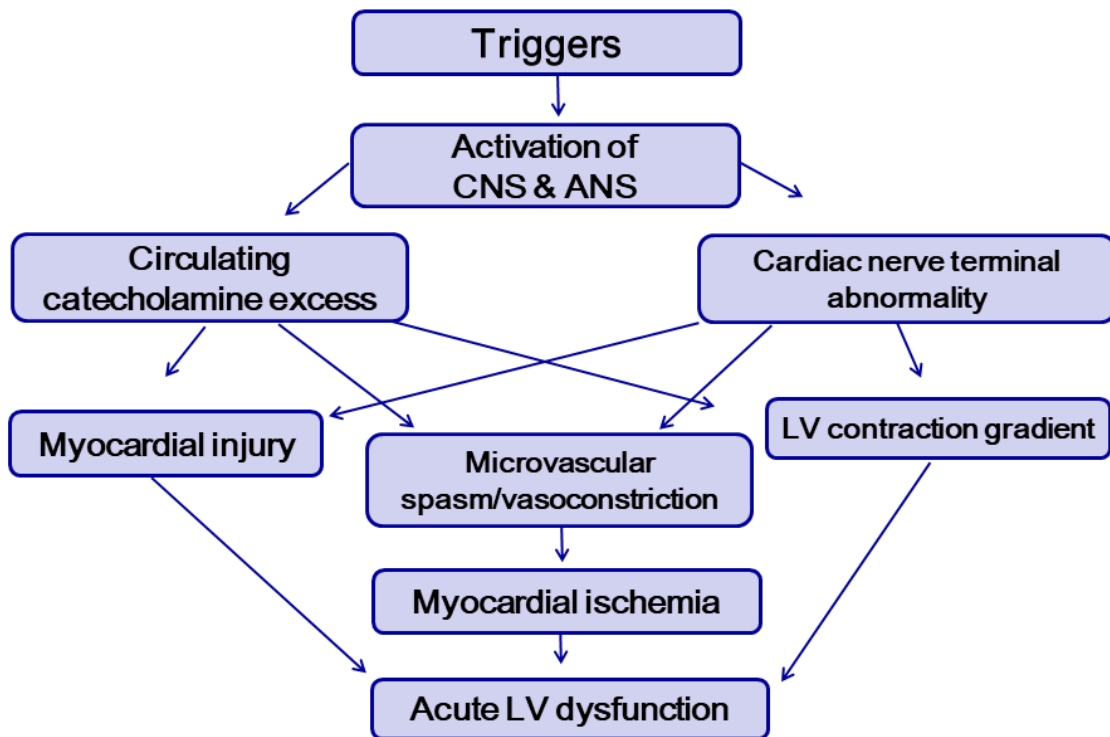
References

1. Ghadri JR, Wittstein IS, Prasad A, Sharkey S, Dote K, Akashi YJ, Cammann VL, Crea F, Galiuto L, Desmet W, Yoshida T, Manfredini R, Eitel I, Kosuge M, Nef HM, Deshmukh A, Lerman A, Bossone E, Citro R, Ueyama T, Corrado D, Kurisu S, Ruschitzka F, Winchester D, Lyon AR, Omerovic E, Bax JJ, Meimoun P, Tarantini G, Rihal C, Y-Hassan S, Migliore F, Horowitz JD, Shimokawa H, Lüscher TF, Templin C. International expert consensus document on takotsubo syndrome (Part I): Clinical characteristics, diagnostic criteria, and pathophysiology. *Eur Heart J* 2018; **39**:2032-2046.
2. Ferreira VM, Marcelino M, Piechnik SK, Marini C, Karamitsos TD, Ntusi NA, Francis JM, Robson MD, Arnold JR, Mihai R, Thomas JD, Herincs M, Hassan-Smith ZK, Greiser A, Arlt W, Korbonits M, Karavitaki N, Grossman AB, Wass JA, Neubauer S. Pheochromocytoma is characterized by catecholamine-mediated myocarditis, focal and diffuse myocardial fibrosis, and myocardial dysfunction. *J Am Coll Cardiol* 2016;**67**:2364-2374.
3. Pelliccia F, Kaski JC, Crea F, Camici PG. Pathophysiology of takotsubo syndrome. *Circulation* 2017; **135**: 2426-2441.

Figure 1 Key pathogenetic aspects in takotsubo syndrome

The picture depicts the interplay among triggers, pathogenetic factors, mechanisms of cardiac injury, and clinical consequences. Current evidences indicate that in the acute phase of TTS there is an increased concentration of catecholamines that might induce direct myocardial injury and coronary spasm/vasoconstriction, mostly at the microvascular level, together with an increased cardiac workload that contribute to an acute situation of 'supply-demand mismatch' followed by post-ischemic stunning.

ANS, autonomic nervous system; CNS, central nervous system; LV, left ventricular.



Takotsubo Syndrome's Pathophysiology: Still a Mystery?

Francesco Pelliccia^{1,*}, Juan Carlos Kaski², Paolo G. Camici³

¹Sapienza University, Rome, Italy;

²St George's University of London, UK;

³Vita-Salute University and San Raffaele Hospital, Milan, Italy.

Word count: 499 words

References: 3

Numbers of figures: 1

* Corresponding author:

Francesco Pelliccia, MD, PhD,

Sapienza University,

Viale del Policlinico 155, 00166 Rome - IT

E-mail: *f.pelliccia@mclink.it*

DIPARTIMENTO DI SCIENZE CARDIOVASCOLARI
RESPIRATORIE NEFROLOGICHE
ANESTESIOLOGICHE E GERIATRICHE



SAPIENZA
UNIVERSITÀ DI ROMA

Professor Thomas F. Lüscher,
Editor-in-chief,
European Heart Journal

September 30, 2018

Re: Takotsubo Syndrome's Pathophysiology: Still a Mystery?

Permissions Information:

“The authors do hereby declare that all illustrations and figures in the manuscript are entirely original and do not require reprint permission.”

Francesco Pelliccia, MD, PhD, on behalf of all authors

Takotsubo Syndrome's Pathophysiology: Still a Mystery?**ABSTRACT**

The authors of the consensus document on takotsubo syndrome (TTS) recently published in the European Heart Journal propose newer diagnostic criteria in an attempt to improve the identification and characterization of TTS patients. Of note, pheochromocytoma has been included among the causes of TTS. This is in contrast with multiple studies indicating that pheochromocytoma differs from TTS in clinical presentation, electrocardiographic changes, type of left ventricular wall motion abnormalities, and findings at cardiac magnetic resonance imaging.

Also, the authors postulate that the mechanism through which catecholamine excess precipitates myocardial stunning in TTS is "unknown". However, the pathophysiology of TTS should not be considered a mystery, as it has recently recognised that the increased concentration of catecholamine occurring in the acute phase of TTS can induce both direct myocardial injury and coronary microvascular vasoconstriction together with an increased cardiac workload that contribute further to an acute situation of 'supply-demand mismatch' followed by post-ischemic stunning.