

Accepted Manuscript

Safety, accuracy, and cost effectiveness of bedside bolt external ventricular drains (EVDs) in comparison to tunnelled EVDs inserted in theatres

Joy Roach, Benjamin Gaastra, Diederik Bulters, Anan Shtaya



PII: S1878-8750(19)30204-9

DOI: <https://doi.org/10.1016/j.wneu.2019.01.106>

Reference: WNEU 11279

To appear in: *World Neurosurgery*

Received Date: 29 November 2018

Revised Date: 13 January 2019

Accepted Date: 14 January 2019

Please cite this article as: Roach J, Gaastra B, Bulters D, Shtaya A, Safety, accuracy, and cost effectiveness of bedside bolt external ventricular drains (EVDs) in comparison to tunnelled EVDs inserted in theatres, *World Neurosurgery* (2019), doi: <https://doi.org/10.1016/j.wneu.2019.01.106>.

This is a PDF file of an unedited manuscript that has been accepted for publication. As a service to our customers we are providing this early version of the manuscript. The manuscript will undergo copyediting, typesetting, and review of the resulting proof before it is published in its final form. Please note that during the production process errors may be discovered which could affect the content, and all legal disclaimers that apply to the journal pertain.

Safety, accuracy, and cost effectiveness of bedside bolt external ventricular drains (EVDs) in comparison to tunnelled EVDs inserted in theatres

Joy Roach¹, Benjamin Gaastra¹, Diederik Bulters¹ and Anan Shtaya^{1,2}

¹Wessex Neurological Centre, University Hospital Southampton, Southampton, UK.

²Neurosciences Research Centre, Molecular and Clinical Sciences Research Institute, St George's, University of London and St George's University Hospital NHS Trust, London, UK.

Corresponding author:

Anan Shtaya

St George's, University of London, London, SW17 0RE, UK

E-mail ashtaya@sgul.ac.uk.

Tel: 020 8725 5120

Conflict of interest:

All authors have none to declare.

Funding:

This study was completed with lack of dedicated funding.

We acknowledge NIHR lectureship to Mr Shtaya.

Title word count: 20

Number of figures: 3

Number of tables: 5

Number of references: 15

Manuscript Word count: 3238

Abstract

Objective: External ventricular drain (EVD) placement is frequently required in neurosurgical patients to divert CSF and monitor intracranial pressure. The usual practise is the tunnelled EVD technique performed in operating theatres. EVD insertion through a bolt in intensive care is also described. We employ both practices in our institute. Herein, we compare the indications, accuracy, safety and costs of the two techniques.

Methods: Retrospective cohort study of a prospectively maintained EVD data-base of all patients undergoing first frontal EVD placement between Jan 2010-Dec 2015. Those with preceding CSF infection were excluded. We compared bolt EVD with tunnelled EVD techniques in terms of accuracy of EVD tip location by analysing CT scans to grade catheter tip location as optimal (ipsilateral frontal horn) or otherwise suboptimal, and complications that include infection and revision rates.

Results: 579 eligible patients aged 3 months to 84 years were identified. 430 had tunnelled EVDs and 149 bolt EVDs. The most frequent diagnosis was intracranial haemorrhage (73% bolt vs 50.4% tunnelled group ($p<0.001$)). Other diagnoses included tumour (4.7% bolt vs 19.1% tunnelled ($p<0.001$)), traumatic brain injury (17.5% bolt vs 17.4% tunnelled). In the bolt EVD group 66.4% of EVD tips were optimal, compared to 61.0% in the tunnelled group ($p=0.33$). Infection was confirmed in 15 (10.0%) bolt EVDs compared to 61 (14.2%) tunnelled EVDs ($p=0.2$). Each bolt EVD kit costs £260 while placing a tunnelled one in theatre costs £1316.

Conclusions: Bedside bolt EVD placement is safe, accurate and cost effective in selective patients with haemorrhage related hydrocephalus.

Keywords: External ventricular drain (EVD), hydrocephalus, CSF, bolt, tunnelled.

Introduction:

External ventricular drain (EVD) placement is frequently required in neurosurgical patients to alleviate symptoms associated with hydrocephalus, to monitor and manage raised intracranial pressure and to deliver intrathecal medication.^{1,2} The standard practice in the United Kingdom is the tunnelled EVD technique performed in the operating theatre.³ This is performed by drilling a burr hole, passing a catheter into the lateral ventricle, and then tunnelling the catheter under the skin before bringing it out and into a collection bag. However, EVD insertion through a bolt at the bedside in intensive care and the emergency department is also described^{4,5}. A hole is made in the skull with a twist drill and a hollow bolt screwed into place providing access for a ventricular catheter to pass through.

Studies in the last few years from a number of European and American institutes have investigated safety, accuracy and infection rates of bolt EVD placement^{2,4-8} as well as tunnelled EVD in intensive care units.⁸ However, bolt EVD technique outside operating theatres is not common practice in the UK. In a recent UK national study of 495 EVDs, while 98.6% of EVDs were placed in theatres, our neurosurgery institute was the only one reporting bolt EVD insertion in intensive care unit among the UK centres participated in this study.³ We therefore set out to compare the safety, accuracy, practicality and costs of inserting bolt EVD versus the standard tunnelled technique in a busy tertiary neurosurgery centre.

Methods

This retrospective cohort study of our prospectively maintained EVD database is registered as an audit with institutional approval. Patients that had an EVD inserted between 1st January 2010 and 31st December 2015 were identified from our EVD database. Case ascertainment was further confirmed via a search through our audit department coding system for EVDs. A retrospective case note review was performed looking through each patient's paper and

electronic records. Data was collected on the patient demographics, the procedural details including the location and length of the procedure, the grade of the surgeon, the number of catheter passes, details of any CSF microbiology samples taken and their culture results. Our local imaging system was used to review each patients' post EVD insertion CT or MRI scan to identify the EVD tip position which was classified into ipsilateral frontal horn, contralateral frontal horn, ipsilateral body, third ventricle, basal cisterns or in the brain parenchyma. EVD catheter tip position was considered optimal if in the ipsilateral frontal horn as described previously¹. In the patients that had more than one EVD placed during their admission only the first EVD placement was included in the data analysis. Patients who had no post EVD insertion CT or MRI scan and those with occipital EVDs were excluded from the analysis. Patients with evidence of a preceding CSF infection and those placed at the time of craniotomy for management of their underlying condition, for example an EVD placed during clipping of an aneurysm for a subarachnoid haemorrhage or insertion of an EVD at the time of cranioplasty were also excluded.

Data of the catheter tip position is available for 107 bolt EVDs and 269 tunnelled EVDs. Some of the tunnelled EVDs were inserted under image guidance (IGS) versus none in the bolt EVDs group. Therefore, we additionally performed a subgroup analysis of the data excluding the tunnelled EVDs that were placed with IGS leaving 184 tunnelled EVDs compared to 107 bolt EVDs. To determine the accuracy of the EVD tip position the post procedure CT/MRI scans of the brain were reviewed by the last author who was blinded to radiology reports and outcomes using the Hospital SECTRA system (Sectra Imaging IT Solutions AB, Sweden) and EVD tip position was counter checked against the independent Neuroradiology report.

Tunnelled EVD insertion technique

In our institute EVD insertion procedures are performed in the operating theatre using standard tunnelled EVD catheters, predominantly silver impregnated catheters (Silverline, Spiegelberg) but some antibiotic impregnated and plain silicone catheters were also included in the study upon the discretion of the surgeon. We initially studied EVD tip position accuracy for tunnelled EVDs in comparison with bolt EVDs. However, image guidance (IGS) is used when inserting selected tunnelled EVDs in theatres when feasible particularly in patients with small ventricles,¹ but not for bolt EVDs. Therefore, to minimise bias, we subsequently analysed EVD tip position excluding IGS inserted EVDs as none of the bolt EVDs were inserted with image guidance due to non-compatible equipment. This allows comparing free hand insertion techniques only for both groups. The standard surgical procedure includes routine skin preparation and draping, with the head in a neutral position, a 3-cm skin incision is made over the Kocher point (2.5 cm from midline and 1 cm anterior to the coronal suture) or frontally 10 cm above the supra-orbital ridge (mid-pupillary line) and 2.5 cm from the midline. A burr hole is fashioned using a Stryker disposable perforator (14 mm) (Stryker, Miami, Florida), After opening the dura the stylet-loaded ventricular catheter is introduced perpendicular to the skull aimed at the ipsilateral medial epicanthus in the coronal plane and just anterior to the external auditory meatus in the sagittal plane. The target is the ipsilateral anterior horn of the lateral ventricle close to the foramen of Monro with maximum length of intracranial EVD catheter of 6 cm from the cortical surface. Free flow of CSF confirms successful placement. The distal end of the ventricular catheter is then tunnelled subcutaneously and the skin closed with the catheter secured to the skin using the flange and silk sutures to avoid postoperative unintentional pull-out. The distal end of the catheter is then attached to a closed external drainage and monitoring system (Integra, USA). Figure 1 shows how the tunnelled EVD appears on the scout image of a CT head.

Bolt EVD Insertion Technique

We are able to insert bolt EVD's (Camino bolt-EVD kit (Integra, USA)) in the emergency department and on the neuro and general intensive care units. The decision whether to place a bolt EVD on intensive care is based on surgeon preference and is generally limited to patients with larger ventricles, those needing more urgent CSF diversion, and in patients with haemodynamic instability making transfer to the operating theatre more difficult. With regards to the procedure itself the patient position and the anatomical landmarks used are identical to the tunnelled technique. The differences being a shorter incision and the burr hole fashioned with a hand held twist drill. As with all invasive procedures, meticulous sterile skin preparation and draping are employed, and masks, gowns and sterile gloves are used as standard. After successful EVD placement the bolt is screwed tightly to the skull and if necessary the incision is sutured either side of the bolt and the bolt is wrapped with a betadine soaked swab. The connection system is identical to the tunnelled technique with the addition of an extra lead for ICP monitoring from the bolt EVD system. Figure 2 shows how a bolt EVD appears on a scout image for a CT head.

Statistical analysis

Statistical analysis was performed using Chi-square and Student's t test when comparing bolt EVD data with tunnelled EVDs as specified in the tables using GraphPad Prism (GraphPad Software, Inc.) as appropriate and detailed in results. Significance was set at $p < 0.05$.

Results

Patient Demographics

A total of 674 patients with 690 EVDs underwent first EVD insertion procedures between January 2010 and December 2015. After excluding those with occipital EVDs, a second (re-inserted) EVD, patients with preceding CSF infection and EVD placement at the time of craniotomy a total of 579 EVDs remained. Out of the 579, 430 (74%) had tunnelled EVDs and 149 (26%) were bolt EVDs. The age range was from 3 months to 84 years with a mean

age of 45.6 ± 1.1 years in the tunnelled group and 56.3 ± 1.2 years in the bolt EVD group. After exclusions (patients with no post-operative scans), we were left with 107 bolt EVDs versus 269 tunnelled EVDs.

Indication for EVD

The indications for EVD insertion are listed in Table 1.

EVD tip position

Firstly, we analysed the EVDs tip position accuracy for all included EVDs. In the bolt EVD group 66.4% of EVD tips were in an optimal position, compared to 61.0% in the tunnelled group ($p=0.33$, Chi square 0.95) Table 2. After excluding the tunnelled EVDs inserted with IGS, the bolt EVDs group the catheter tip accuracy results remained the same (66.4%), while in the tunnelled group 114 (61.9%) out of 184 catheter tip position were optimal with no significant difference between the two groups ($p=0.45$, Chi square 0.56). Since the most common pathology was SAH/ICH/IVH we further analysed the EVD tip accuracy according to this pathology. There were 79 cases in the bolt EVD group versus 97 in the tunnelled EVD group. 55 (69.6%) were graded as having EVD optimal tip position (ipsilateral frontal horn) in the bolt EVDs group versus 72 (74.2%) with no significant difference between groups ($p=0.5$ and Chi square 0.5).

Data was also collected on the number of passes required for successful EVD placement and the grade of the surgeon performing the procedure. For bolt EVDs, in 85.2% of cases the number of catheter insertion attempts data was available in comparison to only 27% in the tunnelled group ($p<0.001$). We have analysed the available data which revealed significantly higher percentage of first successful passes of the EVD catheters in the bolt EVD group (50.3%) when compared to 23.2% in the tunnelled group ($p<0.001$, Chi square 38.5) Table 3. We classified the grade of the surgeon according to their experience as those neurosurgical trainees with 1-3 years of experience in neurosurgery (ST1-3), neurosurgical trainees with 4-

8 years of experience in neurosurgery (ST4-8), and consultants. Some bolt EVDs were inserted by senior neuro intensive care technicians. 49.0% of bolt EVDs and 32.5% of the tunnelled EVDs were inserted by ST1-3 trainees ($p < 0.001$, Chi square 12.9) Table 4. ST4-8 trainees inserted 51.4% of the tunnelled EVDs vs 32.2% of the bolt EVDs, $p < 0.001$, Chi square 16.4). Consultants placed 14% of the tunnelled EVDs compared to only 2% of the bolt EVDs ($p < 0.001$, Chi square 16.3).

We further analysed the optimal EVD tip position according to operator and the results are presented in table 5. In summary there was no difference in the percentage of optimally placed EVDs when comparing equivalent level of training for both procedures. There were more tunnelled EVDs placed by consultants. Neuro intensive care technicians inserted only bolt EVDs.

Complications

CSF was sampled from 416 tunnelled EVDs and 138 of the bolt EVDs. Infection was confirmed with positive culture results in 15 (10%) of bolt EVDs compared to 61 (14.2%) of tunnelled EVDs ($p = 0.26$, Chi square is 1.2). There was a rise in white cell counts in CSF samples from one bolt EVD and 9 tunnelled EVDs with no positive cultures. We examined how long the EVD remained in situ. Data is available for 370 tunnelled EVDs versus 132 bolt EVDs. The average period tunnelled EVDs were in situ was 8.1 ± 0.35 days versus 8.5 ± 0.62 days for bolt EVDs ($p = 0.6$, students' t test). The numbers of EVD catheters that required replacement, for causes other than infection, in the bolt EVD group was 5 (3.4%) and 13 (3%) in the tunnelled EVD group ($p = 0.84$, Chi square is 0.04). The reasons for replacement included catheter blockage, failure to drain CSF and EVDs falling out/being pulled out. The numbers are too small to subgroup and perform any meaningful statistical analysis.

Cost

The costs were estimated using NHS costings in our hospital at the time of the data collection. For the bolt EVD inserted in neuro or general intensive care units the total cost for placement is £260 (1 British pound is approximately 1.29 USA dollar) excluding the cost of the operating surgeon while the average cost of placing a tunnelled EVD in theatre is estimated as £1316. The bolt EVD kit includes the bolt with an EVD plain catheter, hand held drill (see picture Figure 3), an anaesthetic pack with gauze, a blade, syringes and the EVD drainage set £1316 includes the cost of the kit used for a tunnelled EVD and the cost of the operating theatre occupancy. The theatre occupancy time was recorded from theatre books and electronic records. The time recorded was from the time the patient was transferred from the anaesthetic room into the operating theatre to the time the procedure ended which excluded any anaesthetic and patient recovery time. The mean theatre occupancy time for placing an EVD was 61 ± 7.5 minutes. The average cost of theatre occupancy is £18 per minute, the silver line catheter is £153 and the drainage kit costs £83 totalling £1316. These costs exclude the cost of any additional arrangements required to transfer the patients from neuro intensive care to theatres and vice versa.

Discussion

In the current study, we demonstrate that external ventricular drain insertion through bolt at the bedside is safe procedure when compared to the standard tunnelled EVD insertion technique in theatres. These results are in agreement with the practise of other European institutes'.²

We employ both practices of EVD insertion depending on a number of factors including the time critical nature of the situation, theatre availability and the size of the ventricles. EVD placement is often considered as a simple procedure despite its inherent risks of haemorrhage, infection and misplacement. Traditionally anatomical surface landmarks have been used to guide placement of a freehand EVD into the ipsilateral frontal horn but the use of image

guidance to improve accuracy of placement and reduce reoperation rates due to suboptimal placement has become commonplace¹. Freehand placement is still used for bolt EVDs as our equipment did not allow for navigation of bolt EVDs during the audit period studied.

One disadvantage of the bolt EVD is that the trajectory of the EVD catheter is determined by the location and direction of the burr hole and therefore if the ventricle is not punctured in the first pass it is unlikely to be successful on the remaining passes unless the burr hole and therefore trajectory is changed. The number of EVD catheter passes from first attempt is significantly higher in bolt EVDs. This may be related to the small burr hole that initially placed and inability to change the catheter trajectory once in place which results in just one attempt policy. There are a handful of bolt EVDs in the whole series that required conversion to tunnelled EVDs in theatre for this reason.

In order to scrutinise the EVD tip accuracy data we further analysed the tip position accuracy by comparing haemorrhage related pathology as an underlying cause of hydrocephalus requiring an EVD with no significant difference. These results further confirm that both procedures are similar in EVD tip position accuracy. There is no significant difference in the EVDs tip position accuracy according to the training level of the surgeon.

Complications following inserting EVDs are well known and include CSF infection/ventriculitis, brain haemorrhage, catheter malposition, blockage and fall out that require replacement.¹⁻¹² Our infection rates are comparable with other studies.^{3,11} Factors that may be considered when studying infections post EVD insertion include the type of the ventricular catheters used, prophylactic antibiotic administration, and theatre air flow. The tunnelled EVDs placed were mainly silver line catheters which have been reported to reduce CSF infection¹¹. Bolt EVD catheters were only available in plain silicone during the period of this study. Our local protocol is to give cefuroxime 1.5 grams or vancomycin with gentamicin for penicillin allergic patients at the time of anaesthetic induction but this only occurs when

there is an anaesthetist present in the operating theatres and therefore only tunnelled EVDs placed in theatre routinely received prophylactic antibiotics. In addition, the operating theatres are designed with laminar air flow ventilation systems that have been proven to reduce bacterial and particulate contamination of air.¹³ Despite these factors potentially biasing the tunnelled group towards better outcomes, the infection rates were similar with the two techniques.

In the UK, EVDs are usually inserted in theatres and are tunnelled hence we used “the standard care” in our paper. This reflects the common practise and does not imply specific body or ethical guidelines. In fact, other European units may insert bolt EVDs in theatres and not at bedside.^{2,14} The majority of EVDs in Europe are placed in theatres.¹⁵ The literature is scarce of studies detailing tunnelled EVD placement outside the operating room settings. Bedside EVDs may will be standard in the USA and part of them may will be tunnelled,⁸ the literature is lacking of studies describing cost effectiveness of tunnelled EVDs inserted at bedside. Certainly we do not place tunnelled EVDs at bedside in our neurosurgery institute and, to our knowledge, no other institutes in the UK do. To our knowledge, no published studies comparing tunnelled EVD insertion with bolt EVD placement at bedside.

Our study also highlights important practical and economic factors when placing bolt EVD. We show that bolt EVDs are associated with lower costs for similar outcomes. We estimate the cost savings from use of the tunnelled EVDs during the study period was of the order of £200,000. Furthermore, usually EVDs are placed in emergency settings rather than on an elective basis and therefore in addition to the cost savings there are substantial improvements to patient experience by avoiding cancellation of other operations to make way for emergency EVD placement. In addition, tracing intracranial pressure (ICP) using the bolt EVD probe is possible at no additional costs. This is important mainly in traumatic brain injury patients where ICP monitoring is an essential part of the treatment.

Limitations

These results come with the limitations of a retrospective study. There were more haemorrhage related cases in the bolt EVDs group. This may result in bias when analysing the EVD catheter tip position as ventricles likely to be large. We have attempted to correct for selection bias by comparing haemorrhage related bolt EVDs with tunnelled EVDs due to haemorrhage and there was no significant difference in EVD catheter tip position accuracy or revision rates.

Missing data also limited some analyses. For example since the theatre time was not available for all cases included, we noted variability in theatre occupancies, which may be related to the operator and other factors that are beyond the scope of this paper. Although the time estimated to place a bolt EVD is much less than half an hour, unfortunately we do not have any accurate recordings as these procedures were performed on intensive care units and not in theatres. Due to the missing data, we followed our local protocol which is inserting silver line catheter in all tunnelled EVDs in theatres which in our interpretation.

Conclusion

This consecutive series from a busy tertiary neurosurgical unit showed no difference in the safety or accuracy in EVD placement via a bolt or tunnelled techniques. The selection of technique was not entirely random and subject to bias. It is therefore not possible to generalise across all EVD cases. It would appear to be most applicable to haemorrhage related hydrocephalus and patients with larger ventricles. Further data in patients with traumatic brain haemorrhage and smaller ventricles, and using navigated bolt EVD's are necessary to draw conclusions for the whole population of patients requiring EVD placement. Overall, our results demonstrate that insertion of bolt EVDs outside the operating room is safe, accurate, and practical. The role of bolt EVDs is more pronounced in the acute setting when placement is time critical, in patients with large ventricles, or when patient instability

make transfer to theatre undesirable. It is more cost effective than tunnelled EVD placement in theatre and should be considered in selected patients.

References

1. Shtaya A, Roach J, Sadek AR, Gaastra B, Hempenstall J, Bulters D. Image guidance and improved accuracy of external ventricular drain tip position particularly in patients with small ventricles. *J Neurosurg*. 2018;1-6.
2. Jensen TS, Carlsen JG, Sorensen JC, Poulsen FR. Fewer complications with bolt-connected than tunneled external ventricular drainage. *Acta Neurochir (Wien)*. 2016;158(8):1491-1494.
3. Jamjoom AAB, Joannides AJ, Poon MT, et al. Prospective, multicentre study of external ventricular drainage-related infections in the UK and Ireland. *J Neurol Neurosurg Psychiatry*. 2018;89(2):120-126.
4. Fichtner J, Jilch A, Stieglitz LH, Beck J, Raabe A, WJ ZG. Infection rate of emergency bolt-kit vs. non-emergency conventional implanted silver bearing external ventricular drainage catheters. *Clin Neurol Neurosurg*. 2014;122:70-76.
5. Bergdal O, Springborg JB, Holst AV, et al. Accuracy of tunnelated vs. bolt-connected external ventricular drains. *Clin Neurol Neurosurg*. 2013;115(10):1972-1975.
6. Schodel P, Proescholdt M, Ullrich OW, Brawanski A, Schebesch KM. An outcome analysis of two different procedures of burr-hole trephine and external ventricular drainage in acute hydrocephalus. *J Clin Neurosci*. 2012;19(2):267-270.
7. Schodel P, Proescholdt M, Brawanski A, Bele S, Schebesch KM. Ventriculostomy for acute hydrocephalus in critically ill patients on the ICU--outcome analysis of two different procedures. *Br J Neurosurg*. 2012;26(2):227-230.
8. Roitberg BZ, Khan N, Alp MS, Hersonskey T, Charbel FT, Ausman JI. Bedside external ventricular drain placement for the treatment of acute hydrocephalus. *Br J Neurosurg*. 2001;15(4):324-327.
9. Foreman PM, Hendrix P, Griessenauer CJ, Schmalz PG, Harrigan MR. External ventricular drain placement in the intensive care unit versus operating room: evaluation of complications and accuracy. *Clin Neurol Neurosurg*. 2015;128:94-100.
10. Toma AK, Camp S, Watkins LD, Grieve J, Kitchen ND. External ventricular drain insertion accuracy: is there a need for change in practice? *Neurosurgery*. 2009;65(6):1197-1200; discussion 1200-1191.
11. Keong NC, Bulters DO, Richards HK, et al. The SILVER (Silver Impregnated Line Versus EVD Randomized trial): a double-blind, prospective, randomized, controlled trial of an intervention to reduce the rate of external ventricular drain infection. *Neurosurgery*. 2012;71(2):394-403; discussion 403-394.
12. Nowacki A, Wagner F, Soll N, et al. Preliminary Results of Emergency Computed Tomography-Guided Ventricular Drain Placement-Precision for the Most Difficult Cases. *World Neurosurg*. 2018;114:e1290-e1296.
13. James M, Khan WS, Nannaparaju MR, Bhamra JS, Morgan-Jones R. Current Evidence for the Use of Laminar Flow in Reducing Infection Rates in Total Joint Arthroplasty. *Open Orthop J*. 2015;9:495-498.
14. Asaad SK, Bjarkam CR. The Aalborg Bolt-Connected Drain (ABCD) study: a prospective comparison of tunnelled and bolt-connected external ventricular drains. *Acta Neurochir (Wien)*. 2018.

15. Cinibulak Z, Aschoff A, Apedjinou A, Kaminsky J, Trost HA, Krauss JK. Current practice of external ventricular drainage: a survey among neurosurgical departments in Germany. *Acta Neurochir (Wien)*. 2016;158(5):847-853.

Figure/tables legends

Figure 1: Illustrative scout CT head of a patient with tunnelled EVD. Arrow demonstrates the intracranial part of the EVD catheter.

Figure 2: Illustrative scout CT head of a patient with bolt EVD. Arrow demonstrates part of the extracranial EVD catheter.

Figure 3: The bolt EVD kit.

Table 1: Underlying pathology of the bolt EVD and tunnelled EVD groups. TBI: traumatic brain injury. SAH: subarachnoid haemorrhage. ICH: intracerebral haemorrhage. IVH: intraventricular haemorrhage.

Table 2: EVDs tip position for the unmatched tunnelled versus bolt EVD groups.

Table 3: The number of EVDs catheter passes in the matched groups.

Table 4: Level of surgeon performed the procedure in the two groups.

Table 5: EVD catheter tip position accuracy according to the level of surgeon performed the procedure.

Table 1. Underlying pathology for Bolt-EVD vs Tunnelled-EVD groups						
	Bolt-EVDs		Tunnelled-EVDs		P value	Chi-square
Pathology	Number	%	Number	%		
SAH/ICH/IVH	109	73	217	50.4	***<0.001	23.2
Tumour	7	4.7	82	19.1	***<0.001	17.6
TBI	26	17.5	75	17.4	0.99	0
Shunt malfunction	0	0	16	3.7	n/a	
Ischaemic stroke	2	1.3	11	2.6	0.39	0.75
Other	5	3.4	29	6.8	0.13	2.3

		Bolt-EVDs		Tunnelled-EVDs		P value	Chi-square
	Location	Number	%	Number	%		
Optimal	Ipsilateral frontal horn	71	66.3	164	61	0.33	0.95
Suboptimal	Ipsilateral body of ventricle	12	11.2	40	14.9		
	Third ventricle	10	9.4	26	9.7		
	Contralateral frontal horn	8	7.5	22	8.2		
	Basal cisterns	0	0	2	0.7		
	Parenchyma	6	5.6	15	5.5		
	Total	107	100	269	100		

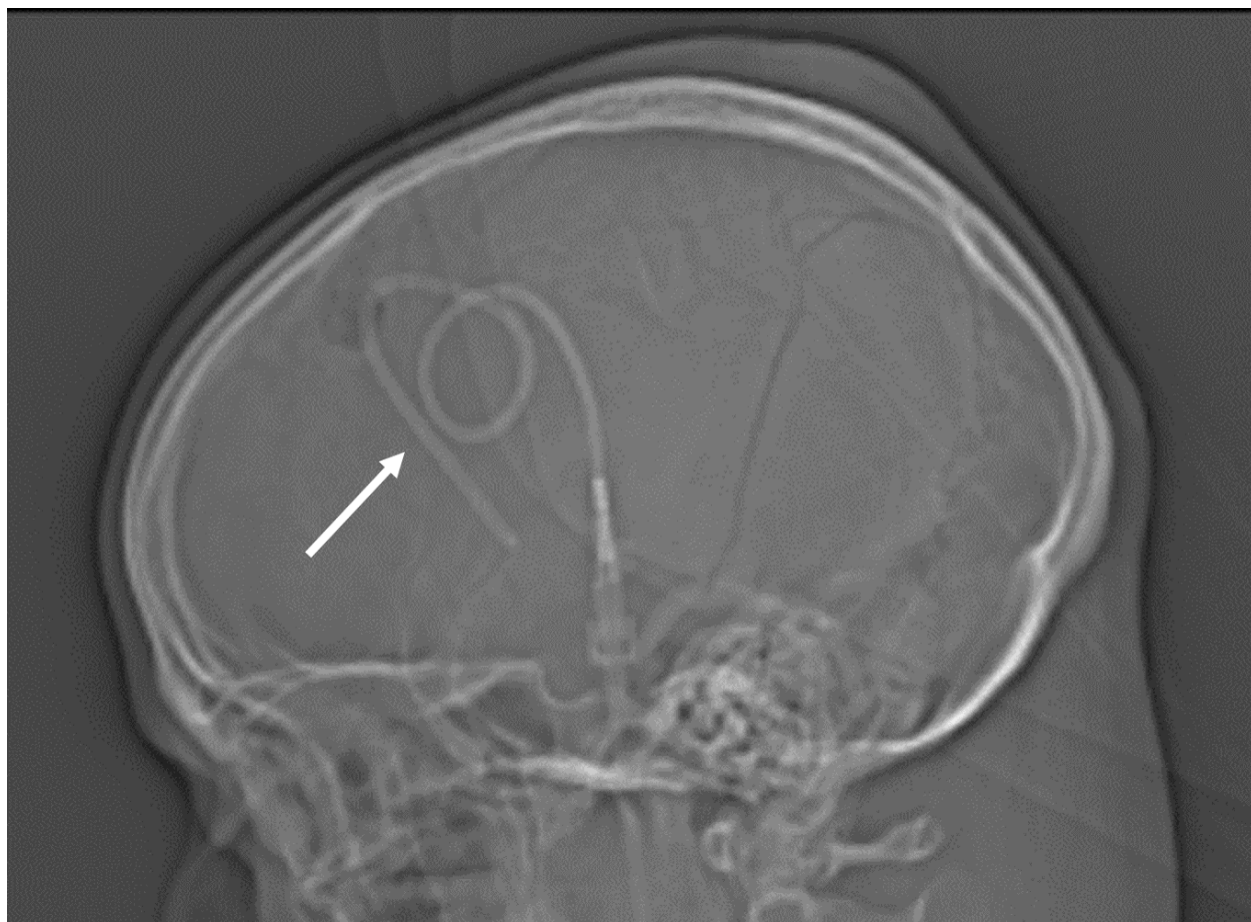
Table 3. Comparison of the number of EVD catheter passes between the two groups

Number of Passes	Bolt EVDs (%)	Tunnelled EVDs (%)	P value	Chi Square
1	75(50.3)	100 (23.2%)	***<0.001	38.5
2	37 (24.8)	12 (2.8)	***<0.001	69.4
3	12 (8.1)	1(0.2)	***<0.001	30.8
4	2 (1.3)	1(0.2)	0.1	2.6
5	0	1(0.2)	n/a	n/a
≥6	1 (0.7)	2 (0.4)	0.1	2.6
Unknown	22 (14.8)	313 (73)	***<0.001	152.8

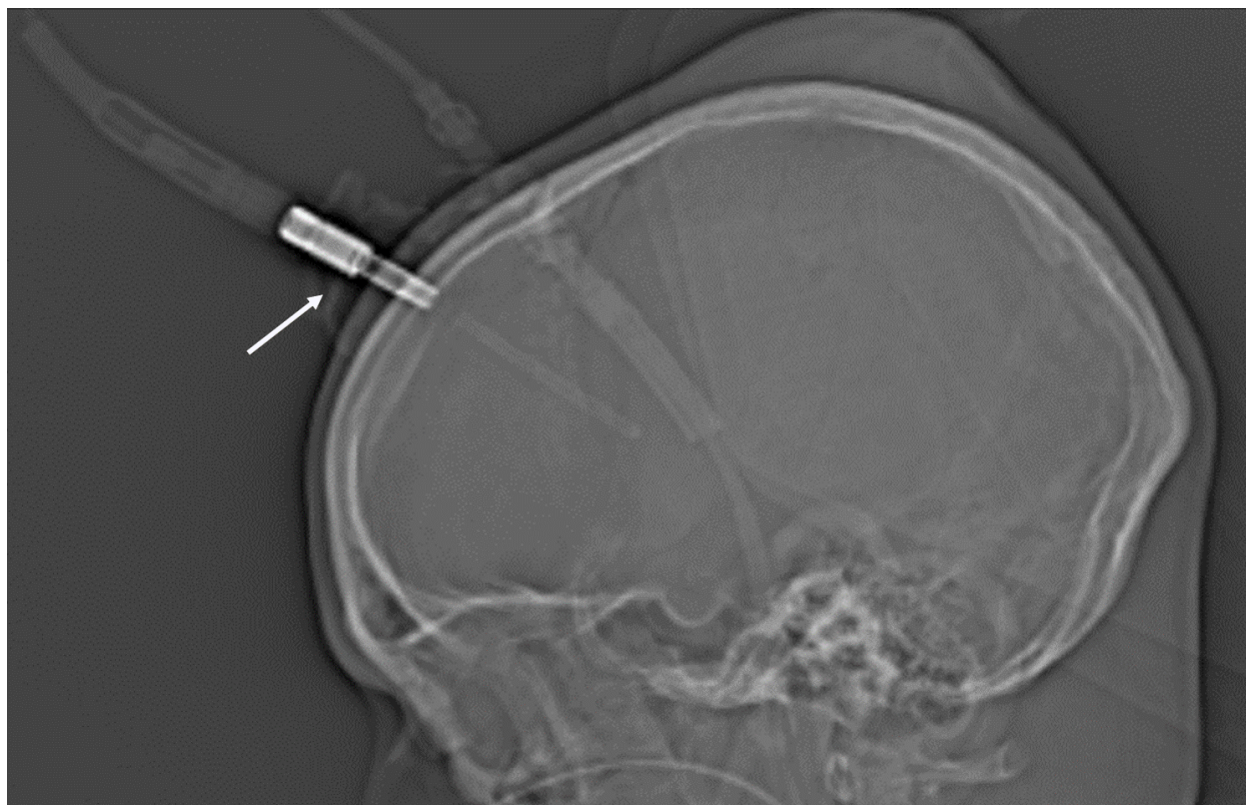Level of the surgeon	Bolt EVDs (%)	Tunnelled (%)	P value	Chi Square
ST1-3	73 (49%)	140 (32.5)	***<0.001	12.9
ST4-8	48 (32.2%)	221 (51.4%)	***<0.001	16.4
Consultant	3 (2%)	60 (14%)	***<0.001	16.3
Neuro technicians	12 (8.1%)	0	n/a	n/a
Unknown	13 (8.7%)	9 (2.1%)		

Table 5. Optimal EVD tip position by operator

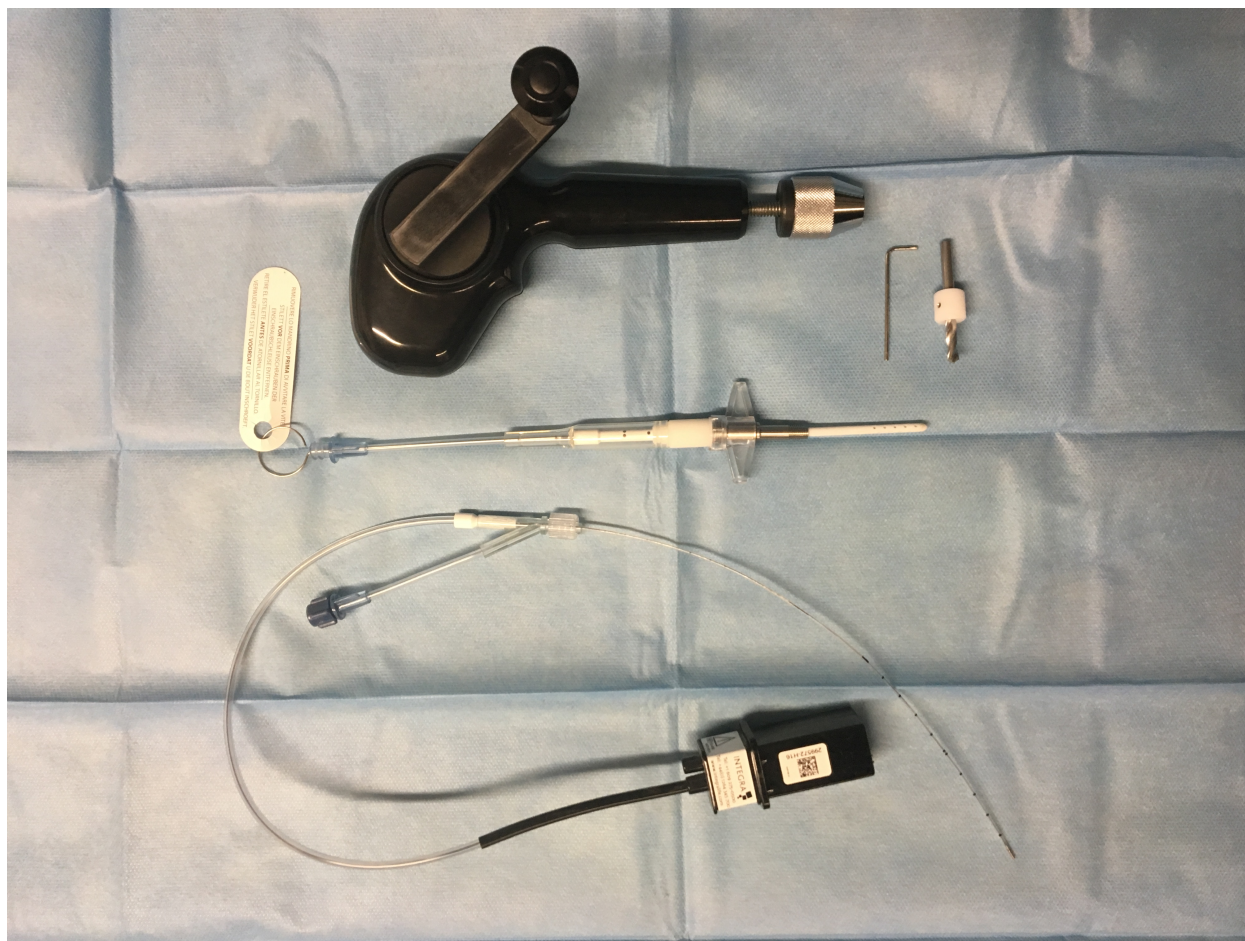Level of the surgeon	Bolt EVDs (%)	Tunnelled (%)	P value	Chi Square
ST1-3	33 (46.5)	69 (42)	0.53	0.4
ST4-8	28 (39.4)	76 (46.3)	0.33	0.96
Consultant	1 (1.4)	15 (9.1)	*0.03	4.7
Neuro technicians	6 (8.5)	0	n/a	n/a
Unknown	3 (4.2)	4 (2.4)		
Total	71(100)	164		



ACCEPTED



ACCEPTED MANUSCRIPT



ACCEPTED

Abbreviation:

External ventricular drain: EVD

Cerebral spinal fluid: CSF

Computed tomography: CT

Magnetic resonance imaging: MRI

Image guidance: IGS

Intracranial pressure: ICP

Subarachnoid haemorrhage: SAH

Intracerebral haemorrhage: ICH

Intraventricular haemorrhage: IVH