10.1161/CIRCULATIONAHA.118.037230

Sudden Death and Left Ventricular Involvement in Arrhythmogenic Cardiomyopathy

Running Title: *Miles et al.; Sudden Death in Arrhythmogenic Cardiomyopathy*

Chris Miles, et al.

The full author list is available on page 18.

Address for Correspondence:
Elijah R. Behr, MA, MBBS, MD
Cardiology Clinical Academic Group
St George's University Hospitals' NHS Foundation Trust and Molecular and Clinical Sciences Institute, St George's University of London
Cranmer Terrace, London SW17 0RE, United Kingdom
Tel: +44 2087252994
Fax: +44 2087253416
Email: ebehr@sgul.ac.uk

Downloaded from http://ahajournals.org by on February 7, 2019

Abstract

Background: Arrhythmogenic cardiomyopathy (ACM) is an inherited heart muscle disorder characterized by myocardial fibro-fatty replacement and an increased risk of sudden cardiac death (SCD). Originally described as a right ventricular (RV) disease, ACM is increasingly recognized as a biventricular entity. We evaluated pathological, genetic, and clinical associations in a large SCD cohort.

Methods: We investigated 5205 consecutive cases of SCD referred to a national cardiac pathology center between 1994 and 2018. Hearts and tissue blocks were examined by expert cardiac pathologists. Following comprehensive histological evaluation, 202 cases (4%) were diagnosed with ACM. Of these, 15 (7%) were diagnosed ante-mortem with dilated cardiomyopathy (DCM)(n=8) or ACM (n=7). Prior symptoms, medical history, circumstances of death, and participation in competitive sport were recorded. Post-mortem genetic testing was undertaken in 24/202 (12%). Rare genetic variants were classified according to American College of Medical Genetics and Genomics (ACMG) criteria.

Results: Of 202 ACM decedents (35.4±13.2 years; 82% male), 157 (78%) reported no prior cardiac symptoms. Forty-one decedents (41/202; 20%) were participants in competitive sport. The adjusted odds of dying during physical exertion were higher in males than females (OR 4.58; 95% CI 1.54-13.68; p=0.006) and in competitive athletes compared with non-athletes (OR 16.62; 95% CI 5.39-51.24; p<0.001). None of the decedents with an ante-mortem diagnosis of DCM fulfilled definite 2010 Task Force criteria. Macroscopic appearance of the heart was normal in 40/202 (20%) cases. There was left ventricular (LV) histopathological involvement in 176/202 (87%). Isolated RV disease was seen in 13%, isolated LV disease in 17%, and biventricular involvement in 70%. Among whole hearts, the most common areas of fibro-fatty infiltration were the LV posterobasal (68%) and anterolateral walls (58%). Post-mortem genetic testing yielded pathogenic variants in ACM-related genes in 6/24 (25%) decedents.

Conclusions: SCD due to ACM affects males predominantly, most commonly occurring during exertion in athletic individuals in the absence of prior reported cardiac symptoms. LV involvement is observed in the vast majority of SCD cases diagnosed with ACM at autopsy. Current Task Force criteria may fail to diagnose biventricular ACM prior to death.

Key Words: Arrhythmogenic cardiomyopathy; sudden cardiac death; left ventricular arrhythmogenic cardiomyopathy

Downloaded from http://ahajournals.org by on February 7, 2019

Clinical Perspective

What is new?

- In this large comprehensive autopsy study, we demonstrate that left ventricular involvement is observed in most decedents with arrhythmogenic cardiomyopathy and the left ventricle is exclusively involved in nearly a fifth of cases.
- Age at death, sex, normal macroscopic appearance of the heart, and participation in competitive sport were not associated with the presence of left ventricular involvement.
- We describe diagnostic histopathological criteria for arrhythmogenic cardiomyopathy involving either or both ventricles.

What are the clinical implications?

- This study identified that the heart was macroscopically normal in 20% of decedents with ACM; expert pathological assessment, including histology, is therefore crucial to inform diagnosis in cases of initially unexplained sudden cardiac death.
- Left ventricular variants of arrhythmogenic cardiomyopathy may evade clinical detection using current diagnostic tools; this should be addressed in future revisions of Task Force criteria.

Downloaded from http://ahajournals.org by on February 7, 2019

Introduction

Arrhythmogenic cardiomyopathy (ACM) is a genetic heart muscle disorder characterized by myocardial atrophy and fibrofatty replacement of the ventricular myocardium. Originally described as arrhythmogenic right ventricular cardiomyopathy/dysplasia (ARVC) (1,2), increased recognition of left ventricular (LV) involvement has recently led to adoption of the term 'ACM' (3,4). Arrhythmogenic cardiomyopathy has an estimated prevalence of 1:2000-1:5000 and is an important cause of sudden cardiac death (SCD) among young individuals including athletes (3,5,6). Typically, ACM follows a Mendelian autosomal dominant inheritance pattern, where disease-causing mutations in over thirteen genes have been identified (7). Approximately half of the index cases with a clinical diagnosis harbor putative mutations in genes encoding desmosomal proteins: plakophilin-2 (PKP2), desmoplakin (DSP), desmocollin-2 (DSC2), junction plakoglobin (JUP), and desmoglein-2 (DSG2).

Clinical presentation of ACM is heterogeneous, and diagnosis can be challenging (3). This is reflected by the Task Force criteria, which integrate a number of structural, histopathological, electrocardiographic, familial, arrhythmic, and genetic parameters (6). Moreover, these criteria are derived from cohorts with predominantly right ventricular involvement (ARVC), thus can potentially fall short for a significant proportion of those with LV dominant or biventricular disease. Task Force criteria require the presence of fibrofatty replacement of the right ventricular (RV) free wall myocardium on endomyocardial biopsy or at autopsy (6), however, pathological and imaging studies have reported LV involvement ranging between 16% and 76% of cases (8-12). Cardiovascular Magnetic Resonance (CMR) may show late gadolinium enhancement, indicative of myocardial fibrosis, in a sub-epicardial or mid-myocardial distribution, usually within the LV inferior or inferolateral walls (13).

Downloaded from http://ahajournals.org by on February 7, 2019

The purpose of this study was to report the pathological features of a large cohort of decedents experiencing SCD from ACM, with a particular focus on the presence of LV involvement. In addition, we sought to report on the clinical characteristics and genetic associations of the cohort.

Methods

The data, analytical methods, and study materials will not be made available to other researchers for purposes of reproducing the results or replicating the procedure. All unexpected sudden deaths in the UK are reported to the coroner, who determines the need for autopsy examination. The Cardiac Risk in the Young Center for Cardiac Pathology (CRY CCP) at St George's, University of London provides a nationally recognized expert cardiac pathology service. Referral is initiated voluntarily by the coroner's pathologist following an unexplained SCD, or if there is suspicion of an inherited heart condition. The center receives approximately 500 SCD cases per annum, just over half under the age of 35 years. A report to the coroner is issued within a two-week period.

All referrals to the CRY CCP undergo a full coroner's pathologist autopsy. Since 2013, spleen samples have been collected for post-mortem genetic testing. Pathological findings and corresponding clinical information were entered into a database incorporating imaging from histological sections and autopsy/toxicology reports from UK coroners. Ethical approval for this study was obtained from the UK National Health Service Research Ethics Committee. Informed consent was provided by the next of kin at the time of referral.

Downloaded from http://ahajournals.org by on February 7, 2019

Study group

We evaluated 5205 consecutive SCD cases referred to the CRY CCP between 1994 and 2018 (*Figure 1*). Inclusion criteria for this study were: 1) SCD defined by one of the following: an unheralded witnessed instantaneous death; a death preceded by a prodrome of acute cardiac symptoms up to one hour before death; or an unwitnessed case without a prior deterioration in the preceding 24 hours. 2) Pathological diagnosis of ACM at autopsy. 3) Absence of an extra-cardiac cause of death. 4) Negative toxicology screen. 5) Absence of obstructive coronary artery disease (atherosclerosis with residual luminal diameter <1mm^2). Decedents with an ante-mortem diagnosis of cardiomyopathy were included.

Demographics and Clinical Characteristics

A questionnaire was sent to all referring pathologists and coroners' officers relating to demographics, medical history, symptoms, family history, sports participation, and circumstances of death. Additional information was obtained by autopsy reports from the referring pathologist, primary care/hospital correspondence, and family member interviews. This was acquired within three months of initial referral to our center. Media and sports club correspondence was also reviewed for competitive sports participation. Decedents were considered competitive athletes if they engaged in an organized team or individual sport requiring regular training and participation in competitive events (14). For those with an ante-mortem diagnosis of cardiomyopathy, the clinical notes and investigations (including electrocardiogram (ECG), echocardiography, ambulatory cardiac monitoring, signal-averaged ECG, and CMR) were subsequently requested and analyzed according to the revised Task Force criteria (6).

Downloaded from http://ahajournals.org by on February 7, 2019

Autopsy evaluation

Whole hearts (3018/5205; 58%) and cases with tissue blocks (2187/5205; 42%) underwent detailed histopathological analysis, including microscopic examination of tissue from both ventricles. Sections were fixed in formalin, embedded in paraffin, and stained with Hematoxylin and Eosin (H&E). The following areas were routinely examined: the right ventricular outflow tract; the anterior, lateral, and posterior right ventricle (mid-ventricular level); interventricular septum; anterior, lateral and posterior left ventricle; the three major coronary arteries; and the ascending aorta. The apices of both ventricles were not examined in the absence of an overt structural abnormality. Information from the referring pathologist's autopsy was also recorded, incorporating macroscopic appearances of the heart, body weight, and heart weight. At least two tissue blocks from both ventricles were required for study inclusion.

ACM was defined on microscopic analysis as myocyte degeneration associated with intermixed fat and fibrosis (within the same microscopic field) from the subepicardial region inward or transmural in either or both ventricles (>20% in at least two tissue blocks of 4cm^2; H&E stain). Disease involvement within the interventricular septum was defined by myocyte degeneration associated with intermixed fat and fibrosis from either side or within the mid-wall. This definition has been updated from a previous report (15). *Figure 2* compares normal histological appearances in the right ventricle with a case meeting diagnostic criteria for ACM. All cases included in the study were examined by the senior author (MNS), in addition to review by at least one other pathologist.

Post-mortem genetic testing

Following extraction of DNA from retained splenic tissue (n=24), cardiac gene panel testing was performed using the Illumina TruSight Cardio (174 genes) panel (or a custom Agilent SureSelect

Downloaded from http://ahajournals.org by on February 7, 2019

with equivalent content) (*Supplemental Table 1*) and sequenced on the Illumina platform (NextSeq or HiSeq), as previously described and validated (16,17). Variant annotation was then undertaken in-house using SnpEff v4.3T (build 2017-11-24) (18), GRCh37.75 and ANNOVAR (version 2017-07-17) (19). Rare variants were defined as those with a minor allele frequency (MAF) cut off <0.01% in the Exome Aggregation Consortium (ExAC) general population database (exac.broadinstitute.org). Rare variants were then assessed for pathogenicity according to the American College of Medical Genetics and Genomics (ACMG) criteria (20). These criteria integrate a number of factors including population data, functional data, computational data, and segregation analysis to inform assessment of pathogenicity.

Statistical analysis

All variables were graphically inspected and summarized according to their nature and by outcomes of interest (i.e. mean, standard deviation, median) for continuous variables and proportions for binary or categorical variables. Data are presented as mean ± 1 standard deviation or percentages and appropriate tests (t tests, (Fisher) chi-squared) were employed for a preliminary flavor of variable associations.

There were two outcomes of primary interest, notably death occurring during physical exertion and LV histopathological involvement. Univariable and multivariable logistic regression analyses were used to understand the strength of the crude and adjusted associations between these two outcomes and available demographics and clinical features in the ACM SCD group. The Hosmer-Lemeshow test was used to assess models' goodness of fit. A *P*-value of <0.05 was deemed statistically significant. Statistical analyses were performed using Stata IC/15 (StataCorp, College Station, TX, US). The author ICS holds responsibility for the statistical methodology applied to the data in this paper.

Downloaded from http://ahajournals.org by on February 7, 2019

Results

Baseline demographics

Of 5205 cases of SCD referred to our unit, 202 (4%) were diagnosed with ACM. The majority of decedents from ACM were male (166/202; 82%) and white (182/202; 90%). The mean age of death was 35.4±13.2 years (median 34.5 years).

Clinical characteristics

The great majority of cases (187/202; 93%) did not have an ante-mortem diagnosis of cardiac disease. Only 15/202 (7%) decedents carried a diagnosis of cardiomyopathy, of which 7/15 (47%) were labelled as ACM and 8/15 (53%) as dilated cardiomyopathy (DCM). Six of the overall SCD cohort with ACM (6/202; 3%) had an implantable cardioverter defibrillator (ICD) in situ. Fifteen (7%) reported a family history of SCD under the age of 35 years, none of whom were diagnosed with cardiomyopathy in life. Two decedents with a positive family history had been referred for clinical investigation. *Table 1* outlines clinical and pathological characteristics stratified by circumstances of death.

In most decedents with ACM (157/202; 78%), there were no reported symptoms prior to death; twenty (10%) recorded syncope prior to death, which was associated with an ante-mortem diagnosis of cardiomyopathy in six cases. The remaining decedents (25/202; 12%) documented a prior history of palpitations (8%), chest pain (2%), and pre-syncope (2%). Eighty-three (41%) of the overall cohort died during physical exertion, and 105 (52%) died at rest or during sleep. Decedents with an existing diagnosis of cardiomyopathy were more likely to have died at rest or during sleep compared with during physical exertion (87% vs 7%, respectively; p=0.004). Circumstances of death were unspecified in 14/202 (7%); there was no significant pattern in missing data with respect to other variables. Among young (<35 years old) decedents with ACM,

Downloaded from http://ahajournals.org by on February 7, 2019

there were more deaths during physical exertion compared with older decedents (50% vs 33%, respectively; p=0.01).

Pathological characteristics

In the majority of cases (120/202; 59%), the whole heart was received for analysis. Of the remaining cases with tissue blocks (41%), the mean number of blocks received across both ventricles was 8.3±3.2 (range 4-15). In 40/202 (20%), macroscopic examination of the heart did not yield an overt structural abnormality (*Supplemental Figure 1*). Heart weight and body weight were recorded in 193/202 (96%) and 131/202 (65%) cases respectively, and demonstrated a positive correlation (r=0.55 p<0.001, n=129). Overall, 27% of men recorded heart weights greater than 500g, and 23% of females greater than 400g. The association between body weight and heart weight was independent of LV histopathological involvement (n=129, p=0.74). Following histological evaluation, none of the cases meeting diagnostic criteria for ACM showed myocardial inflammatory infiltrates.

Ventricular involvement

An overview of ventricular histopathological involvement is presented in *Figure 3.* Left ventricular fibrofatty infiltration was present in 176/202 (87%) decedents. Disease exclusive to the LV was observed in 35/202 (17%), and RV in 26/202 (13%), with 141/202 (70%) having evidence of biventricular disease. Among whole hearts referred to our center (120/202; 59%), the most common sites of LV disease involvement were the posterobasal wall (81/120; 68%) and anterolateral wall (69/120; 58%). In the RV, the anterolateral wall (77/120; 64%), and right ventricular outflow tract (57/120; 48%) were most frequently implicated. A logistic regression model found no significant association between LV disease and age at death (p=0.31), male sex

Downloaded from http://ahajournals.org by on February 7, 2019

(p=0.58), macroscopically normal appearance of the heart (p=0.49), or competitive sport participation (p=0.27)(*Supplemental Table 2*).

Competitive athletes

Of 202 decedents with ACM, 41 (20%) participated in competitive sport and the majority of the decedents (35/41; 85%) were aged <35 years. Thirty-one athletes (31/41; 76%) were engaged in sports with a high dynamic component (*Supplemental Figure 2*). The vast majority (37/41; 90%) of athletes died during physical exertion, including 30 athletes (30/41; 73%) who died during participation in sport. In contrast, 46/147 (31%) of the non-athlete decedents died during physical exertion (90% vs 31%, respectively; p<0.001). There was no significant difference in disease distribution within the heart between athletes and non-athletes (p=0.10).

Multivariable analysis showed that male sex (OR 4.58; 95% CI 1.54-13.68; p=0.006) and participation in competitive sport (OR 16.62; 95% CI 5.39-51.24; p<0.001) were independent predictors of death during physical exertion (*Table 2*).

Genetic testing

Genetic testing was performed in all cases with post-mortem DNA available (n= 24 [12%]). A total of 27 rare variants were identified in 14/24 (58%) cases. Six decedents (6/24; 25%) hosted single pathogenic variants in known ACM genes: *DSP* (n=2; truncating mutations), *TMEM43* (n=2; missense mutations), and *PKP2* (n=2; frameshift mutations)(*Table 3*). The same pathogenic *TMEM43* variant (p.Ser358Leu) was identified in two unrelated individuals and has been described in a number of different cohorts in the ClinVar database (www.ncbi.nlm.nih.gov/clinvar). None of the decedents hosted more than one pathogenic variant. Four decedents harbored rare variants of uncertain significance (VUSs) according to ACMG criteria in desmosomal-related genes: one male with a pathogenic DSP variant hosted

Downloaded from http://ahajournals.org by on February 7, 2019

both missense and splice-site variants in *DSC2*; a previously reported rare missense variant was identified in DSC2 was identified in one decedent; and novel missense variants in *DSP* and *PKP* (VUS) were identified in two individuals also harboring pathogenic variants in these genes. All VUSs are outlined in *Supplemental Table 3.*

Clinico-pathological correlations

Clinical investigations were available in 10 of the 15 (67%) decedents with an ante-mortem diagnosis of cardiomyopathy. Seven subjects were diagnosed with DCM of which four had ICDs in situ, and three decedents were diagnosed with ACM of which one had an ICD. Cardiac MRI had been performed in half and showed evidence of LV disease in 4/5 (80%). Modified Task Force criteria were applied retrospectively to all 10 cases. None of the decedents with a clinical diagnosis of DCM achieved a definite diagnosis of ACM using Task Force criteria (*Table 4*). *Figure 4* shows ECG, CMR, and echocardiogram appearances in an individual with LV-exclusive ACM diagnosed with DCM prior to death. Of seven presumptive DCM diagnoses, none fulfilled major or minor TFC for imaging (*Supplemental Table 4*) whilst six (86%) exhibited T-wave inversion in at least one of the lateral leads (I, aVL, V5, and V6) and none demonstrated T-wave inversion in V1-V3.

Following autopsy examination, macroscopic appearances of the heart were abnormal in all 10 subjects. Post-mortem genetic testing was undertaken in only a few and identified a DSP pathogenic variant in one DCM case, and a PKP2 pathogenic variant in an individual with ACM.

Downloaded from http://ahajournals.org by on February 7, 2019

Discussion

To our knowledge, we report the largest pathological series of ACM in SCD employing contemporary definitions. We demonstrate that comprehensive histopathological evaluation

identifies LV involvement in the overwhelming majority (87%) of individuals experiencing SCD from ACM. This appears to be independent of age at death, sex, normal macroscopic appearance of the heart, and participation in competitive sport.

Clinical associations and implications

While ACM affects both sexes, males are more often phenotypically affected with a higher mortality rate and an increased incidence of cardiac arrest as the initial manifestation (21,22). These observations are consistent with our cohort, which was mainly male (82%). Furthermore, whilst death during physical exertion is well described (15), 52% of deaths in our study occurred at rest or during sleep. Syncope is also a common presenting symptom and marker of SCD risk. A quarter of a US cohort of ACM patients (N=100) had a history of syncope (23), and an Italian registry of 301 ACM patients reported that syncope was associated with a three-fold increased risk of life-threatening arrhythmic events during follow-up (24). Nonetheless, most subjects in our study (78%) failed to report any cardiac symptoms prior to presenting with SCD, and only 10% had experienced some form of syncope.

Over half of our decedents diagnosed with cardiomyopathy in life were labelled as DCM, but showed pathological features of ACM at autopsy. The overlap between DCM and ACM may present several diagnostic challenges as reflected in the finding that none of our decedents with an ante-mortem diagnosis of DCM fulfilled current Task Force criteria for a definite diagnosis of ACM. Among the ante-mortem DCM cohort, six (86%) exhibited T-wave inversion in at least one of the lateral leads: I, aVL, V5, and V6; none demonstrated T-wave inversion in V1-V3. This highlights the phenotypic spectrum of ACM and the potential for biventricular disease to evade clinical diagnosis and subsequent risk management. We also identified a family history of young SCD (<35 years old) in 7% of the cohort, none of whom were diagnosed with

Downloaded from http://ahajournals.org by on February 7, 2019

cardiomyopathy during life. Guidelines recommend comprehensive family evaluation in this setting and may have led to recognition of risk prior to death (25).

Myocardial involvement at autopsy

An early pathological study of 30 ACM hearts revealed LV involvement in 47% of their cohort (8). Patchy inflammatory infiltrates were also detected in 20 (67%) cases, a finding that was not replicated during histological examination of our study group. A later study of 42 cases showed macroscopic or microscopic features of LV disease in 76%, with a predilection for the septum and free wall (posteroseptal and posterolateral regions) (9). In keeping with this and other prior studies, the posterobasal wall was the commonest location of LV fibrofatty infiltration (68%) in our group. More recently, LV histological abnormalities were found in a lower proportion (32%) of 200 SCD cases attributed to ACM (10). However, fatty infiltration of the RV was considered pathological in this study, even in the absence of fibrosis. Our observations suggest that fatty infiltration of the RV should not be considered diagnostic for ACM. Our study also reports LV histopathological involvement in a much higher proportion of decedents with ACM (87%). The role of inflammation in ACM has yet to be fully resolved. The lack of myocardial inflammatory infiltrates detected among our cohort is contrary to earlier assertions linking inflammation to severity of outcome in ACM (26).

Correlation with imaging studies

The natural history of LV involvement in ACM is poorly understood. Our finding that LV involvement was not associated with age at death or macroscopic appearance of the heart at autopsy corroborates imaging studies that suggest LV involvement may occur at an early stage (27). Ghannudi et al (28) evaluated 21 patients with ACM and found 52% had LV involvement on CMR. The degree of RV impairment was similar between those with isolated RV

Downloaded from http://ahajournals.org by on February 7, 2019

involvement and disease affecting the LV. Rastegar and colleagues also studied 78 ACM mutation carriers of whom 38 had structural abnormalities on CMR, including the LV in 55% (29). The higher proportion of cases with LV involvement in our cohort may reflect a greater sensitivity of histopathology for fibrosis.

Competitive sport

The link between athletic activity and SCD risk in patients with ACM is widely acknowledged (30). A previous study found that participation in competitive sport was associated with a two-fold increased risk of ventricular arrhythmia and SCD in ACM, but recreational sport followed a more benign course (31). Data from a prospective multinational registry of athletes with ICDs also identified ACM as the only diagnosis associated with appropriate shocks during competitive sport (32). Current guidelines recommend against participation in competitive and/or endurance sport among individuals meeting Task Force criteria (33). Our data show that most competitive athletes who died with ACM were engaged in sports with a maximum dynamic component, i.e. requiring the highest cardiac output, and the great majority (90%) of these deaths occurred during physical exertion. We found no difference in either RV-exclusive disease or LV involvement between athletes and non-athletes, suggesting that exercise-induced remodeling alone is insufficient to lead to the ACM phenotype.

Genetic evaluation and implications

To our knowledge, there have been no published studies evaluating the utility of post-mortem genetic testing in ACM. Diagnostic yield may be influenced by several factors, such as disease presentation, family history, and geographic region (34). Our use of a stringent MAF threshold and application of ACMG criteria may have resulted in a more conservative yield when compared with prior genetic studies (34,35). Among decedents unheralded with cardiac disease,

Downloaded from http://ahajournals.org by on February 7, 2019

none had a reported family history of ACM. The only pathogenic variants identified in this group were in *TMEM43 and PKP2*, the same missense variant being identified in both (unrelated) *TMEM43* subjects. This variant had previously been reported in multiple ACM families internationally, is highly penetrant and has strong evidence for pathogenicity (36). Both probands exhibited histopathological involvement of the LV, consistent with prior data on the mutation, which is associated with a particularly malignant form of ACM (Arrhythmogenic Right Ventricular Cardiomyopathy Type 5). *DSP* is also highly penetrant and associated with LV involvement and higher risk, especially truncating variants (37,38). Two subjects hosted truncating pathogenic *DSP* variants, and both had prior diagnoses of DCM.

Implications for the pathologist and clinician

We demonstrated that 20% of ACM cases were macroscopically normal on initial inspection, regardless of LV involvement. Our findings are in line with earlier studies that recognize a concealed phase in ACM, where SCD may occur in the absence of overt structural abnormalities (39). This reinforces the importance of histological analysis of hearts in all cases of SCD. Moreover, previous reports have described sudden death occurring in PKP2 mutation carriers exhibiting structurally normal hearts at autopsy (40,41); this may suggest a propensity for malignant arrhythmia in those with a pure electrical phenotype.

In 17% of our cases, fibrofatty infiltration was identified exclusively within the LV, consistent with the previously described entity of 'LV-Dominant' ACM (13). LV-dominant ACM may manifest clinically with inferolateral T wave inversion on the 12-lead ECG, arrhythmias of LV origin, and suggestive appearances on cardiac imaging. Thus, the absence of RV structural abnormality may lead to poor recognition of 'non-classical' disease utilizing current diagnostic criteria. Moreover, the significant minority of ACM SCD cases with LV-

Downloaded from http://ahajournals.org by on February 7, 2019

exclusive disease support inclusion of LV pathological and clinical markers in future revision of Task Force criteria.

Study limitations

This study relied on referral of SCD cases to an expert cardiac pathology center, therefore, there may be an element of referral bias as pathologists may choose to refer more challenging cases and potentially a higher proportion of cases with LV involvement. In 41% of cases, the whole heart was not sent to the center for analysis and macroscopic appearances of the heart were noted by the referring pathologist. Consequently, sampling technique may differ according to local protocols. However, tissue blocks from both ventricles were received in each case and histological diagnostic criteria consistently applied. Retrospective review of clinical information, competitive sports participation, and family member interviews could be subject to recall bias and may have underestimated the true extent of symptoms experienced in life that may otherwise have not been documented. Finally, whilst genetic testing was performed on all possible individuals with retained DNA for molecular autopsy, the group with genetic results is small so inference of genotype mediated risk is inappropriate. A larger genetic testing uptake in the cohort would facilitate important genotype-phenotype correlations and assessment of genetic yield, which would be an important area worthy of future research.

Conclusions

Most ACM-related SCDs occurred without preceding ante-mortem symptoms or relevant family history. Exercise-related SCD was observed in the majority of competitive athletes, with competitive sport participation conveying significantly increased odds of death during physical exertion. A fifth of cases demonstrated a macroscopically normal heart, emphasizing the importance of histopathological evaluation in cardiac autopsy. LV involvement was present in

Downloaded from http://ahajournals.org by on February 7, 2019

the great majority of cases, with 17% exhibiting disease exclusive to the LV. Our study supports inclusion of left ventricular structural involvement in future revision of Task Force diagnostic criteria.

Author List

Chris Miles, MBChB, MRCP[1]; Gherardo Finocchiaro, MD[1];
Michael Papadakis, MBBS, MD, MRCP[1]; Belinda Gray, MBBS, PhD[1];
Joseph Westaby, BMBS, MSc[1]; Bode Ensam, MBBS, MRCP[1];
Joyee Basu, BMBCh, MA, MRCP[1]; Gemma Parry-Williams, MBChB, MRCP[1];
Efstathios Papatheodorou, MD[1]; Casey Paterson, B.Com.[1]; Aneil Malhotra, MBBChir, MA, MSc, PhD, MRCP[1]; Jan Lukas Robertus, MD, PhD[2]; James S. Ware, MBBChir, MA, PhD, MRCP[3]; Stuart A Cook, PhD, MRCP[3]; Angeliki Asimaki, PhD[1]; Adam Witney, PhD[4];
Irina Chis Ster, MSc, PhD[4]; Maite Tome, MD, PhD[1]; Sanjay Sharma, BSc(Hons), MD, FRCP(UK), FESC[1]; Elijah R. Behr, MA, MBBS, MD[1*]; Mary N. Sheppard, MBBCh, MD, FRCPath[1*]

Affiliations

[1]Cardiology Clinical Academic Group, St George's University Hospitals' NHS Foundation Trust and Molecular and Clinical Sciences Institute, St George's University of London, London, United Kingdom; [2]Department of Pathology, Royal Brompton and Harefield NHS Foundation Trust, Imperial College London, London, United Kingdom; [3]National Heart and Lung Institute & MRC London Institute of Medical Sciences, Imperial College London, and Royal Brompton and

Downloaded from http://ahajournals.org by on February 7, 2019

Harefield NHS Foundation Trust, London, United Kingdom; [4]Institute of Infection and Immunity, St George's University of London, London, United Kingdom

* Joint senior authorship

Acknowledgments

The authors are grateful to the charitable organization Cardiac Risk in the Young (CRY) for providing funding to support the CRY Center for Cardiac Pathology. We also thank the British Heart Foundation (BHF) for supporting the first author (CM) with a clinical research training fellowship (BHF Clinical Research Training Fellowship no. FS/18/28/33549).

Sources of Funding

CM is funded by the British Heart Foundation (BHF Clinical Research Training Fellowship FS/18/28/33549), the Robert Lancaster Memorial Fund sponsored by McColl's Retail Group Ltd, and Cardiac Risk in the Young (CRY). GF, MP, BE, JB, GPW, SP, and AM have received research fellowship grants from CRY. BG is the recipient of a National Health and Medical Research Council Early Career Fellowship (Fellowship #1122330). AM and JW receive support from the National Institute for Health Research. ERB and BE received research funding from the Robert Lancaster Memorial Fund sponsored by McColl's Retail Group Ltd.

Disclosures

None.

Downloaded from http://ahajournals.org by on February 7, 2019

References

1. Thiene G. The research venture in arrhythmogenic right ventricular cardiomyopathy: a paradigm of translational medicine. *Eur Heart J.* 2015; 36: 837-848.
2. Marcus FI, Fontaine GH, Guiraudon G, Frank R, Laurenceau JL, Malergue C, Grosgogeat Y. Right ventricular dysplasia: a report of 24 adult cases. *Circulation.* 1982; 65: 384.
3. Corrado D, Link MS, Calkins H. Arrhythmogenic Right Ventricular Cardiomyopathy. *N Engl J Med.* 2017; 376: 61-72.
4. Saffitz JE. Arrhythmogenic Cardiomyopathy. *Circulation.* 2011; 124: e390.
5. McKenna WJ, Maron BJ, Thiene G. Classification, Epidemiology, and Global Burden of Cardiomyopathies. *Circ Res.* 2017; 121: 722.
6. Marcus FI, McKenna WJ, Sherrill D, Basso C, Bauce B, Bluemke DA, Calkins H, Corrado D, Cox MG, Daubert JP, Fontaine G, Gear K, Hauer R, Nava A, Picard MH, Protonotarios N, Saffitz JE, Sanborn DM, Steinberg JS, Tandri H, Thiene G, Towbin JA, Tsatsopoulou A, Wichter T, Zareba W. Diagnosis of arrhythmogenic right ventricular cardiomyopathy/dysplasia: proposed modification of the task force criteria. *Circulation.* 2010; 121: 1533-1541.
7. Xu Z, Zhu W, Wang C, Huang L, Zhou Q, Hu J, Cheng X, Hong K. Genotype-phenotype relationship in patients with arrhythmogenic right ventricular cardiomyopathy caused by desmosomal gene mutations: A systematic review and meta-analysis. *Scientific Reports.* 2017; 7: 41387.
8. Basso C, Thiene G, Corrado D, Angelini A, Nava A, Valente M. Arrhythmogenic right ventricular cardiomyopathy. Dysplasia, dystrophy, or myocarditis? *Circulation.* 1996; 94: 983-991.
9. Corrado D, Basso C, Thiene G, McKenna WJ, Davies MJ, Fontaliran F, Nava A, Silvestri F, Blomstrom-Lundqvist C, Wlodarska EK, Fontaine G, Camerini F. Spectrum of Clinicopathologic Manifestations of Arrhythmogenic Right Ventricular Cardiomyopathy/Dysplasia: A Multicenter Study. *J Am Coll Cardiol.* 1997; 30: 1512-1520.
10. Tabib A, Loire R, Chalabreysse L, Meyronnet D, Miras A, Malicier D, Thivolet F, Chevalier P, Bouvagnet P. Circumstances of Death and Gross and Microscopic Observations in a Series of 200 Cases of Sudden Death Associated With Arrhythmogenic Right Ventricular Cardiomyopathy and/or Dysplasia. *Circulation.* 2003; 108: 3000.
11. te Riele A,S.J.M., James CA, Philips B, Rastegar N, Bhonsale A, Groeneweg JA, Murray B, Tichnell C, Judge DP, van der Heijden J,F., Cramer MJM, Velthuis BK, Bluemke DA, Zimmerman SL, Kamel IR, Hauer RNW, Calkins H, Tandri H. Mutation Positive Arrhyhmogenic Right Ventricular Dysplasia/Cardiomyopathy: The Triangle of Dysplasia Displaced. *J Cardiovasc Electrophysiol.* 2013; 24: 1311-1320.
12. Berte B, Denis A, Amraoui S, Yamashita S, Komatsu Y, Pillois X, Sacher F, Mahida S, Wielandts J, Sellal J, Frontera A, Al Jefairi N, Derval N, Montaudon M, Laurent F, Hocini M, Haïssaguerre M, Jaïs P, Cochet H. Characterization of the Left-Sided Substrate in Arrhythmogenic Right Ventricular Cardiomyopathy. *Circ Arrhythm Electrophysiol.* 2015; 8: 1403.
13. Sen-Chowdhry S, Syrris P, Prasad SK, Hughes SE, Merrifield R, Ward D, Pennell DJ, McKenna WJ. Left-Dominant Arrhythmogenic Cardiomyopathy: An Under-Recognized Clinical Entity. *J Am Coll Cardiol.* 2008; 52: 2175-2187.

Downloaded from http://ahajournals.org by on February 7, 2019

14. Maron BJ, Zipes DP, Kovacs RJ. Eligibility and Disqualification Recommendations for Competitive Athletes With Cardiovascular Abnormalities: Preamble, Principles, and General Considerations. *Circulation.* 2015; 132: e256.
15. Finocchiaro G, Papadakis M, Robertus JL, Dhutia H, Steriotis AK, Tome M, Mellor G, Merghani A, Malhotra A, Behr E, Sharma S, Sheppard MN. Etiology of Sudden Death in Sports: Insights From a United Kingdom Regional Registry. *J Am Coll Cardiol.* 2016; 67: 2108-2115.
16. Lahrouchi N, Raju H, Lodder EM, Papatheodorou E, Ware JS, Papadakis M, Tadros R, Cole D, Skinner JR, Crawford J, Love DR, Pua CJ, Soh BY, Bhalshankar JD, Govind R, Tfelt-Hansen J, Winkel BG, van der Werf C, Wijeyeratne YD, Mellor G, Till J, Cohen MC, Tome-Esteban M, Sharma S, Wilde AAM, Cook SA, Bezzina CR, Sheppard MN, Behr ER. Utility of Post-Mortem Genetic Testing in Cases of Sudden Arrhythmic Death Syndrome. *J Am Coll Cardiol.* 2017; 69: 2134-2145.
17. Ware JS, John S, Roberts AM, Buchan R, Gong S, Peters NS, Robinson DO, Lucassen A, Behr ER, Cook SA. Next Generation Diagnostics in Inherited Arrhythmia Syndromes. *Journal of Cardiovascular Translational Research.* 2013; 6: 94-103.
18. Cingolani P, Platts A, Wang LL, Coon M, Nguyen T, Wang L, Land SJ, Lu X, Ruden DM. A program for annotating and predicting the effects of single nucleotide polymorphisms, SnpEff: SNPs in the genome of Drosophila melanogaster strain w(1118); iso-2; iso-3. *Fly.* 2012; 6: 80-92.
19. Wang K, Li M, Hakonarson H. ANNOVAR: functional annotation of genetic variants from high-throughput sequencing data. *Nucleic Acids Res.* 2010; 38: e164-e164.
20. Richards S, Aziz N, Bale S, Bick D, Das S, Gastier-Foster J, Grody WW, Hegde M, Lyon E, Spector E, Voelkerding K, Rehm HL, On behalf of the ACMG Laboratory Quality Assurance Committee. Standards and Guidelines for the Interpretation of Sequence Variants: A Joint Consensus Recommendation of the American College of Medical Genetics and Genomics and the Association for Molecular Pathology. *Genet Med.* 2015; 17: 405-424.
21. Lin C, Chung F, Lin Y, Chang S, Lo L, Hu Y, Tuan T, Chao T, Liao J, Chang Y, Chen Y, Walia R, Te ALD, Yamada S, Chen S. Gender differences in patients with arrhythmogenic right ventricular dysplasia/cardiomyopathy: Clinical manifestations, electrophysiological properties, substrate characteristics, and prognosis of radiofrequency catheter ablation. *Int J Cardiol.* 2017; 227: 930-937.
22. Calkins H, Corrado D, Marcus F. Risk Stratification in Arrhythmogenic Right Ventricular Cardiomyopathy. *Circulation.* 2017; 136: 2068.
23. Dalal D, Nasir K, Bomma C, Prakasa K, Tandri H, Piccini J, Roguin A, Tichnell C, James C, Russell SD, Judge DP, Abraham T, Spevak PJ, Bluemke DA, Calkins H. Arrhythmogenic right ventricular dysplasia: a United States experience. *Circulation.* 2005; 112: 3823-3832.
24. Mazzanti A, Ng K, Faragli A, Maragna R, Chiodaroli E, Orphanou N, Monteforte N, Memmi M, Gambelli P, Novelli V, Bloise R, Catalano O, Moro G, Tibollo V, Morini M, Bellazzi R, Napolitano C, Bagnardi V, Priori SG. Arrhythmogenic Right Ventricular Cardiomyopathy: Clinical Course and Predictors of Arrhythmic Risk. *J Am Coll Cardiol.* 2016; 68: 2540-2550.
25. Priori SG, Wilde AA, Horie M, Cho Y, Behr ER, Berul C, Blom N, Brugada J, Chiang CE, Huikuri H, Kannankeril P, Krahn A, Leenhardt A, Moss A, Schwartz PJ, Shimizu W, Tomaselli G, Tracy C. HRS/EHRA/APHRS expert consensus statement on the diagnosis and management of patients with inherited primary arrhythmia syndromes: document endorsed by HRS, EHRA, and APHRS in May 2013 and by ACCF, AHA, PACES, and AEPC in June 2013. *Heart Rhythm.* 2013; 10: 1932-1963.

Downloaded from http://ahajournals.org by on February 7, 2019

26. Campuzano O, Alcalde M, Iglesias A, Barahona-Dussault C, Sarquella-Brugada G, Benito B, Arzamendi D, Flores J, Leung TK, Talajic M, Oliva A, Brugada R. Arrhythmogenic right ventricular cardiomyopathy: severe structural alterations are associated with inflammation. *J Clin Pathol.* 2012; 65: 1077-1083.
27. Sen-Chowdhry S, Syrris P, Ward D, Asimaki A, Sevdalis E, McKenna WJ. Clinical and genetic characterization of families with arrhythmogenic right ventricular dysplasia/cardiomyopathy provides novel insights into patterns of disease expression. *Circulation.* 2007; 115: 1710-1720.
28. Ghannudi SE, Nghiem A, Germain P, Jeung MY, Gangi A, Roy C. Left Ventricular Involvement in Arrhythmogenic Right Ventricular Cardiomyopathy - A Cardiac Magnetic Resonance Imaging Study. *Clin Med Insights Cardiol.* 2014; 8: 27-36.
29. Rastegar N, Zimmerman SL, Te Riele ASJM, James C, Burt JR, Bhonsale A, Murray B, Tichnell C, Judge D, Calkins H, Tandri H, Bluemke DA, Kamel IR. Spectrum of Biventricular Involvement on CMR Among Carriers of ARVD/C-Associated Mutations. *JACC: Cardiovascular Imaging.* 2015; 8: 863.
30. Corrado D, Zorzi A. Arrhythmogenic right ventricular cardiomyopathy and sports activity. *Eur Heart J.* 2015; 36: 1708-1710.
31. Ruwald A, Marcus F, Estes I,N.A.M., Link M, McNitt S, Polonsky B, Calkins H, Towbin JA, Moss AJ, Zareba W. Association of competitive and recreational sport participation with cardiac events in patients with arrhythmogenic right ventricular cardiomyopathy: results from the North American multidisciplinary study of arrhythmogenic right ventricular cardiomyopathy. *Eur Heart J.* 2015; 36: 1735-1743.
32. Lampert R, Olshansky B, Heidbuchel H, Lawless C, Saarel E, Ackerman M, Calkins H, Estes NAM, Link MS, Maron BJ, Marcus F, Scheinman M, Wilkoff BL, Zipes DP, Berul CI, Cheng A, Jordaens L, Law I, Loomis M, Willems R, Barth C, Broos K, Brandt C, Dziura J, Li F, Simone L, Vandenberghe K, Cannom D. Safety of Sports for Athletes With Implantable Cardioverter-Defibrillators: Long-Term Results of a Prospective Multinational Registry. *Circulation.* 2017; 135: 2310-2312.
33. Corrado D, Wichter T, Link MS, Hauer RNW, Marchlinski FE, Anastasakis A, Bauce B, Basso C, Brunckhorst C, Tsatsopoulou A, Tandri H, Paul M, Schmied C, Pelliccia A, Duru F, Protonotarios N, Estes NM, McKenna WJ, Thiene G, Marcus FI, Calkins H. Treatment of Arrhythmogenic Right Ventricular Cardiomyopathy/Dysplasia: An International Task Force Consensus Statement. *Circulation.* 2015; 132: 441-453.
34. Ackerman MJ, Priori SG, Willems S, Berul C, Brugada R, Calkins H, Camm AJ, Ellinor PT, Gollob M, Hamilton R, Hershberger RE, Judge DP, Le Marec H, McKenna WJ, Schulze-Bahr E, Semsarian C, Towbin JA, Watkins H, Wilde A, Wolpert C, Zipes DP, Heart Rhythm Society (HRS), European Heart Rhythm Association (EHRA). HRS/EHRA expert consensus statement on the state of genetic testing for the channelopathies and cardiomyopathies: this document was developed as a partnership between the Heart Rhythm Society (HRS) and the European Heart Rhythm Association (EHRA). *Europace.* 2011; 13: 1077-1109.
35. Kapplinger JD, Landstrom AP, Salisbury BA, Callis TE, Pollevick GD, Tester DJ, Cox MG, Bhuiyan Z, Bikker H, Wiesfeld AC, Hauer RN, van Tintelen JP, Jongbloed JD, Calkins H, Judge DP, Wilde AA, Ackerman MJ. Distinguishing arrhythmogenic right ventricular cardiomyopathy/dysplasia-associated mutations from background genetic noise. *J Am Coll Cardiol.* 2011; 57: 2317-2327.

Downloaded from http://ahajournals.org by on February 7, 2019

36. Merner ND, Hodgkinson KA, Haywood AF, Connors S, French VM, Drenckhahn JD, Kupprion C, Ramadanova K, Thierfelder L, McKenna W, Gallagher B, Morris-Larkin L, Bassett AS, Parfrey PS, Young TL. Arrhythmogenic right ventricular cardiomyopathy type 5 is a fully penetrant, lethal arrhythmic disorder caused by a missense mutation in the TMEM43 gene. *Am J Hum Genet.* 2008; 82: 809-821.
37. Castelletti S, Vischer AS, Syrris P, Crotti L, Spazzolini C, Ghidoni A, Parati G, Jenkins S, Kotta MC, McKenna WJ, Schwartz PJ, Pantazis A. Desmoplakin missense and non-missense mutations in arrhythmogenic right ventricular cardiomyopathy: Genotype-phenotype correlation. *Int J Cardiol.* 2017; 249: 268-273.
38. López-Ayala JM, Gómez-Milanés I, Sánchez Muñoz JJ, Ruiz-Espejo F, Ortíz M, González-Carrillo J, López-Cuenca D, Oliva-Sandoval M, Monserrat L, Valdés M, Gimeno JR. Desmoplakin truncations and arrhythmogenic left ventricular cardiomyopathy: characterizing a phenotype. *EP Europace.* 2014; 16: 1838-1846.
39. Corrado D, Basso C, Thiene G. Sudden cardiac death in young people with apparently normal heart. *Cardiovasc Res.* 2001; 50: 399-408.
40. Lahrouchi N, Raju H, Lodder EM, Papatheodorou E, Ware JS, Papadakis M, Tadros R, Cole D, Skinner JR, Crawford J, Love DR, Pua CJ, Soh BY, Bhalshankar JD, Govind R, Tfelt-Hansen J, Winkel BG, van der Werf C, Wijeyeratne YD, Mellor G, Till J, Cohen MC, Tome-Esteban M, Sharma S, Wilde AAM, Cook SA, Bezzina CR, Sheppard MN, Behr ER. Utility of Post-Mortem Genetic Testing in Cases of Sudden Arrhythmic Death Syndrome. *J Am Coll Cardiol.* 2017; 69: 2134-2145.
41. Jodie I, Bagnall Richard D, Laura Y, Michele M, Yemima B, David W, Johan D, Christopher S. Concealed Arrhythmogenic Right Ventricular Cardiomyopathy in Sudden Unexplained Cardiac Death Events. *Circulation: Genomic and Precision Medicine.* 2018; 11: e002355.

Downloaded from http://ahajournals.org by on February 7, 2019

Table 1. Clinical and pathological characteristics stratified by circumstances of death. Values presented are mean±standard deviation, median, or n (%) as appropriate.

	Overall	**Death during exertion**	**Death at rest / during sleep**	**P value**
N (%)	**202**	**83 (41)**	**105 (52)**	
Age at death (years)	35.4±13.2, 34.5	32.7±12.5, 29	37.7±13.1, 37	**0.01**
Male, n (%)	166 (82)	78 (94)	76 (72)	**<0.001**
White, n (%)	182 (90)	74 (89)	96 (91)	0.60
Body weight, median	81.5±17.4, 81 n=131 (65)	81.0±16.9, 80 n=57 (69)	81.0±17.8, 80.55 n=68 (65)	0.99
Diagnosis of cardiomyopathy ante-mortem, n (%)	15 (7)	1 (1)	13 (12)	**0.004**
Prior syncope, n (%)	20 (10)	8 (10)	12 (11)	0.69
Asymptomatic status, n (%)	157 (78)	65 (78)	80 (76)	0.86
FH SCD (<35 years old), n (%)	15 (7)	5 (6)	9 (9)	0.58
Macroscopically normal appearance of the heart at autopsy, n (%)	40 (20)	18 (22)	20 (19)	0.70
Disease confined to right ventricle, n(%)	26 (13)	11 (13)	14 (13)	0.99
Disease confined to left ventricle, n(%)	35 (17)	15 (18)	19 (18)	0.99
Biventricular disease, n(%)	141 (70)	57 (69)	72 (69)	0.99

FH indicates family history; SCD, sudden cardiac death.

P values represent the strength of association between circumstances of death and the available clinical or demographic variables. Comparisons are made using appropriate tests upon each variable's nature. Circumstances of death were unspecified for 14/202 individuals.

Downloaded from http://ahajournals.org by on February 7, 2019

Table 2. Analyses of death during physical exertion among ACM decedents.

	Univariable Analysis		**Adjusted Analysis**	
	Odds Ratio (95% CI)	**P Value**	**Odds Ratio (95% CI)**	**P Value**
Male	5.95 (2.19-16.19)	<0.001	4.58 (1.54-13.68)	0.006
White	0.77 (0.29-2.04)	0.60		
Age at death	0.97 (0.95-0.99)	0.01	0.99 (0.97-1.02)	0.51
Body weight*	1.00 (0.90-1.11)	0.99		
Heart weight†	1.02 (0.99-1.05)	0.16		
Competitive Athlete	20.30 (6.84-60.34)	<0.001	16.62 (5.39-51.24)	<0.001
Left ventricular involvement	1.01 (0.43-2.35)	0.99		

CI indicates confidence interval.
* per 5kg increase in Weight
† per 10g increase in Heart Weight

American Heart Association
Circulation

Downloaded from http://ahajournals.org by on February 7, 2019

Table 3. Overview of pathogenic variants identified from post-mortem genetic testing

Case ID	Age at death	Circumstances of death	Ante-mortem diagnosis	Pathology	Gene	cDNA change	ExAC MAF	ACMG
Case 1 White Male	37	Died in sleep	ACM	Right ventricular ACM	PKP2	c.2198_2202delACACC	0	Pathogenic PVS1; PM2; PP3
Case 2 White Male	20	Died during exertion	None	Right ventricular ACM	PKP2	c.253_256delGAGT	0	Pathogenic PVS1; PM2; PP3
Case 3 White Female	26	Died at rest	DCM	Biventricular ACM	DSP	c.4395T>G	0	Pathogenic PVS1; PM2; PP3
Case 4 White Male	28	Died at rest	DCM	Biventricular ACM	DSP	c.5269C>T	0	Pathogenic PVS1; PM2; PP3
Case 5 White Male Athlete	20	Died during exertion	None	Biventricular ACM	TMEM43	c.1073C>T	0	Pathogenic PS1; PM2; PM7; PP3
Case 6 White Male	45	Died at rest	None	Biventricular ACM	TMEM43	c.1073C>T	0	Pathogenic PS1; PM2; PM7; PP3

ACM: Arrhythmogenic cardiomyopathy; DCM: Dilated cardiomyopathy; cDNA: Complementary DNA; ExAC: Exome Aggregation Consortium; MAF: Minor allele frequency; ACMG: American College of Medical Genetics and Genomics; PKP2: Plakophilin-2; DSP: Desmoplakin; TMEM43: Transmembrane protein 43; PVS: Pathogenic very strong; PS: Pathogenic strong; PM: Pathogenic moderate; PP: Pathogenic supporting.

Downloaded from http://ahajournals.org by on February 7, 2019

10.1161/CIRCULATIONAHA.118.037230

Table 4. Clinico-pathological correlations among ACM decedents diagnosed with cardiomyopathy ante-mortem

Case	Ante-mortem diagnosis	Age at death	Circumstances of death	Application of modified TFC (2010)					TFC 2010 Major*	TFC 2010 Minor*	TFC 2010 diagnostic certainty	Path diagnosis
				Depolarization/ Conduction	Repolarization	Ventricular arrhythmias	Imaging	Family History				
A	ACM	37	Died at rest	Minor criterion: SAECG – 3 abnormal parameters	Major criterion: Negative T waves in V1, V2, V3, and V4	Minor criteria: 1) NSVT with unknown axis 2) >500 PVCs/24hr	Major criterion (CMR and Echo)	None	2	2	Definite	BiV ACM
B	ACM (ICD in situ)	44	Died at rest	None	None. V paced rhythm	Minor criterion: 1) Sustained VT with unknown axis	Major criterion (CMR and Echo)	None	1	1	Borderline	BiV ACM
C	ACM	37	Died in sleep	None	None	Major criterion: 1) NSVT with LBBB and superior axis Minor criterion: 2) >500 PVCs/24hr	Minor criterion (CMR)	None	1	1	Borderline	RV ACM PKP2†
D	DCM	49	Died during exertion	Minor criterion: Terminal activation duration of QRS ≥ 55ms in V1	Minor criterion: Negative T waves in V4, V5, and V6	Minor criterion: 1) >500 PVCs/24hr	None (CMR and Echo)	None	0	3	Borderline	LV ACM
E	DCM	29	Died at rest	None	Minor criterion: Negative T waves in V4, V5, and V6	Major criterion: 1) NSVT with LBBB and superior axis Minor criterion: 2) >500 PVCs/24hr	None (CMR and Echo)	None	1	1	Borderline	BiV ACM
F	DCM (ICD in situ)	48	Died at rest	None	Minor criterion: Negative T waves in V4, V5, and V6	Minor criterion: NSVT with unknown axis	None (Echo)	None	0	2	Possible	BiV ACM
G	DCM (ICD in situ)	35	Died at rest	None	Minor criterion: Negative T waves in V5 and V6	Minor criterion: 1) NSVT with unknown axis	None (Echo)	None	0	2	Possible	BiV ACM
H	DCM (ICD in situ)	26	Died at rest	None	Minor criterion: Negative T waves in V4, V5, and V6	Minor criterion: 1) Sustained VT with unknown axis	None (Echo)	None	0	2	Possible	BiV ACM DSP†
I	DCM (ICD in situ)	41	Died at rest	None	None. A-V paced rhythm	Minor criterion: 1) Sustained VT with unknown axis	None (Echo)	None	0	1	N/A	BiV ACM
J	DCM	56	Died in sleep	None	Minor criterion: Negative T waves in V4 and V5	None	None (Echo)	None	0	1	N/A	LV ACM

DCM: Dilated cardiomyopathy; ACM: Arrhythmogenic cardiomyopathy; TFC: Task Force Criteria (2010) (6); CMR: Cardiovascular Magnetic Resonance; Echo: Echocardiography; NSVT: Non-sustained ventricular tachycardia; PVCs: Premature ventricular contractions; LBBB: Left bundle branch block; BiV: Biventricular; ICD: Implantable cardioverter defibrillator; SAECG: Signal-averaged ECG; RV: Right ventricular; PKP2: Plakophilin-2; LV: Left ventricular; DSP: Desmoplakin; A-V: Atrial and ventricular; V: Ventricular.

* Task Force Criteria attained from different categories

† Pathogenic variant detected in gene following post-mortem genetic testing

Downloaded from http://ahajournals.org by on February 7, 2019

Figure Legends

Figure 1. Selection of ACM cases from all SCD referred to pathology center.

Figure 2. Histological examination of ACM: Normal findings within the RV versus pathological criteria for ACM.

Figure 3. Ventricular disease involvement among all ACM decedents (n=202)(left). Distribution of fibrofatty infiltration among whole hearts referred to pathology center (n=120)(right). RV: Right ventricle; LV: Left ventricle; RVAL: RV anterolateral wall; RVOT: RV outflow tract; RVS: RV septum; RVPW: RV posterior wall; LVS: LV septum; LVAL: LV anterolateral wall; LVPW: LV posterior wall.

Figure 4. A case of LV-dominant ACM. A: Histological slide (Picrosirius red stain) demonstrating myocyte degeneration and fibrofatty infiltration within the posterolateral wall of the LV (extending transmurally). B: 12-lead ECG showing first degree AV-block, inferolateral T-wave inversion (arrows) and low voltage limb lead QRS complexes, prolonged terminal activation duration in V1, and ventricular bigeminy with fragmented, broad, ectopics of RBBB morphology and superior axis (arrow). C+D: Delayed-enhancement CMR images illustrating extensive LV delayed enhancement, including near transmural enhancement of the lateral wall and mid-wall enhancement of the anterior wall. E: Parasternal long axis view (echocardiography) showing severe LV dilatation (left ventricular end-diastolic dimension 71mm).

Downloaded from http://ahajournals.org by on February 7, 2019



Downloaded from http://ahajournals.org by on February 7, 2019

ACM

Normal RV fatty infiltration

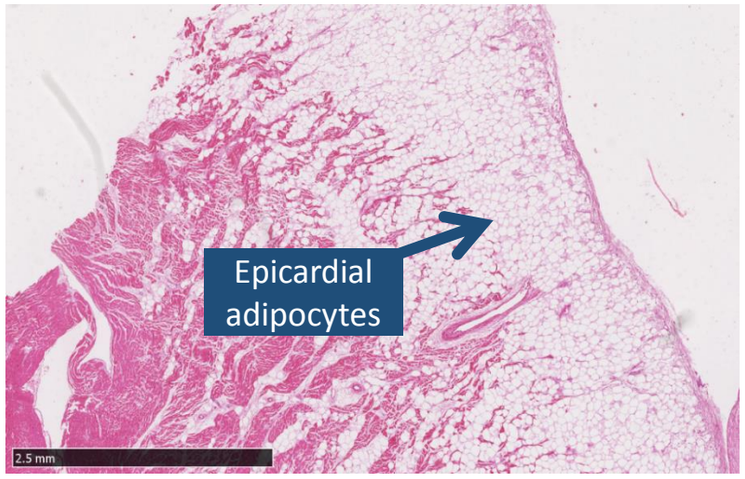

Isolated areas of fibrosis between trabeculae without intermixed adipocytes

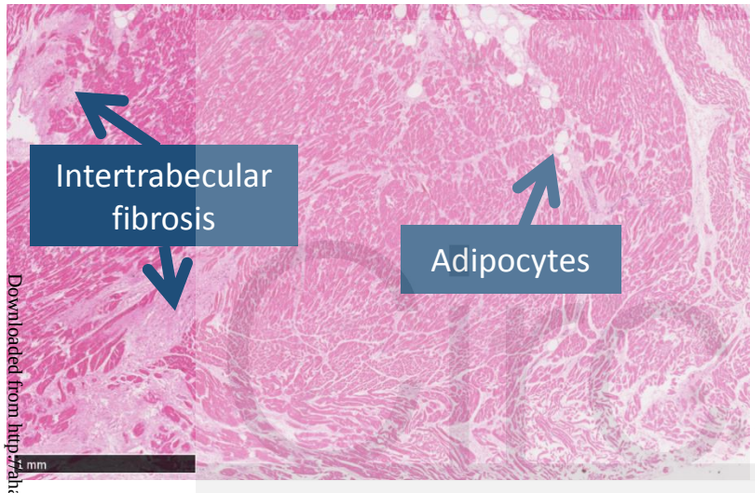

Non-epicardial adipocytes and peri-vascular collagen within right ventricle

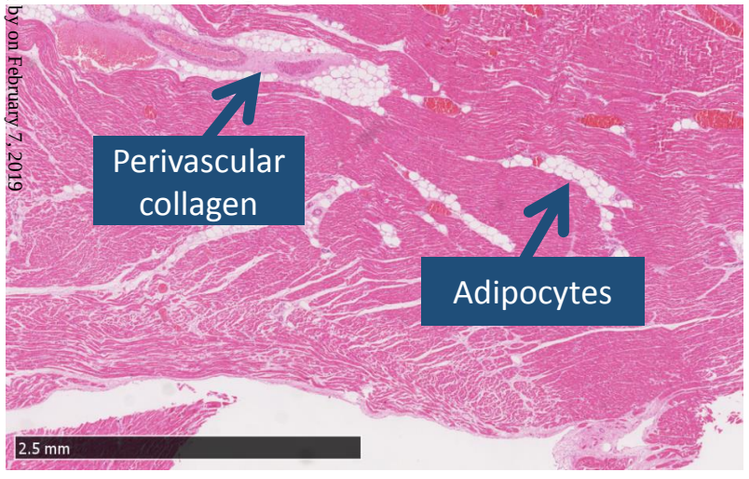

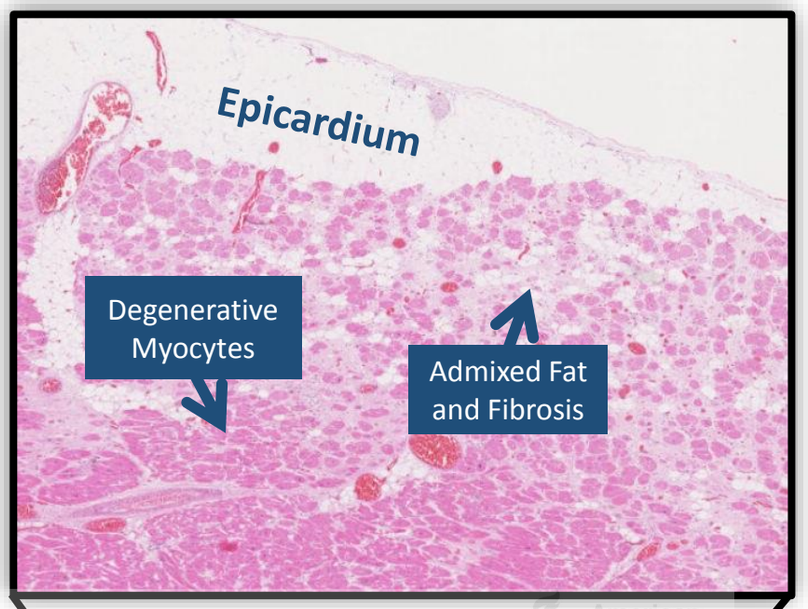

Myocyte degeneration
Fat & fibrosis (co-located)
Subepicardial →
Transmural
≥ 2 tissue blocks

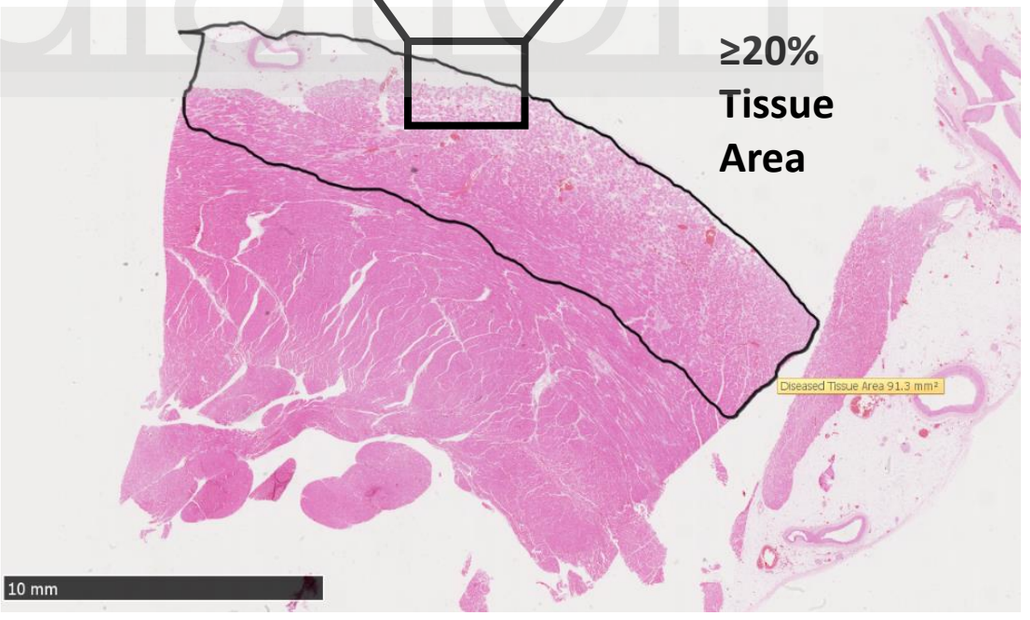

NORMAL / NON-DIAGNOSTIC → **PATHOLOGICAL**

Downloaded from http://ahajournals.org by on February 7, 2019

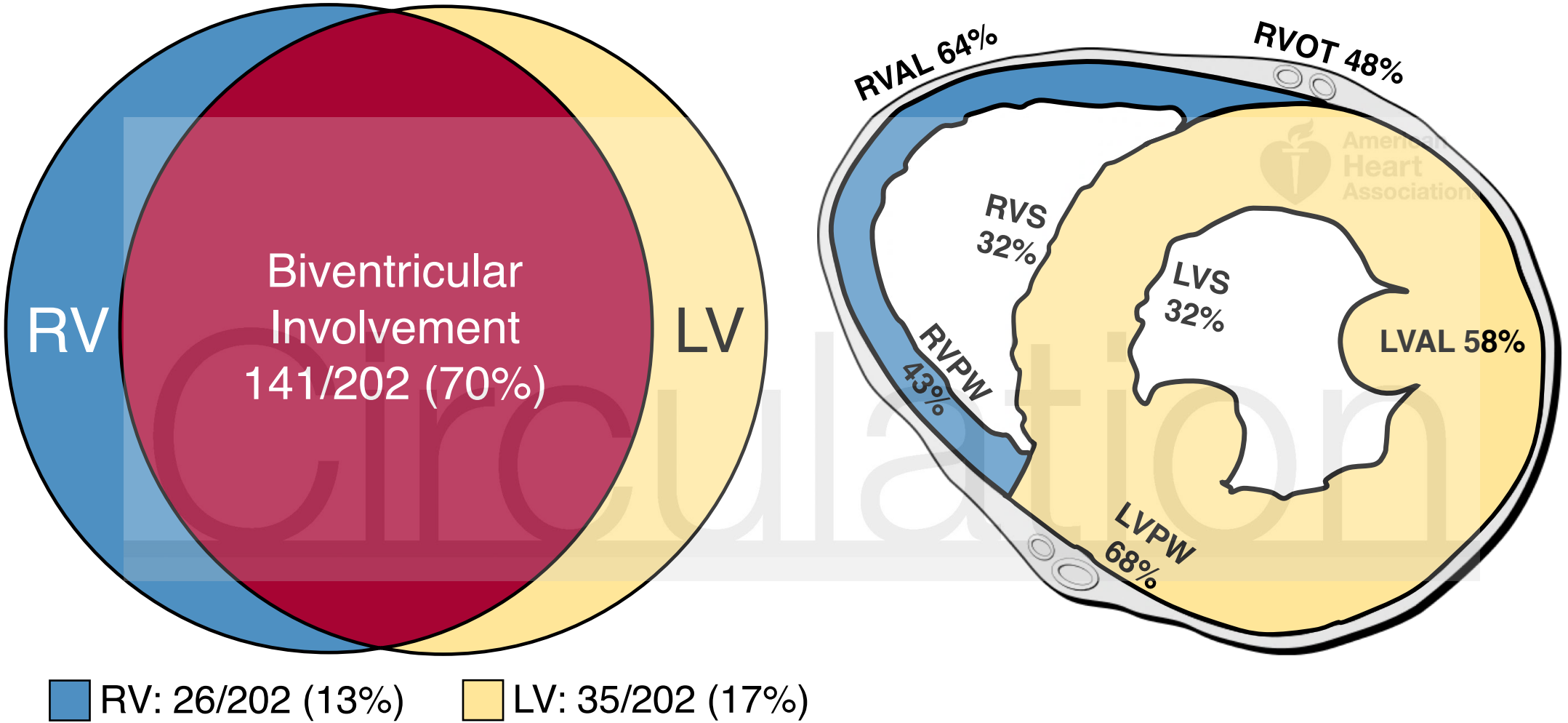

Downloaded from http://ahajournals.org by on February 7, 2019

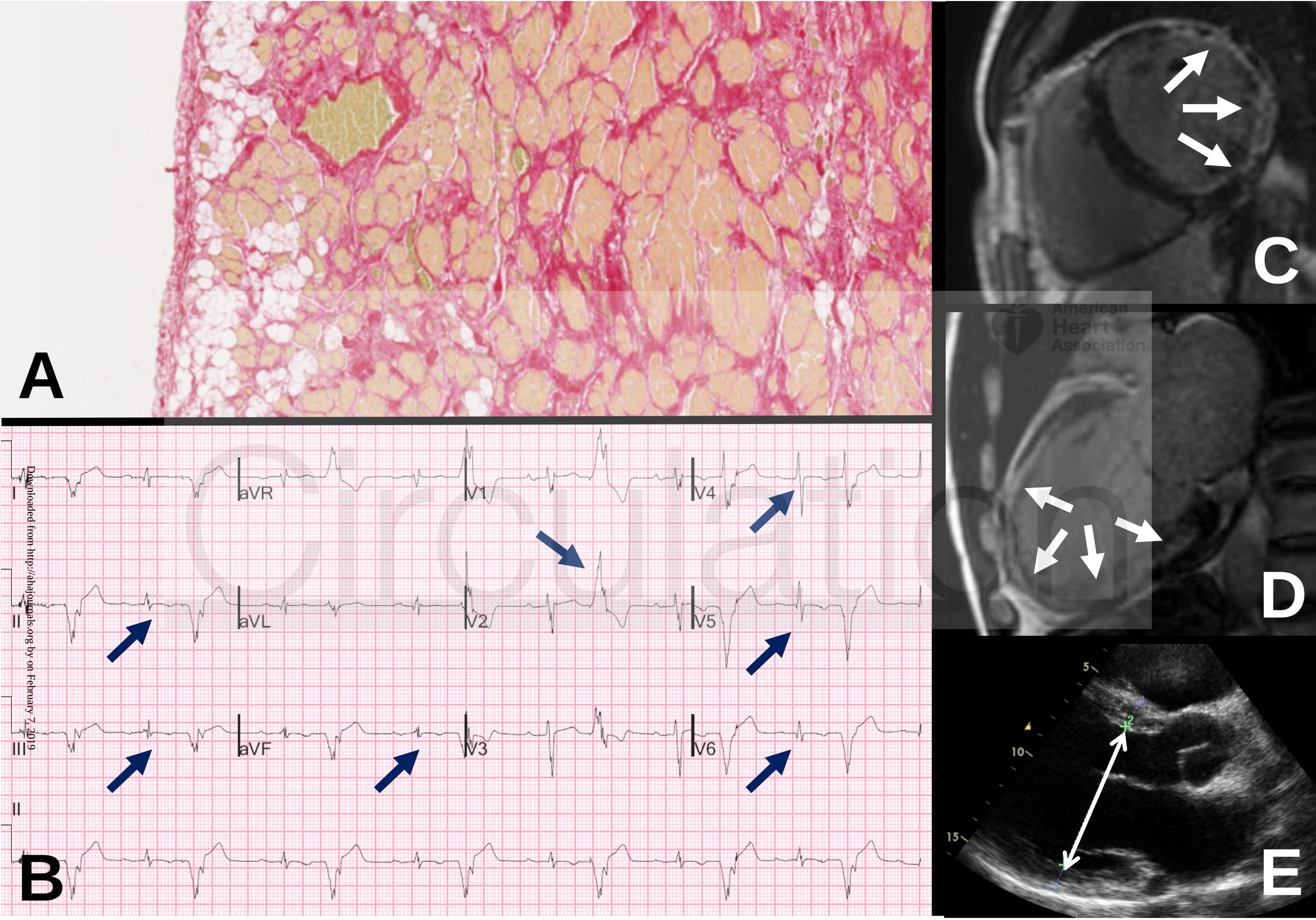

Downloaded from http://ahajournals.org by on February 7, 2019