

Arthroscopic Posterior Glenoid Fracture Fixation Using Knotless Suture Anchors



Jonathan A. Baxter, F.R.C.S.(Orth), James Tyler, F.R.C.S.(Orth),
Nivander Bhamber, M.R.C.S., Magnus Arnander, F.R.C.S.(Orth),
Eyiyemi Pearse, F.R.C.S.(Orth), and Duncan Tennent, F.R.C.S.(Orth)

Abstract: Shoulder instability after a posterior glenoid rim fracture is rare and potentially difficult pathology to treat. Operative techniques often involve a large dissection to view the fragments resulting in local soft tissue injury. Internal fixation is often achieved with interfragmentary screws; however, this may not be possible with small or multifragmentary fracture patterns. We describe an arthroscopic technique for posterior glenoid rim fracture fixation using knotless suture anchors. These anchors can be inserted without cannulas allowing easier access to the posterior glenoid. This procedure is simple, safe, and offers good visualization of the glenohumeral joint whilst avoiding the detrimental effects of larger surgical dissection.

Glenoid fractures involving the articular cavity are rare and usually seen in high-energy trauma.¹ Like anterior glenoid fractures, posterior fractures can lead to recurrent instability of the glenohumeral joint. Acute reduction and fixation of the fragment is indicated if the glenohumeral joint remains noncentered or an articular step of greater than 5 mm is present.² Traditional procedures to reduce and stabilize these fractures are usually performed through a posterior approach. This requires extensive dissection with the possibility of significant complications. Joint access is also limited through this approach. Arthroscopic techniques provide better visualization of the articular

surface, but often the fracture fragments are difficult to reduce and hold with percutaneous screws. We describe an arthroscopic technique for reduction and fixation of a displaced Ideberg type Ib posterior glenoid rim fracture using knotless anchors.³

Surgical Technique

Preoperative investigations include anteroposterior and axillary lateral radiographs and computed tomography scan to assess the extent of the fracture. The procedure is performed under general anesthesia and an interscalene brachial plexus block. The patient is placed in the lateral position as is standard practice for shoulder arthroscopy in our institution. The arm is positioned in 20° to 30° of forward flexion to improve the view of the posterior glenoid with the use of arm traction and 3.5 to 5 kg weight. The shoulder is prepared and draped in the normal fashion. A 30° arthroscope is introduced through a posterior portal and an anterior portal is made in the rotator interval using an outside-in technique (Video 1). A standard diagnostic arthroscopy is performed to ensure that there is no concomitant intra-articular pathology. A switching stick is used to reverse instruments and allow viewing of the posterior glenoid from the anterior portal.

An accessory superolateral portal is made perpendicular to the articular surface. The placement of this portal is planned using a spinal needle. The fracture is identified and mobilized in a similar fashion to that used for the posterior labrum during a labral repair

From the Orthopaedic Department, St George's Hospital, London, England.

The authors report the following potential conflicts of interest or sources of funding: J.A.B., J.T., N.B., M.A., and E.P. receive unrestricted financial support for training fellowship from Arthrex. D.T. receives consultancy fee from Arthrex; has patents (planned, pending, or issued) for Tightrope ACJ Technique from Arthrex; receives royalties from Arthrex; receives payment for development of educational presentations from Arthrex; and receives unrestricted financial support for training fellowship from Arthrex. Full ICMJE author disclosure forms are available for this article online, as [supplementary material](#).

Received March 29, 2017; accepted July 12, 2017.

Address correspondence to Duncan Tennent, F.R.C.S.(Orth), Orthopaedic Department, St George's Hospital, Blackshaw Road, London SW17 0QT, England. E-mail: Duncan@tennent.net

© 2017 by the Arthroscopy Association of North America. Published by Elsevier. This is an open access article under the CC BY-NC-ND license (<http://creativecommons.org/licenses/by-nc-nd/4.0/>).

2212-6287/17439

<http://dx.doi.org/10.1016/j.eats.2017.07.017>

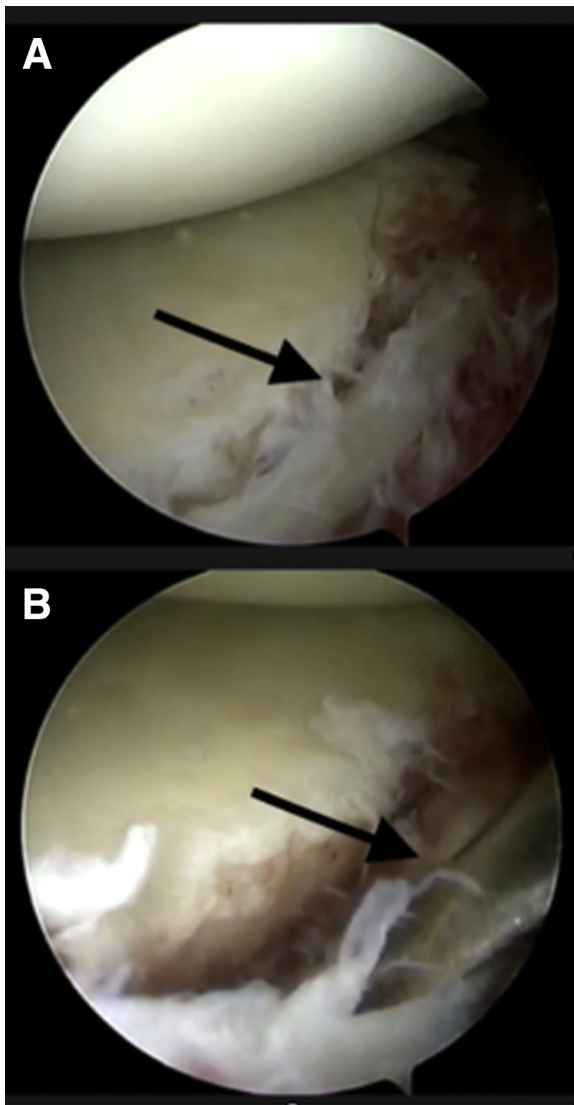


Fig 1. Fracture identification (A) (arrow) and mobilization using a soft tissue liberator. The patient is in the lateral position and the left shoulder is being operated on. The arthroscope has been introduced through the anterior portal to allow excellent visualization and enable instruments to be inserted through the posterior portal. Both surfaces are prepared using the arthroscopic rasp (B) (arrow). An arthroscopic shaver is avoided to limit damage to the posterior labrum. Adequate mobilization is confirmed when the fracture fragment can be reduced.

using an elevator and arthroscopic rasp to prepare the fracture surfaces (Fig 1). Care should be taken not to fragment larger fracture fragments. Fracture reduction can be achieved by manipulating the fragments using standard arthroscopic instruments. Reduction can be checked by probing the inferior margin of the fracture ensuring that it is flush with the glenoid neck.

After mobilization and reduction of the fracture fragments, a SutureTak anchor (Arthrex, Naples, FL) is inserted percutaneously below the inferior margin on

the glenoid neck via the posterior portal (Fig 2). The insertion site is determined by palpation to ensure that the cannulated drill guide sits below the limit of the fracture fragment. The pilot hole is drilled and anchor

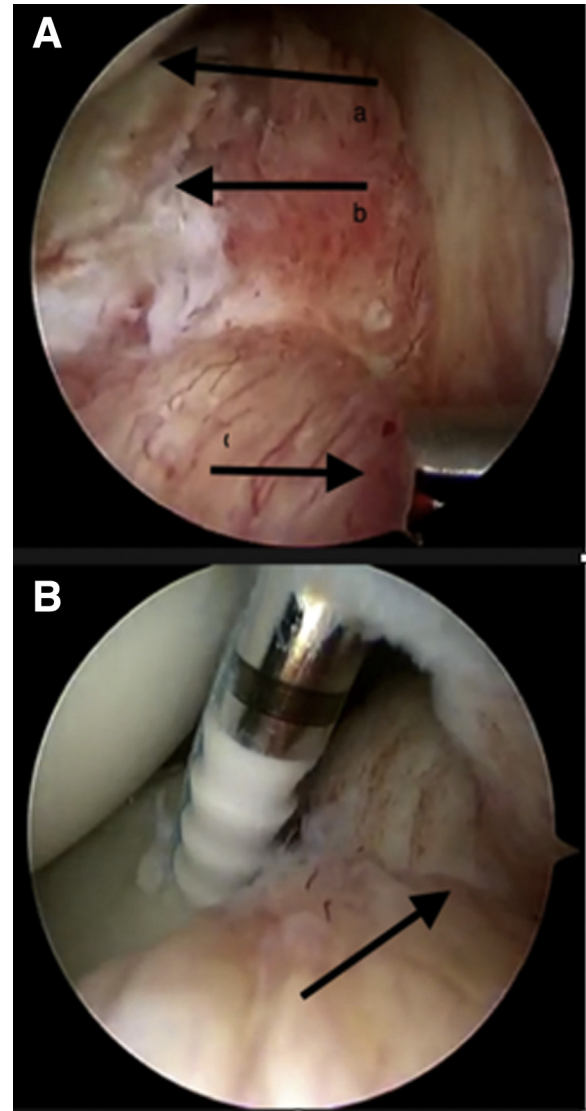


Fig 2. The patient is in the lateral position and the left shoulder is being operated on. The arthroscope has been introduced through the anterior portal. The drill guide is used to feel the reduction of the fragment medially along the glenoid neck (A, arrow c). To ensure the orientation, the posterior humeral head (A, arrow a) and fracture line (A, arrow b) are kept in view during placement. The pilot hole is drilled and a SutureTak anchor inserted medial to the fracture. One suture limb is withdrawn from the accessory superolateral portal. The drill guide is then inserted for a 2.9-mm PushLock anchor through this portal and a pilot hole is drilled in the glenoid face just beyond the articular extent of the fracture. The retrieved suture limb is secured with a 2.9-mm Bio-Composite PushLock anchor inserted through the same portal (B, arrow). It is important not to attempt to tension this suture as it will still run free in the anchor. This suture is cut flush.

inserted through the drill guide. Care must be taken to avoid displacing the drill guide before anchor insertion to ensure that the pilot hole remains aligned. One suture limb is then withdrawn from the accessory superolateral portal. The drill guide for a 2.9-mm PushLock anchor is then inserted through the same portal, and a pilot hole is drilled in the glenoid face just beyond the articular extent of the fracture. The retrieved suture limb is then secured with a 2.9-mm BioComposite PushLock anchor (Arthrex) inserted through the same portal. Care should be taken to ensure that the anchor is fully seated and not left proud. It is important not to attempt to tension with this anchor as the suture will still run free in the SutureTak anchor.

The second limb is withdrawn from the superolateral portal and secured with a second anchor further up the glenoid face in a superior direction. The suture configuration is tensioned during the insertion of this second anchor as the suture is still able to slide. It is important to ensure that the fragment is seated correctly before insertion of this second anchor. This suture is then cut flush completing the inferior construct (Fig 3). The process is repeated with a second SutureTak anchor inserted at the superior margin of the fragment on the glenoid neck. The third and fourth PushLock anchors are inserted further up the glenoid face to secure the superior margin of the fracture (Fig 3). A summary of the key points is included in Table 1. The wounds are closed and the arm placed in a sling for comfort allowing free movement below 90° for 6 weeks as per our normal regime for posterior labral repair.

Discussion

Posterior glenoid fractures although rare can lead to recurrent instability. The degree to which articular incongruity leads to poor outcome and the development of post-traumatic arthritis remains unclear; however, minimally displaced fractures without further involvement of the shoulder girdle can be managed conservatively with good functional results.⁴ Indications for operative intervention include radiological instability diagnosed by a noncentered humeral head and an articular step of greater than 5 mm.²

Posterior Ideberg type Ib fractures are commonly treated with open reduction and internal fixation through the posterior Judet approach or modifications thereof.⁵ This approach offers access from the acromion to the inferior margin of the scapula. The deltoid muscle must be sharply dissected to identify the plane between infraspinatus and teres minor. This requires a significant amount of soft tissue dissection and does not always offer a clear view of the articular surface. Reduction and fixation of the fragment with screws can result in joint penetration, fragmentation, and hardware irritation.

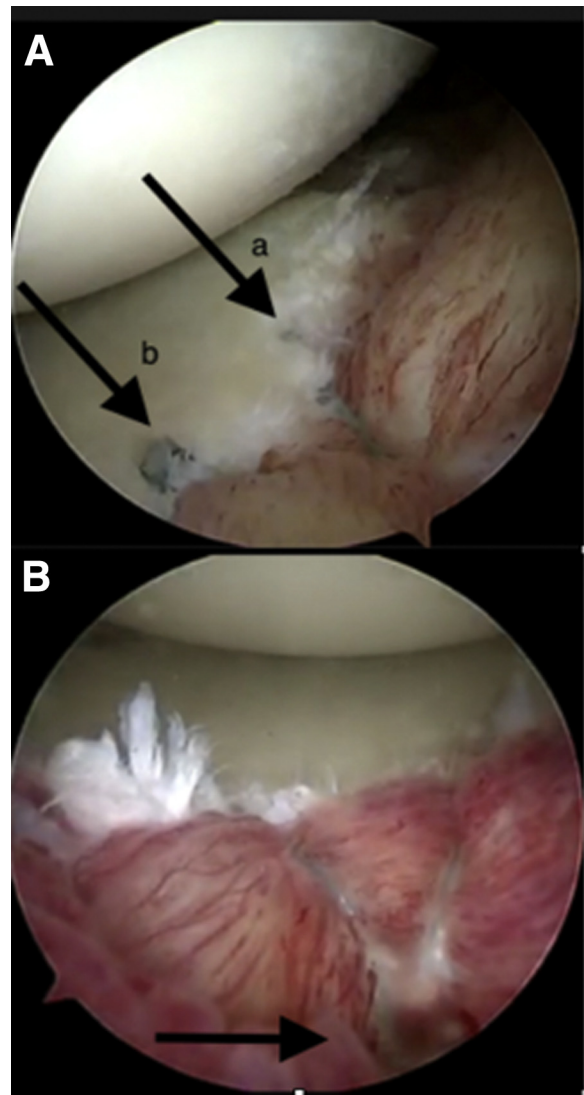


Fig 3. The patient is in the lateral position and the left shoulder is being operated on. The arthroscope has been introduced through the anterior portal. The second limb is withdrawn from the superolateral portal and secured with a second 2.9-mm PushLock anchor inserted further around the glenoid face in a superior direction (A, arrow b). Ensure that an adequate bone bridge is left between the first (A, arrow a) and second anchors. The suture configuration is tensioned during the insertion of this second anchor as the suture is still able to slide. It is important to ensure that the fragment is seated correctly before insertion of this second anchor. The process is repeated superiorly. The final construct consists of an inferior (A) and superior (B) suture anchor configuration that maximizes the area of compression across the fracture site.

The arthroscopic or arthroscopic-assisted technique can offer less tissue damage during dissection, reduced risk to blood supply of the fragments, and better visualization of the articular surface. It also allows for formal assessment of the glenohumeral joint to identify associated injuries including labrocapsular injuries that can be addressed at the same time.

Table 1. Tips, Pearls, Pitfalls, Key Points, Indications, Contraindications, and Risks

Tips
<ul style="list-style-type: none"> • Position the patient more prone than usual and flex the arm more; this will increase the exposure of the posterior joint • Use a spinal needle to plan the superolateral portal position carefully to access the posterior fracture
Pearls
<ul style="list-style-type: none"> • Have a grasping retriever and a loop retriever available for suture management • Palpate the inferior aspect of the fracture to ensure reduction before SutureTak insertion • Complete each repair before inserting the next anchor
Pitfalls
<ul style="list-style-type: none"> • Preparing the fracture site with the shaver can be difficult; consider using the soft tissue liberator and rasp • Do not tension the first limb as it will slide and could unload the anchor. The construct is tensioned with the insertion of the second anchor
Key points
<ul style="list-style-type: none"> • Carefully check all access with a spinal needle before starting and adjust the arm position accordingly • Pay attention to suture management to avoid soft-tissue bridges • Ensure fracture reduction by visualizing the joint surface and probing the fragment medially on the glenoid neck
Indications
<ul style="list-style-type: none"> • Posterior glenoid rim fractures resulting in instability
Contraindications
<ul style="list-style-type: none"> • Evidence of significant bone loss. Larger fracture patterns with extension to the glenoid neck
Risks
<ul style="list-style-type: none"> • The risks are similar to those of knotless posterior shoulder stabilization • There is relative proximity to the axillary nerve at the inferior aspect of the visualized field

Bauer et al.⁶ in 2006 described an arthroscopic technique for glenoid rim fractures. They described fixation of Ideberg type Ia fractures with sutures passed anterior to posterior through glenoid neck drill holes tied over the infraspinatus fascia. In the instance of a posterior or combined anterior and posterior glenoid fracture, the sutures were tied whilst the posterior fragment was held reduced by a probe from an accessory portal. In the described series of 4 patients, good function and pain scores were reported at 2 to 4 years' follow-up.

Helling et al.⁷ in 2002 described the treatment of 2 Ideberg Ia glenoid fractures with suture anchors loaded with monofilament. One anchor was placed cranial and

one caudal to the fragment that was then reduced anatomically along with the labrum. They reported excellent functional outcomes at minimum 32 months' follow-up. For Ideberg type II and III fractures they recommended screw fixation.

The use of anchors reduces the likelihood of penetration into the joint or splitting smaller fragments during screw insertion. We believe that the suture anchor configuration as described in this report allows for a more universal spread of compression across the fracture fragment and more secure fixation. In addition, the use of knotless anchors avoids knot migration and abrasion of the humeral head.⁸

In conclusion, arthroscopic reduction and fixation with knotless suture anchors offers a minimally invasive alternative for the treatment of displaced posterior glenoid fractures. We recommend the described technique as a simple and safe solution avoiding the need for extended surgical dissection and screw fixation.

References

1. Yang HB, Wang D, He XJ. Arthroscopic-assisted reduction and percutaneous cannulated screw fixation for Ideberg type III glenoid fractures: A minimum 2-year follow-up of 18 cases. *Am J Sports Med* 2011;39:1923-1928.
2. Bauer G, Fleischmann W, Dussler E. Displaced scapular fractures: Indication and long-term results of open reduction and internal fixation. *Arch Orthop Trauma Surg* 1995;114:215-219.
3. Ideberg R, Grevsten S, Larsson S. Epidemiology of scapular fractures. Incidence and classification of 338 fractures. *Acta Orthop Scand* 1995;66:395-397.
4. Kligman M, Roffman M. Glenoid fracture: Conservative treatment versus surgical treatment. *J South Orthop Assoc* 1998;7:1-5.
5. Judet R. Surgical treatment of scapular fractures. *Acta Orthop Belg* 1964;30:673-678.
6. Bauer T, Abadie O, Hardy P. Arthroscopic treatment of glenoid fractures. *Arthroscopy* 2006;22:569.e1-569.e6.
7. Helling HJ, Isenberg J, Andermahr J, Rehm KE. Minimally invasive surgery of glenoid fractures. *Eur J Trauma* 2002;28:247-251.
8. Kim SH, Crater RB, Hargens AR. Movement-induced knot migration after anterior stabilization in the shoulder. *Arthroscopy* 2013;29:485-490.