

Expert Opinion

European association of perinatal medicine (EAPM) position statement: Screening, diagnosis and management of congenital anomalies of the umbilical cord

Eric Jauniaux^{a,*}, Cathrine Ebbing^b, Yinka Oyelese^c, Rony Maymon^d, Federico Prefumo^e, Amar Bhide^f

^a EGA Institute for Women's Health, Faculty of Population Health Sciences, University College London (UCL), London, UK

^b Department of Obstetrics and Gynecology, Haukeland University Hospital and Department of Clinical Science, University of Bergen, Bergen, Norway, Norway

^c Division of Maternal Fetal Medicine, Department of Obstetrics and Gynecology, Beth Israel Deaconess Medical Center and Harvard Medical School, Boston, MA, USA

^d Department of Obstetrics and Gynecology, The Yitzhak Shamir Medical Center Israel, Sackler Faculty of Medicine, Tel Aviv University, Tel Aviv, Israel

^e Obstetrics and Gynaecology Unit, IRCCS Istituto Giannina Gaslini, Genova, Italy

^f Fetal Medicine Unit, Department of Obstetrics and Gynecology, St. George's Hospital, UK



ARTICLE INFO

Keywords:

Umbilical cord
Congenital anomalies
Fetal anomalies
Ultrasound imaging
Screening
Perinatal complications

ABSTRACT

Congenital anomalies of the umbilical cord are associated with an increased risk of pregnancy and perinatal complications. Some anomalies of the cord have a higher prevalence than other fetal structural anomalies. The most common anomalies are the absence of an umbilical artery and velamentous insertion of the cord (with or without vasa previa). These anomalies, even when not associated with fetal structural defects, increase the risk of adverse perinatal outcome including, fetal growth restriction and stillbirth. In the absence of prenatal diagnosis, vasa previa is associated with the highest perinatal morbidity and mortality of all congenital anomalies of the umbilical cord. Most cases can be detected by ultrasound from the beginning of the second trimester and should be included in the routine mid-pregnancy ultrasound examination. Documentation should include cord insertion site, number of vessels in the cord, and if other pathologies have been detected. Pregnancies at increased risk of velamentous cord insertion should be screened for vasa previa using transvaginal ultrasound and colour Doppler imaging. If a velamentous cord insertion or isolated single umbilical artery is detected, individualised follow-up during pregnancy and tailored obstetric management are indicated.

Introduction

The umbilical cord plays an essential role in fetal development and abnormalities of the cord have the potential to lead to impaired oxygenation and nutrition to the fetus, which may in turn lead to both short- and long-term adverse outcomes including cerebral palsy (CP) and perinatal death [1,2]. Some congenital abnormalities of the cord are also associated with a variety of fetal structural defects and genetic conditions. However, examination of the cord has never been given the same attention as the fetus during routine antenatal ultrasound scanning [3,4]. Overall, ultrasound examination of the placenta and the umbilical cord is not standardised and not included in clinical protocols or obstetric ultrasound training programs [5]. In addition, most data regarding outcomes and management of umbilical cord abnormalities

detected on prenatal ultrasound are observational, often not confirmed at birth, and thus data are subject to considerable bias.

Assisted reproductive technologies and in particular in-vitro fertilisation (IVF), are associated with increased risks of congenital umbilical cord abnormalities [6,7]. The worldwide increase in the number of pregnancies conceived with IVF means that the incidence of these abnormalities and associated perinatal complications is likely increase. Currently, there is no consensus on the antenatal screening of some congenital abnormalities of the umbilical cord and on the management of those diagnosed prenatally. In order to ensure optimal perinatal outcomes, it is important that those providing routine obstetric ultrasound imaging are aware of the spectrum of congenital cord abnormalities, their background epidemiology, sonographic appearance at the mid-pregnancy detailed fetal anatomy scan, clinical significance and

* Corresponding author.

E-mail address: e.jauniaux@ucl.ac.uk (E. Jauniaux).

<https://doi.org/10.1016/j.ejogrb.2024.04.044>

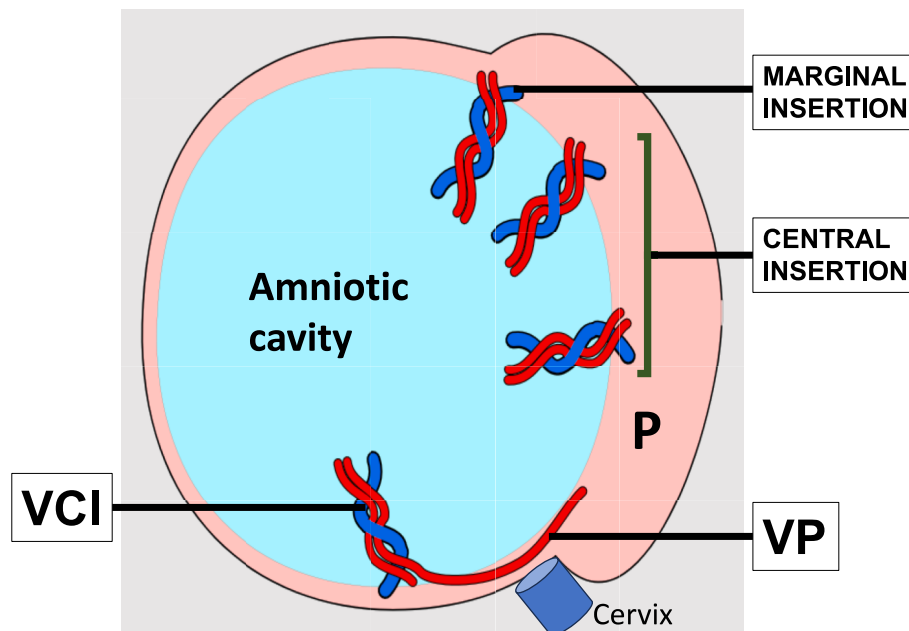


Fig. 1. Diagram showing the different possible position of the umbilical cord insertion within and outside the placental (P) chorionic plate.

management. Furthermore, health care providers should be trained in how to communicate these findings to patients without causing undue alarm.

The present position statement was developed by the European Association of Perinatal Medicine's special interest group on "Placental and cord anomalies", using regular online exchanges and shared-document iterations to achieve a consensus. The scope of this statement is to review the evidence-based data on ultrasound imaging and management of congenital abnormalities that can be screened for at the routine mid-pregnancy ultrasound scan. Secondary anomalies such as cord knots, abnormal cord coiling or excessively long cord can often only be identified in the third trimester and their clinical value is still under investigation, and therefore they are not included in this statement. The document was subsequently approved by the EAPM Executive Board.

Single umbilical artery

A single umbilical artery (SUA) is one of the most common fetal congenital abnormalities and is reported in approximately 0.5–1 % of pregnancies [8,10]. It was first reported by Vesalius (1514–1564) and its association with other fetal congenital malformations and poor fetal growth has been known for over 60 years [9].

A Norwegian population-based study reported a prevalence of SUA of 1/218 (0.46 %) singleton pregnancies. Increasing odds of SUA at birth were found with maternal parity ≥ 4 , smoking, conception by assisted reproduction and a history of diabetes and epilepsy, chronic hypertension and previous cesarean delivery [10]. The incidence of associated congenital fetal malformation was 10.9 % in the SUA group compared to 0.65 % in fetuses with a 3-vessel umbilical cord. A strong association was found in that population between a SUA and neonatal gastrointestinal atresia or stenosis (Odd Ratio (OR) 25.8; 95 % confidence interval [CI], 17.0–39.1), oesophageal and anorectal atresia or stenosis (OR 20.3; 95 % CI, 3.4–30.9) and renal agenesis (OR 5.9; 95 % CI, 1.9–18.5). SUA was also associated with a 2–8 times higher risk of congenital heart defects [10]. The association with trisomy 18 (OR 14.4; 95 % CI, 9.3–22.4) and 13 (OR 13.6; 95 % CI, 6.7–27.8) is strong, but this is due to the association between these chromosomal abnormalities and the above mentioned congenital fetal malformations. The incidence of SUA is three times greater in twins than in singletons (3 % vs 1 %) but similar in monochorionic (MC) and dichorionic (DC) twins [11,12]. Twins with

SUA are at a higher risk for other congenital malformations, similarly to what is observed in singletons [8,12]. A SUA is found in all cases of sirenomelia and acardiac twin, and this is often referred in those cases as the SUA syndrome [8]. Patients presenting with SUA in a singleton or multiple pregnancy and a fetal congenital malformation should be referred to a specialised fetal medicine unit (FMU) for further investigations, including fetal karyotyping.

Around two-thirds of fetuses presenting with a SUA have no other anomalies and are referred to as having an isolated SUA (iSUA) [13]. Overall, singleton fetuses with iSUA are at increased risk of adverse perinatal outcome (OR 5.06; 95 % CI 4.26–6.02), intrauterine fetal death and perinatal death (OR 5.62, 95 % CI 4.69–6.73) [14] and should therefore be managed with increased attention. Approximately half of singleton and twin pregnancies with iSUA are also at increased risk of becoming small-for-gestational-age (SGA) neonates [12,14,15]. Laterality of the missing artery was not associated with SGA [15,16]. A recent systematic review and meta-analysis [13] including three retrospective cohort and eight retrospective case-control studies, reporting on 1,533 cases of iSUA cases, confirms a higher risk of delivering SGA neonates (OR 2.90; 95 % CI 2.02–4.18). Pregnancies with SUA, with or without an associated malformation, have a 2-fold increased risk for SUA in a subsequent pregnancy [10].

The first ultrasound diagnosis of two fetuses with a SUA was reported in the third trimester by Jassani et al in 1980 [17]. The development of colour Doppler imaging has improved the accuracy of the diagnosis, and made this possible from the end of the first trimester [18]. A recent Danish cohort study including 116,501 singleton pregnancies consecutively enrolled in first trimester screening for aneuploidies and mid-trimester anomaly scan reported that associated abnormalities were found at a later date (most commonly after birth) in 4.3 % of what were believed to be isolated cases of SUA, 1.5 % of which were minor congenital cardiovascular malformations [15]. A recent practice guideline from the Society for Maternal-Fetal Medicine recommends no additional evaluation for aneuploidy in fetuses with iSUA, regardless of whether results of previous aneuploidy screening were low risk or testing was declined [19]. The guideline also recommends that if a heart examination is normal, it is not necessary to perform detailed fetal echocardiography. The association between iSUA, fetal death and SGA in both singleton and twin pregnancies [11–16], supports an assessment of fetal growth during the third trimester. A recent study found that a

diameter of > 3.1 mm for the single umbilical artery at 20–22 weeks of gestation was associated with a lower risk of SGA, suggesting that this cut-off could be used to identify fetuses at risk of abnormally slow growth in the third trimester of pregnancy [16]. Patients presenting with a fetus diagnosed with iSUA at the mid-pregnancy scan and SGA in the third trimester should with be referred for follow-up to a specialist FMU.

Abnormalities of the cord insertion and vasa previa

Normally, the umbilical cord inserts directly into the chorionic or fetal plate of the placenta and the umbilical vessels are protected by Wharton's Jelly for their entire length (Fig. 1). A velamentous cord insertion (VCI) describes an umbilical cord insertion into the free membranes i.e. outside the chorionic or fetal plate of the placenta [20–23]. This entity is associated with umbilical vessels running freely from the base of the cord on the membranes until they connect with the chorionic vessels of the placental edge. Connecting vessels of a VCI are unprotected for a variable distance and thus at risk of rupture. Marginal insertions of the cord are more common than velamentous insertions, but less likely to be associated with free running vessels [21]. There is a lack of consistency in the definition of a marginal cord insertion, with distances from the placental edge of 1 to 2.5 cm being frequently used [22]. Furthermore some "marginal" cord insertions are in reality velamentous insertions, making the true significance of a marginal cord insertion difficult to ascertain. A "furcate" cord insertion is a rare abnormality where the umbilical vessels separate before reaching the placenta losing the protection of Wharton's jelly for a variable length. This anomaly has been described on ultrasound imaging [23] but may be difficult to distinguish from a VCI, in particular when the furcate cord is inserted into the placenta eccentrically or marginally. Overall, the prevalence of abnormal cord insertions (marginal or velamentous) in singleton pregnancies is around 7.8 % [21] (of which 1.5 % are velamentous). In twin pregnancies, the prevalence is around 16.8 % (of which 5.9 % are velamentous) [21]. The incidence of VCI is increased in pregnancies conceived with IVF [5–7,20,21], which also increases the incidence of low placentation and there is a direct association between low-lying placenta/placenta previa and VCI [7,28].

Vasa previa (VP) refers to the presence of chorionic vessels unsupported by Wharton's jelly traversing the membranes over, or in proximity to the internal cervical os [20,24]. Three types of VP have been described: Type I: Unsupported vessels connect the VCI to the placenta, Type II: Free vessels connect the main placental mass to a succenturiate lobe and Type III: Free vessels running in the membranes at the edge of the placenta. A recent systematic review and meta-analysis of 12 studies reporting prenatal diagnosis with systematic screening of VP, including 1320 pregnancies with this diagnosis in a total population of 2 278 561 unselected pregnancies [25], reported an incidence of 1 in 1218 pregnancies (weighted pooled incidence per 1000 pregnancies 0.79; 95 % CI: 0.59 to 1.01). The data from this study highlight the fact that VP is more common than previously reported. The distribution of the different types of VP in the general population has not been clearly defined, but reported cases of type III are uncommon with 18 cases reported in a recent systematic review of the international literature [26]. The incidence of the other types of VP has probably increased over the last two decades due to increasing number of pregnancies resulting from assisted reproduction (OR 19; 95 %CI 6.6–54) [27], mainly in vitro fertilisation, which is associated with a high incidence of VCI and placentation in the lower segment, and more rarely with abnormalities of placental shape [28]. Overall, around 2/3 of VP are associated with a VCI, in both singleton and twin pregnancies [20,24,29].

A VCI is also associated with an increased risk of pre-labour rupture of membranes (OR 1.6, 95 % CI 1.5–1.7), preterm pre-labour rupture of membranes (OR 2.7, 95 % CI 2.4–3.0) and spontaneous preterm birth (OR 2.0, 95 % CI 1.9–2.2) [30]. Excluding cases with VP, VCI in singleton pregnancies is associated with an increased risk of SGA neonates (RR 2.69; 95 % CI 1.73–4.17) and stillbirth (RR 9.42; 95 % CI

3.19–27.76) [31,32]. Overall, in singleton pregnancies, a VCI carries an increased risk of cerebral palsy, regardless of the gestational age at delivery or fetal sex (adjusted RR (aRR) 2.11; 95 % CI, 1.65–2.60) [2] and the risk of perinatal death at term is tripled, (OR 3.3; 95 % CI 2.5–4.3) [21]. Patients diagnosed with a VCI on second-trimester ultrasound, presenting with a risk of preterm delivery and/or abnormal fetal growth should be referred to a specialist FMU for follow-ups. In monozygotic twins with and without twin-to-twin transfusion syndrome (TTTS), a VCI is associated with a high risk (OR 4.76; 95 % CI 2.43–10.47 and OR 4.52; 95 % CI 1.30–28.59, respectively) of severe growth discordance [33].

Compared to normal placental cord insertion, a VCI is associated with a 5.6 % risk of manual removal of the placenta at vaginal delivery (OR 5.21; 95 % CI 4.71–5.76) and an increased risk of postpartum hemorrhage (OR 2.06; 95 % CI 1.77–2.39) [33].

When undiagnosed prenatally, VP is associated with the highest perinatal morbidity and mortality of all congenital anomalies of the umbilical cord, because of the risk of vessel rupture during labor. A review published in 1952 [34], prior to the advent of prenatal ultrasound scanning, found a perinatal mortality rate of 55 % associated with VP. This finding was confirmed in 2004 by a large population study, which showed a perinatal mortality of 56 % in cases not diagnosed prenatally [35]. A recent systematic review and meta-analysis of seven studies that included cases of VP, with and without a prenatal diagnosis, found a 25-fold higher risk of perinatal death (OR 25.39; 95 % CI 7.93–81.31) and 50-fold higher risk of neonatal hypoxic morbidity (OR 50.09; 95 % CI 17.33–144.79) when the diagnosis was not made antenatally [36].

When performed by a trained operator, screening and diagnosis of cord insertion abnormalities is highly accurate, with a detection rate of around 99 % [20,24,37,38]. Transvaginal sonography is essential for the diagnosis of VP, and together with colour Doppler it diagnosed all cases of VP during the second trimester (sensitivity, 100 %) with a specificity of 99.0–99.8 % [38]. Routine screening for VP in all pregnancies remains controversial [20]. However, targeted screening for VP in high-risk patients has been shown to improve both maternal and neonatal obstetric outcomes [30,39]. Detection of a VCI and/or a VP at the routine second-trimester scan should lead to follow-up scans in a specialised FMU, including transvaginal scans to determine placental cord insertion and/or the position of the VP in relation with the internal cervical os, as well as cervical length to assess the risk of spontaneous preterm delivery [20,24,29].

Rare congenital anomalies of the umbilical cord

Cysts of the umbilical cord may be true cysts, which arise from the allantois or omphalo-mesenteric duct, or pseudocysts, which result from localized liquefaction of Wharton's jelly. The prevalence of umbilical cord cysts varies through gestation, with around 3 % of pregnancies reported as having umbilical cord cysts in the first trimester [40]. Umbilical cord cysts found early in pregnancy are associated with a fetal chromosomal or structural defect in 20 % of the cases [40]. The diagnosis of an umbilical cord cyst associated with sonographic fetal abnormalities in the second and third trimesters should be an indication for fetal karyotype testing, and these patients should therefore be referred to a specialist FMU [41].

Other rare congenital anomalies of the umbilical cord such as pseudocysts, angiomyxoma (a very rare benign vascular tumour of the umbilical cord), umbilical vein varix, umbilical cord stricture and supernumerary vessels in the cord, have been associated with fetal structural defects and perinatal complications [42]. However, these associations may be biased because of the propensity to report abnormal cases [41]. Referral to a specialist FMU is also indicated in these situations.

Table 1

Characteristics of the main congenital abnormalities of the umbilical cord that can be identified at the mid-pregnancy detailed fetal ultrasound examination.

Anomaly	Prevalence	Risks factors	Perinatal complications	Management
SUA	0.5–1 % of singleton pregnancies (3 % of twins)	Maternal parity ≥ 4 , smoking, ART conception, multiple pregnancies, and history of diabetes epilepsy, chronic hypertension and previous CD.	¶ 10.9 % of fetuses with SUA have an associated congenital malformation mainly gastrointestinal atresia or stenosis, oesophageal and anorectal atresia or stenosis, renal agenesis and congenital heart defects. ¶ iSUA is associated with an increased risk of SGA and IUFD in the third trimester.	¶ Referral to a specialist FMU for further investigation including karyotyping. ¶ Referral to a specialist FMU for follow-up if SGA.
VCI	1.5 % of singleton pregnancies (5.9 % of twins)	ART/IVF	PROM, preterm birth, SGA, IUFD, cerebral palsy, manual removal of the placenta and PPH.	Referral to a specialist FMU for follow-up if SGA or risk of preterm delivery.
VP	1 in 1218 pregnancies	ART/IVF VCI	Intrapartum death and neonatal hypoxic morbidity.	Referral to a specialist FMU for follow-up.

SUA = single umbilical artery; iSUA = isolated single umbilical artery CD = cesarean delivery; ART = assisted reproductive technologies; FMU = fetal medicine unit; IUFD = intrauterine fetal death; SGA = small-for-gestational-age; VCI = velamentous cord insertion; IVF = In-vitro fertilisation. PPH = postpartum hemorrhage; PROM = pre-labor rupture of membranes.

Recommendations

Awareness and identification of congenital abnormalities of the umbilical cord at the time of the second-trimester ultrasound scan can help healthcare professionals inform patients about perinatal risks and management options, and together with appropriate management, can lead to improve perinatal outcomes (Table 1). Sonographic assessment of the umbilical cord insertion into the placenta, as well as documentation of the number of umbilical arteries is recommended. Pregnancies at increased risk of VCI should be screened for VP using transvaginal ultrasound and colour Doppler imaging. Congenital anomalies of the umbilical cord, even when not associated with fetal structural defects, increase the risk of adverse perinatal outcome, including fetal growth restriction and stillbirth.

Follow-up in specialised FMU is recommended in pregnancies at higher risk of perinatal complications, such as those presenting with an iSUA and SGA, or VP. Patients with an SUA and a normal fetal growth at the 34–35 weeks growth scan do not require additional follow-up. Similarly, patients with a VCI diagnosed at the mid-pregnancy detailed fetal anatomy scan should have a follow-up ultrasound examination at the end of the second trimester to exclude a VP and assess fetal growth and cervical length. Further specialist follow-up should be tailored according to the findings at that scan. Further studies are needed to determine the significance and optimal management of other less common congenital and secondary abnormalities of the umbilical cord such as cord knot and nuchal cord.

Funding

No funding was obtained for this study.

The authors declare that they have no known competing financial interests or personal relationships that could have appeared to influence the work reported in this article.

Declaration of competing interest

The authors declare that they have no known competing financial interests or personal relationships that could have appeared to influence the work reported in this paper.

References

- [1] Oyelese Y. Placenta, umbilical cord and amniotic fluid: the not-less-important accessories. *Clin Obstet Gynecol* 2012;55:307–23.
- [2] Ebbing C, Rasmussen S, Kessler J, Moster D. Association of placental and umbilical cord characteristics with cerebral palsy: national cohort study. *Ultrasound Obstet Gynecol* 2023;61:224–30.
- [3] Sepulveda W. Time for a more detailed prenatal examination of the umbilical cord? *Ultrasound Obstet Gynecol* 1999;13:157–60.
- [4] Sherer DM, Manning FA. Prenatal ultrasonographic diagnosis of nuchal cord(s): disregard, inform, monitor or intervene? *Ultrasound Obstet Gynecol* 1999;14:1–8.
- [5] Jauniaux E, Silver RM. Rethinking prenatal screening for anomalies of placental and umbilical cord implantation. *Obstet Gynecol* 2020;136:1211–6.
- [6] Cochran E, Pando C, Kirschen GW, Soucier D, Fuchs A, Garry DJ. Assisted reproductive technologies (ART) and placental abnormalities. *J Perinat Med* 2020;48:825–828.
- [7] Larcher L, Jauniaux E, Lenzi J, Ragnedda R, Morano D, Valeriani M, et al. Ultrasound diagnosis of placental and umbilical cord anomalies in singleton pregnancies resulting from in-vitro fertilization. *Placenta* 2023;131:58–64.
- [8] Heifetz SA. Single umbilical artery. A statistical analysis of 237 autopsy cases and review of the literature. *Perspect Pediatr Pathol* 1984;8:345–78.
- [9] Lemoski EF, Medovy H. Single umbilical artery: incidence, clinical significance and relation to autosomal trisomy. *Can Med Assoc J* 1962;87:1229–31.
- [10] Ebbing C, Kessler J, Moster D, Rasmussen S. Single umbilical artery and risk of congenital malformation: population-based study in Norway. *Ultrasound Obstet Gynecol* 2020;55:510–5.
- [11] Klatt J, Kuhn A, Baumann M, Raio L. Single umbilical artery in twin pregnancies. *Ultrasound Obstet Gynecol* 2012;39:505–9.
- [12] Stout MJ, Odibo AO, Longman R, Shanks AL, Cahill AG. The incidence of isolated single umbilical artery in twins and adverse pregnancy outcomes. *Prenat Diagn* 2013;33:269–72.
- [13] Dagklis T, Siargkas A, Apostolopoulou A, Tsakiridis I, Mamopoulos A, Athanasiadis A, et al. Adverse perinatal outcomes following the prenatal diagnosis of isolated single umbilical artery in singleton pregnancies: a systematic review and meta-analysis. *J Perinat Med* 2021;50:244–52.
- [14] Ebbing C, Kessler J, Moster D, Rasmussen S. Isolated single umbilical artery and the risk of adverse perinatal outcome and third stage of labor complications: A population-based study. *Acta Obstet Gynecol Scand* 2020;99:374–80.
- [15] Rechnagel AA, Jørgensen FS, Ekelund CK, Zingenberg H, Petersen OB, Pihl K. Risk of adverse pregnancy outcome in isolated single umbilical artery diagnosed at the mid-trimester anomaly scan: a large Danish retrospective cohort study. *J Matern Fetal Neonatal Med* 2023;36:2239982.
- [16] Contro E, Larcher L, Lenzi J, Valeriani M, Farina A, Jauniaux E. Changes in artery diameters and fetal growth in cases of isolated single umbilical artery. *Diagnostics (Basel)* 2023;13:571.
- [17] Jassani MN, Brennan JN, Merkatz IR. Prenatal diagnosis of single umbilical artery by ultrasound. *J Clin Ultrasound* 1980;8:447–8.
- [18] Jauniaux E, Campbell S, Vyas S. The use of color Doppler imaging for prenatal diagnosis of umbilical cord anomalies: report of three cases. *Am J Obstet Gynecol* 1989;161:1195–7.
- [19] Prabhu M, Kuller JA, Biggio JR. Society for Maternal-Fetal Medicine Consult Series #57: Evaluation and management of isolated soft ultrasound markers for aneuploidy in the second trimester: (Replaces Consults #10, Single umbilical artery, October 2010; #16, Isolated echogenic bowel diagnosed on second-trimester ultrasound, August 2011; #17, Evaluation and management of isolated renal pelviectasis on second-trimester ultrasound, December 2011; #25, Isolated fetal choroid plexus cysts, April 2013; #27, Isolated echogenic intracardiac focus, August 2013). *Am J Obstet Gynecol* 2021;225:B2–15.
- [20] Jauniaux E, Alfrevic Z, Bhide AG, Burton GJ, Collins SL, Silver R. Royal college of obstetricians and gynaecologists. *Vasa praevia: diagnosis and management: green-top guideline No. 27b*. *BJOG*. 2019;126:e49–61.
- [21] Ebbing C, Kiserud T, Johnsen SL, Albrechtsen S, Rasmussen S. Prevalence, risk factors and outcomes of velamentous and marginal cord insertions: a population-based study of 634,741 pregnancies. *PLoS One* 2013;8:e70380.
- [22] Wax IR, Cartin A, Craig WY, Pinette MG, Wax JR. Second-trimester ultrasound-measured umbilical cord insertion-to-placental edge distance: Determining an outcome-based threshold for identifying marginal cord insertions. *J Ultrasound Med* 2020;39:351–8.

- [23] Smith M, McCullum B. Furcate umbilical cord insertion with a bilobed placenta identified on prenatal ultrasonography. *Australas J Ultrasound Med* 2022;25:98–102.
- [24] Oyelese Y, Lees CC, Jauniaux E. The case for screening for vasa previa: time to implement a life-saving strategy. *Ultrasound Obstet Gynecol* 2023;61:7–11.
- [25] Zhang W, Giacchino T, Chanyarungrojn PA, Ionescu O, Akolekar R. Incidence of vasa praevia: a systematic review and meta-analysis. *BMJ Open* 2023;13:e075245.
- [26] Pozzoni M, Sammaria C, Villanacci R, Borgese C, Ghisleri F, Farina A, et al. Prenatal diagnosis and postnatal outcome of Type-III vasa previa: systematic review of literature. *Ultrasound Obstet Gynecol* 2024;63:24–33.
- [27] Ruiter L, Kok N, Limpens J, Derks JB, de Graaf IM, Mol B, et al. Incidence of and risk indicators for vasa praevia: a systematic review. *BJOG* 2016;123:1278–87.
- [28] Jauniaux E, Moffett A, Burton GJ. Placental implantation disorders. *Obstet Gynecol Clin North Am* 2020;47:117–32.
- [29] Jauniaux E, Melcer Y, Maymon R. Prenatal diagnosis and management of vasa previa in twin pregnancies: a case series and systematic review. *Am J Obstet Gynecol* 2017;216:568–75.
- [30] Ebbing C, Johnsen SL, Albrechtsen S, Sunde ID, Vekseth C, Rasmussen S. Velamentous or marginal cord insertion and the risk of spontaneous preterm birth, prelabor rupture of the membranes, and anomalous cord length, a population-based study. *Acta Obstet Gynecol Scand* 2017;96:78–85.
- [31] Siargkas A, Tsakiridis I, Pachi C, Mamopoulos A, Athanasiadis A, Dagklis T. Impact of velamentous cord insertion on perinatal outcomes: a systematic review and meta-analysis. *Am J Obstet Gynecol MFM* 2023;5:100812.
- [32] Ebbing C, Kiserud T, Johnsen SL, Albrechtsen S, Rasmussen S. Third stage of labor risks in velamentous and marginal cord insertion: a population-based study. *Acta Obstet Gynecol Scand* 2015;94:878–83.
- [33] Costa-Castro T, Zhao DP, Lipa M, Haak MC, Oepkes D, Severo M, et al. Velamentous cord insertion in dichorionic and monochorionic twin pregnancies - Does it make a difference? *Placenta* 2016;42:87–92.
- [34] Evans GM. Vasa praevia. *Br Med J* 1952;2(4796):1243.
- [35] Oyelese Y, Catanzarite V, Prefumo F, Lashley S, Schachter M, Tovbin Y, et al. Vasa previa: the impact of prenatal diagnosis on outcomes. *Obstet Gynecol* 2004;103:937–42.
- [36] Zhang W, Geris S, Al-Emara N, Ramadan G, Sotiriadis A, Akolekar R. Perinatal outcome of pregnancies with prenatal diagnosis of vasa previa: systematic review and meta-analysis. *Ultrasound Obstet Gynecol* 2021;57:710–9.
- [37] Sepulveda W, Rojas I, Robert JA, Schnapp C, Alcalde JL. Prenatal detection of velamentous insertion of the umbilical cord: a prospective color Doppler ultrasound study. *Ultrasound Obstet Gynecol* 2003;21:564–9.
- [38] Ruiter L, Kok N, Limpens J, Derks JB, de Graaf IM, Mol BW, et al. Systematic review of accuracy of ultrasound in the diagnosis of vasa previa. *Ultrasound Obstet Gynecol* 2015;45:516–22.
- [39] Melcer Y, Jauniaux E, Maymon S, Tsviban A, Pekar-Zlotin M, Betsler M, et al. Impact of targeted scanning protocols on perinatal outcomes in pregnancies at risk of placenta accreta spectrum or vasa previa. *Am J Obstet Gynecol* 2018;218:443.e1–8.
- [40] Ross JA, Jurkovic D, Zosmer N, Jauniaux E, Hackett E, Nicolaides KH. Umbilical cord cysts in early pregnancy. *Obstet Gynecol* 1997;89:442–5.
- [41] Zangen R, Boldes R, Yaffe H, Schwed P, Weiner Z. Umbilical cord cysts in the second and third trimesters: significance and prenatal approach. *Ultrasound Obstet Gynecol* 2010;36:296–301.
- [42] Tonni G, Lituania M, Cecchi A, Carboni E, Resta S, Bonasoni MP, et al. Umbilical cord diseases affecting obstetric and perinatal outcomes. *Healthcare (Basel)* 2023;11:2634.