

## CASE REPORT

# Frontal sinus mucocele with orbital extension drained via a combined upper lid skin crease and endoscopic approach

Kirsty Michelle Clarke<sup>1</sup>  | Caroline Wilde<sup>1</sup> | Abi Walker<sup>2</sup> | Sarah Little<sup>2</sup> | Sarah F. Osborne<sup>2</sup>

<sup>1</sup>Adnexal Department, Moorfields Eye Hospital, London, UK

<sup>2</sup>Department of Otorhinolaryngology, St George's Hospital, London, UK

## Correspondence

Kirsty Michelle Clarke, Adnexal Department, Moorfields Eye Hospital, London, UK.  
St George's Hospital, Blackshaw Road, London. SW17 0QT, UK.  
Email: [kirsty.michelle.clarke@gmail.com](mailto:kirsty.michelle.clarke@gmail.com)

## Funding information

Moorfields Eye Hospital NHS Foundation Trust

## Abstract

This case report discusses the ophthalmic complications of frontal sinus mucoceles and describes the favorable long-term surgical outcomes of a combined endoscopic and upper-lid skin crease drainage approach carried out jointly with otorhinolaryngology. A 47-year-old single mother presented to eye casualty with markedly swollen eyelids and visual acuity of 6/6 in the left eye, no perception of light in the right. Ophthalmic examination revealed right-sided hypoglobus and proptosis with exposure keratopathy inferiorly. There was complete ophthalmoplegia in the right eye and a hemorrhagic optic disc visible on fundoscopy. CT orbit with contrast confirmed a diagnosis of giant frontal mucocele with orbital extension. The patient underwent mucocele drainage via a modified anterior orbitotomy approach and FESS (Functional Endoscopic Sinus Surgery) drainage performed jointly with otorhinolaryngology. Two weeks post-operatively her proptosis was resolving and by three months she had regained full extraocular motility. As expected, vision was not restored in the right eye. At one year, the patient's upper lid skin crease scar was completely buried in the eyelid's natural contour, and repeat CT scanning confirmed no re-stenosis or mucocele recurrence. This case demonstrates, that a multidisciplinary approach to far-lateral frontal sinus mucoceles with orbital extension and ophthalmic complications which combines an upper lid skin crease incision with FESS drainage, allows adequate access to the frontal sinus while preserving cosmesis.

## KEYWORDS

anterior orbitotomy, FESS, frontal mucocele, orbital cellulitis

## 1 | INTRODUCTION

Frontal sinus mucoceles occur in the context of frontal recess obstruction.<sup>1</sup> They develop insidiously, and patients

tend to present late, once sight-threatening complications have already developed.<sup>2</sup> Surgical treatment which combines marsupialization with the restoration of a functional frontal drainage pathway is the only curative treatment.

This is an open access article under the terms of the [Creative Commons Attribution-NonCommercial-NoDerivs](https://creativecommons.org/licenses/by-nc-nd/4.0/) License, which permits use and distribution in any medium, provided the original work is properly cited, the use is non-commercial and no modifications or adaptations are made.

© 2022 The Authors. *Clinical Case Reports* published by John Wiley & Sons Ltd.

However, frontal sinus mucoceles present a distinct challenge to surgeons in gaining adequate intra-operative visibility while preserving cosmesis.<sup>1</sup>

In recent years, open approaches to frontal sinus drainage using a bicoronal or Lynch–Howarth incision have fallen out of favor, due to extensive scarring and long post-operative recovery periods.<sup>1</sup> Minimally invasive endoscopic techniques provide a viable alternative to these problems for sphenoid and maxillary sinus mucoceles. However, experience has demonstrated that 18.5% of frontal mucoceles are inaccessible endoscopically, due to thick secretions, septae, or variations in anatomy.<sup>3</sup>

Access via the upper-lid skin crease is appealing to both the patient and surgeon alike, as it provides good operative visibility but leaves only a subtle scar concealed within the eyelid's natural contour. Here, we present a detailed description of the combined open and endoscopic procedure.

## 2 | CASE REPORT

A 47-year-old single mother was referred to eye casualty via the NHS 111 service after reporting a low-grade headache for 5 days, bilateral eyelid swelling, and blurred vision. On arrival, she presented with markedly swollen eyelids and vision loss in her right eye. There was no history of trauma or thyroid dysfunction. Her visual acuity was 6/6 in the left eye and no perception of light in the right eye, where a relative afferent pupillary defect was present. Intraocular pressures were 30 mmHg and 17 mmHg, respectively. On ophthalmic examination, there was hypoglobus and the right eye was proptosed by >5 mm when measured by a Hertel exophthalmometer. There was exposure keratopathy of the right eye covering an area of 1.5–4 mm. There was complete ophthalmoplegia in the right eye. Optical coherence tomography (OCT) imaging showed swollen hemorrhagic optic discs and a pale retina suggestive of a compression ischemic optic neuropathy (shown in [Figure 1A](#)). CT orbit with contrast confirmed the presence of a frontal sinus mucocele with intraorbital extension. A breach at the level of lamina papiracea leads to the communication of the ethmoidal-frontal compartment with the orbit (please see [Figure 2A](#)). Please see supplementary materials for further imaging ([Video S1](#)).

The patient was started on IV ceftriaxone and oral metronidazole. The day after presentation the patient was consented for mucocele drainage via a combined anterior orbitotomy and FESS drainage approach under general anesthesia. Before the surgery, she was prepped and draped, and the upper lid was marked to ensure optimal cosmesis. Next, the oculoplastic surgeon performed a modified anterior approach orbitotomy; a skin crease incision is made,

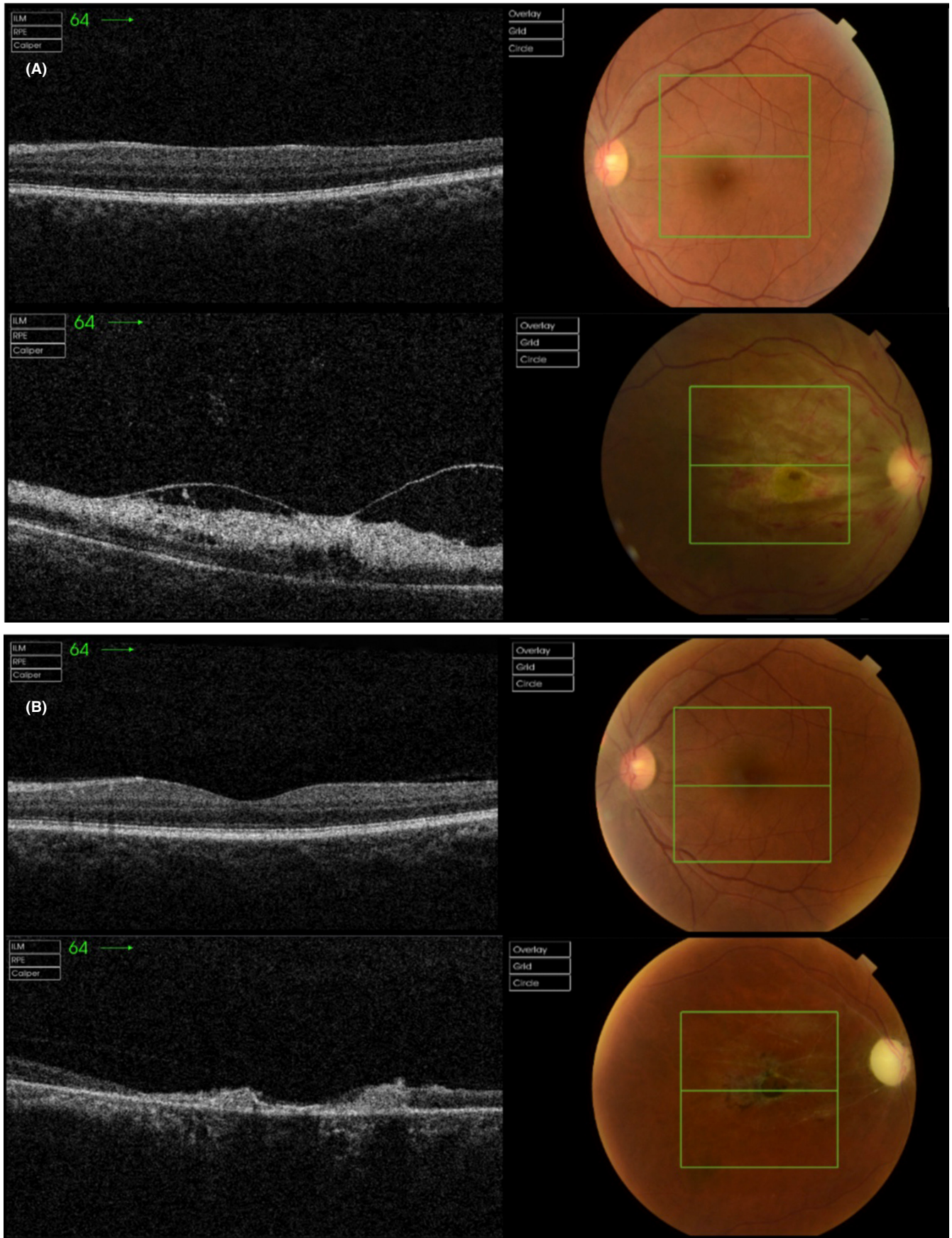
the orbicularis is divided, and dissection was performed above the orbital septum to the orbital rim using blunt scissors. The periosteum was incised at the orbital rim to allow subperiosteal dissection until the site of the bony defect was reached. The mucocele was drained via the skin crease incision. A functional endoscopic sinus surgery (FESS), and Entellus balloon system was used to allow passage to the frontal sinuses. An endoscope was passed through the lid crease to view the frontal sinus and the opening to the frontal recess to ensure complete drainage. It was also possible to place a balloon retrograde through the sinus as it could not be passed from the nose due to septae and thick secretions. Care was taken not to damage the supraorbital nerve. The lid skin was closed with 7–0 vicryl, completing the surgery in 2 hours and 28 minutes.

Postoperatively, the patient was discharged on the day of her procedure and her follow-up care included 14 days of co-amoxiclav tablets, intranasal steroids, and regular sinus douching. She was followed-up at 2 weeks for suture removal and then every 3–6 months at regular intervals to ensure no re-stenosis or mucocoele recurrence. Due to ocular motility restrictions, the patient was followed up in combined appointments with orthoptists.

At her 2 week adnexal clinic appointment for suture removal, the right eye proptosis was much improved, enabling full eye closure. She had regained full sensation to her right forehead but was experiencing occasional shooting pains over the vertex, likely due to irritation of the supraorbital nerve. Her vision remained no perception of light in the right eye, and due to exposure, she had developed two inferior corneal defects measuring 2 mm and 0.5 mm. Ocular movements were improved with restriction of –3 in all directions of gaze in the right eye. OCT image revealed a thin atrophic retina in the right eye with a pale optic disc, the left retina remained unchanged from the time of presentation (shown in [Figure 1B](#)). At 3 months follow-up, she was completely pain-free and her cornea was fully healed. Notably, her extraocular motility was fully restored, and the upper lid skin crease scar was buried completely in the eyelid contour. One year on, regular CT surveillance under otolaryngology has detected no re-stenosis or mucocele recurrence (shown in [Figure 2B](#)).

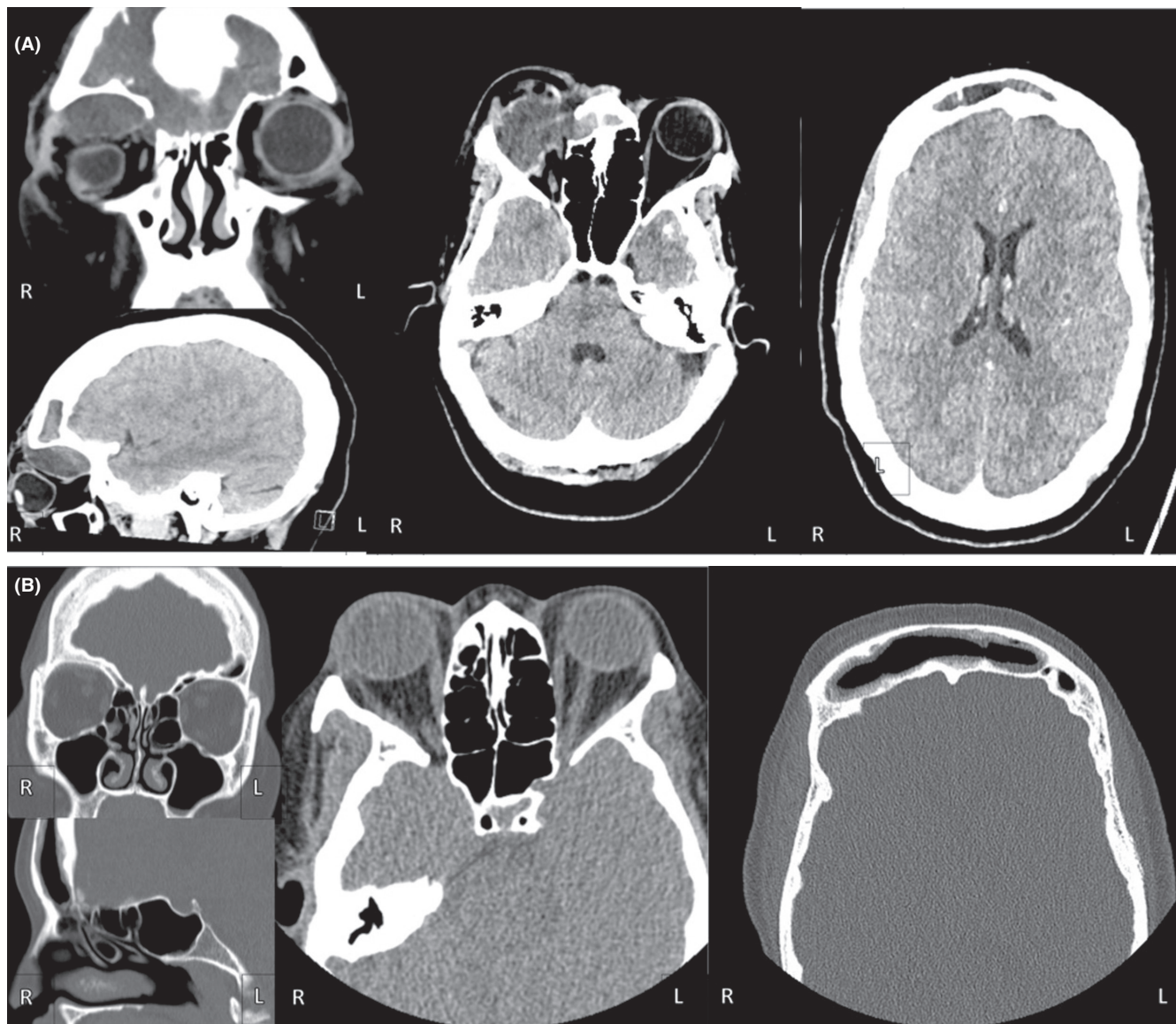
## 3 | DISCUSSION

Frontal sinus mucoceles present insidiously, and many patients have long histories of subtle symptoms.<sup>4</sup> Early signs of frontal sinus mucoceles encountered in this case included dull head pain and blurred vision. Such non-specific symptoms are difficult to identify and mucoceles are commonly misdiagnosed as rhinosinusitis in the first instance.<sup>4</sup> Unfortunately, frontal sinus disease can be



**FIGURE 1** (A) OCT of the right and left eye at presentation. Note the presence of a hemorrhagic swollen optic disc on the right. (B) OCT of the right and left eye at follow-up. The left eye appearance is stable in comparison to images taken at presentation. In the right eye, however, the optic disc is pale and atrophic. The retinal nerve fiber layer is visibly thinned.





**FIGURE 2** CT Imaging. (A) Unenhanced CT Orbit with contrast prior to surgery. Sagittal, coronal, and axial views show an expanded and markedly enlarged frontal sinus with mucosal thickening (arrow) and swelling of the soft tissues overlying the orbit and forehead. There is a destruction of the right lamina papyracea anteriorly. The frontal sinus and anterior ethmoid air cells were completely opacified and a low-density collection is seen eroding through the lamina papyracea into the superior aspect of the orbit causing superio-posterior globe indentation and proptosis. There is an extraconal low-attenuation collection displacing the extraocular muscles and retrobulbar fat. There is no intracranial extension of the mucocele. (B) CT unenhanced orbit at 3 months follow-up. The mucocele has been drained and there is no sign of re-stenosis. Proptosis has largely resolved. Minimal thickening of soft tissues anteriorly over the surgical defect.

highly morbid if left untreated, posing a risk of intraorbital infection and associated intracranial complications, such as meningitis, subdural abscess, intracerebral abscess, and osteomyelitis.<sup>1</sup> In this case, the patient presented late with irreversible vision loss due to compressive ischemic optic neuropathy, demonstrating the need for diagnosis and early operative intervention where frontal sinus disease is suspected.

Mucoceles that extend laterally beyond the mid pupillary line are extremely challenging to drain endoscopically,

with revision rates as high as 23%.<sup>5</sup> Iatrogenic injury to the frontal sinus may result in restenosis through soft tissue scarring and osteoneogenesis, further worsening the frontal recess obstruction.<sup>5</sup> Traditional open techniques leave prominent facial disfigurement and have also been associated with a significant risk of failure (33%), restenosis, and recurrent infection.<sup>1</sup> The risks of facial scarring and extended recovery periods may be especially unacceptable to newly diagnosed patients with only subtle symptoms at presentation.

No enduring surgical complications were reported in this case, and while the patient experienced supraorbital nerve pain initially, this resolved spontaneously on follow-up. Unfortunately, the duration of follow-up, in this case, cannot exclude recurrence several years after treatment; however, the resolution of ocular motility in a case of severe sinus disease shows the technique to be a promising advancement in the treatment of what has to date been a surgically challenging condition.

## 4 | CONCLUSION

This case demonstrated how advanced frontal sinus mucoceles with severe ophthalmic complications can be effectively treated by combining the expertise of otolaryngologists, with that of oculoplastic surgeons, to gain optimal access while utilizing minimally invasive endoscopic techniques to preserve cosmesis.

### AUTHOR CONTRIBUTIONS

KC lead data collection and drafted all case report. CW aided data collection and made substantive edits to all drafts of the manuscript. SO, SL, and AW made substantive edits to the final draft of the manuscript.

### ACKNOWLEDGMENTS

We would like to thank the patient in this report for kindly allowing her clinical case to be shared in order that we might improve the management of frontal sinus disease.

### CONFLICT OF INTEREST

The authors have no conflicts of interest to declare.

### DATA AVAILABILITY STATEMENT

Not applicable.

### CONSENT

Written informed consent was obtained from the patient to publish this report in accordance with the journal's patient consent policy.

### ORCID

Kirsty Michelle Clarke  <https://orcid.org/0000-0002-0229-0158>

### REFERENCES

1. Ramadan H. History of frontal sinus surgery. *The Frontal Sinus*. Springer; 2005:1-6.
2. Herndon M, McMains KC, Kountakis SE. Presentation and management of extensive fronto-orbital-ethmoid mucoceles. *Am J Otolaryngol*. 2007;28:145-147.
3. Plantier DB, Brandão D, Pinna FDR, Voegels RL. Mucocele: clinical characteristics and outcomes in 46 operated patients. *Int Arch Otorhinolaryngol*. 2019;23:88-91.
4. Scangas GA, Gudis DA, Kennedy DW. The natural history and clinical characteristics of paranasal sinus mucoceles: a clinical review. *Int Forum Allergy Rhinol*. 2013;3:712-717.
5. Dhepnorarat RC, Subramaniam S, Sethi DS. Endoscopic surgery for fronto-ethmoidal mucoceles: a 15-year experience. *Otolaryngol Head Neck Surg*. 2012;147:345-350.

### SUPPORTING INFORMATION

Additional supporting information can be found online in the Supporting Information section at the end of this article.

**How to cite this article:** Clarke KM, Wilde C, Walker A, Little S, Osborne SF. Frontal sinus mucocele with orbital extension drained via a combined upper lid skin crease and endoscopic approach. *Clin Case Rep*. 2022;10:e06206. doi: [10.1002/ccr3.6206](https://doi.org/10.1002/ccr3.6206)