

Mending the broken valentine heart: a case report

Sarandeep Marwaha *, Raghav Bhatia, Michael Papadakis, and Anna Marciniak

Department of Cardiology, St George's, University of London, St George's University Hospitals NHS Foundation Trust, London SW17 0RE, UK

Received 1 February 2022; first decision 8 April 2022; accepted 29 July 2022; online publish-ahead-of-print 5 August 2022

Background

Mortality from myocardial infarction (MI) has been decreasing since the introduction of primary percutaneous intervention. Late complications still pose a dilemma, such as deterioration of left ventricle (LV) function, LV aneurysms, and LV thrombus formation. If not adequately managed in a timely manner, this can result in life-threatening consequences. Restoration of LV function by surgical resection of the infarcted LV wall is an option for a few complicated cases, with variable outcomes.

Case summary

A 66-year-old man presented with dyspnoea 2 years after his initial MI, which was treated with a drug-eluting stent to his left circumflex artery. His Warfarin had been stopped after 6 months of treatment of a small LV thrombus, which was noted at the time of his initial infarction. His echocardiogram on admission demonstrated severe LV systolic impairment of 23% (which had deteriorated from 40%) with a giant true aneurysm of the basal to mid-lateral wall, which resembled a Valentine heart. The presence of a large, organized thrombus filling the aneurysm complicated the case further. The patient underwent a resection of the LV aneurysm and thrombus. He remained asymptomatic and maintained a significant improvement of his LV function to 47% at his 5 months scan.

Discussion

The importance of imaging post-large MI and follow-up imaging once thrombus resolution has occurred is crucial. Patients with large LV aneurysm associated with severe refractory LV impairment and LV thrombus should be considered for LV aneurysmectomy for prognostic benefit and symptom relief.

Keywords

Aneurysm • Case report • Cardiac magnetic resonance • Left ventricular aneurysmectomy • Myocardial infarction • Thrombus

ESC Curriculum

2.1 Imaging modalities • 2.3 Cardiac magnetic resonance • 3.3 Chronic coronary syndrome • 6.2 Heart failure with reduced ejection fraction • 7.5 Cardiac surgery

Learning points

- Left ventricle (LV) thrombus may reoccur or become chronic if there is a large akinetic segment of the myocardium.
- Left ventricle aneurysmectomy should be discussed as an option in severely impaired LV function with LV thrombus or symptomatic patients.
- Cardiovascular magnetic resonance scans should be considered in large myocardial infarction to confirm resolution of subtle thrombus in severely dilated and impaired LV and for assessment of akinetic walls when LV aneurysmectomy is being considered.

* Corresponding author. Email: anna.marciniak2@stgeorges.nhs.uk

Handling Editor: Tina Khan

Peer-reviewers: Matthew Williams; Mark Abela

Compliance Editor: Lavanya Athithan

Supplementary Material Editor: Ameenathul Mazaya Fawzy

© The Author(s) 2022. Published by Oxford University Press on behalf of European Society of Cardiology.

This is an Open Access article distributed under the terms of the Creative Commons Attribution-NonCommercial License (<https://creativecommons.org/licenses/by-nc/4.0/>), which permits non-commercial re-use, distribution, and reproduction in any medium, provided the original work is properly cited. For commercial re-use, please contact journals.permissions@oup.com

Introduction

Since the introduction of primary percutaneous coronary intervention, mortality from acute myocardial infarction (MI) has decreased.¹ Despite this, left ventricular (LV) failure and LV thrombus is a known complication and a cause of increased mortality after the acute period. Left ventricle thrombus is associated with cerebrovascular accident and systemic thromboembolisms.² Previous studies have suggested the incidence of LV thrombus in anterior MI being up to 56%. Although most recent studies suggest a lower incidence of up to 8%.³ This may be attributable to early reperfusion and the introduction of effective heart failure medication such as angiotension-converting enzyme inhibitors.⁴ An anterior ST elevation MI (STEMI), significant LV dysfunction, and microvascular obstruction are major risk factors for LV thrombus formation.³ The detection of LV thrombus has been reported to be higher with cardiovascular magnetic resonance (CMR) compared with echocardiogram,³ which often patients do not routinely have post-discharge. Missing a late formation LV thrombus could have life-threatening consequences to the patient and the association with LV aneurysms poses a debate of whether medical or surgical approach should be considered.

Timeline

Day	Events/tests
2 years earlier	MI requiring stent to co-dominant LCx
Day 1	Presented with SOB during outpatient echocardiogram
Day 3	Patient underwent a CMR: revealed severely impaired LV shaped like a 'Valentine' heart
Day 4	Patient underwent a coronary angiogram: showed moderate to severe lesions but no acute occlusion of a coronary artery
Day 5	Multidisciplinary meeting consensus for patient to undergo LV aneurysmectomy
Day 7	Patient underwent LV aneurysmectomy and thrombus removal
Day 8	Post-operation echocardiogram confirming, no pericardial effusion, improvement of LV function to 42% and no obvious thrombus detected
Day 14	Patient discharged from hospital with uneventful post-operation recovery
4 months post-operation	Patient underwent an CMR confirming improvement of ejection fraction (EF) had remained and there was no further residual LV thrombus formation

Case presentation

A 66-year-old male with a past medical history of Type 2 diabetes and hypertension was transferred to the Cardiothoracic Unit with worsening breathlessness. The patient had previously presented 2 years ago with chest pain and was diagnosed with a large MI due to a co-dominant left circumflex artery (LCx) occlusion, which was treated with a

drug-eluting stent. He was noted at the time to have severe LV impairment and a small laminar thrombus on echocardiogram and a dual pathology for his severe LV impairment was considered at the time with a plan for an outpatient CMR, which did not occur. He was medically optimized, for heart failure, anticoagulated, and his EF had increased to 40%. According to the patient, he had been advised to stop his anticoagulation after 6 months and there had been no further plans of re-imaging him. Unfortunately, the patient was lost to follow-up. He had remained compliant on his heart failure medications. Due to multiple unattended appointments, this was his first presentation since his MI.

On clinical examination, he was haemodynamically stable, and his chest was clear, with no peripheral oedema. His admission ECG showed sinus bradycardia, rate of 53 b.p.m. with Q waves in Leads II, V5, and V6. His echocardiogram had shown a deterioration in LV systolic function with EF of 20% despite heart failure medication and a large aneurysmal lateral wall with a large laminar thrombus. The patient was immediately started on anticoagulation with Warfarin.

He underwent an angiogram, which showed an unobstructed left anterior descending artery, moderate to severe LCx ostial disease with mild in-stent restenosis, and mild to moderate stenosis of the small right coronary artery. For further assessment of myocardial viability and thrombus size, the patient underwent a cardiac MRI (CMR). This showed a severely dilated LV with severely impaired LV systolic function (EF 23%), a giant LV aneurysm out pouching from the basal to mid-inferolateral and inferior walls (101 mm width, 64 mm depth with a broad neck of 73 mm), resembling a Valentine heart (Figure 1). There was full thickness infarction of all aneurysmal segments and a large organized, thrombus filling the aneurysm, measuring 90 × 29 mm. The right ventricle was of a normal size and systolic function (EF: 59%).

The patient was discussed in the multidisciplinary team (MDT) meeting, and it was deemed that he would benefit from a LV aneurysmectomy and thrombectomy for better prognosis and symptom relief. The patient had a successful operation, and he was discharged with no complication. His follow-up echocardiogram showed a normal LV cavity size with improvement of his LV systolic function (EF of 42%) with akinetic inferolateral and anterolateral walls. He has remained on Warfarin and heart failure medications. A follow-up CMR nearing Valentine's Day confirmed a significant improvement in his LV function, which had maintained at an EF of 47%, with no evidence of further thrombus. The patient remained in NYHA Class I (Figure 1).

Discussion

The highest risk of LV thrombosis formation is within the first 3 months of a MI. Up to 85–90% of thrombi will be detected in the first 7–14 days but 15% can be detected at the 8–9-week scan interval.^{3,4} Often an echocardiogram scan may not show a clear thrombus or be as sensitive as a CMR scan in its detection. Therefore, CMR should potentially be considered for LV thrombus assessment in high-risk patients but repeating at least the echocardiogram scan during follow-up would be beneficial before considering stopping anticoagulation. The 2017 ESC STEMI guidelines suggest 6 months of anticoagulation for mural thrombus with a repeat echocardiogram to decide on further long-term therapy.⁵

A true LV aneurysm is defined as an area of akinesia, which involves a full wall and protrudes, resulting in a reduced EF.⁶ Left ventricle aneurysm and severely impaired apical segments are associated with higher risk of thrombus formation.² The main aim of a LV aneurysmectomy is to re-establish LV structure by removal of akinetic fibrous segments with the intention of decreasing end-diastolic volume and hence increasing stroke volume, ultimately improving mortality and morbidity outcome.^{7,8} There is little data on the beneficial impact of LV aneurysmectomy and previous studies such as the STITCH trial did not show

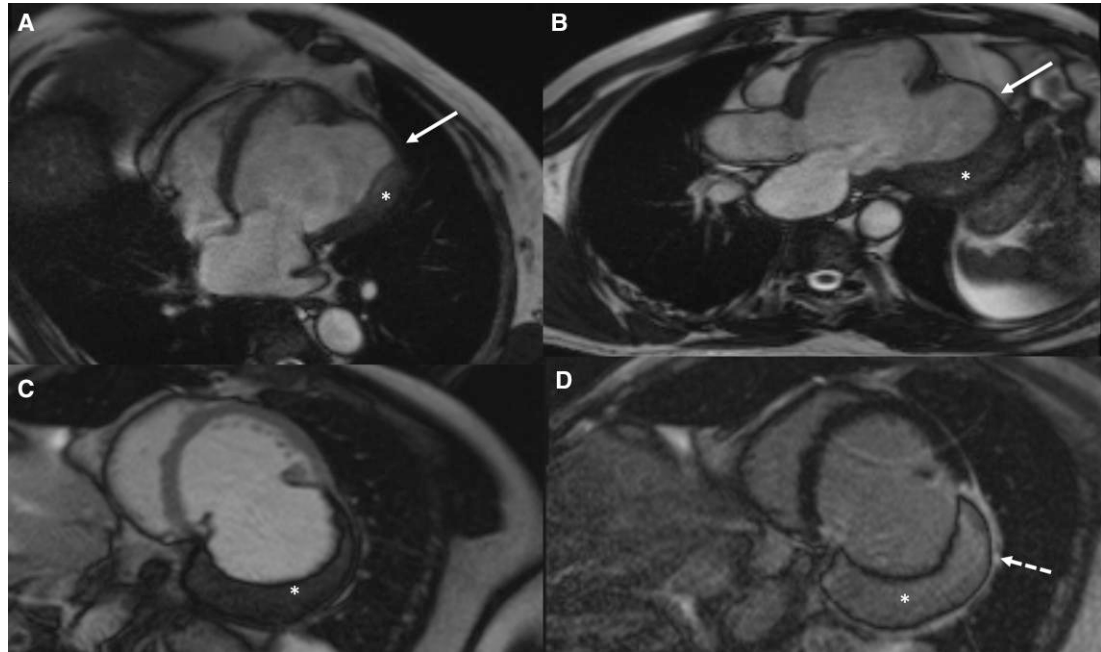


Figure 1 Cardiovascular magnetic resonance images taken before left ventricle aneurysmectomy. (A and B) Four-chamber and three-chamber long axis demonstrating a giant true aneurysm (white arrow) from the inferolateral wall and inferior wall. Large aneurysm filled with a large thrombus (white star); (C) short axis view of early gadolinium images highlighting thrombus (white star); (D) short axis view of late gadolinium images highlighting infarcted area (white dashed arrow) and thrombus (white star).

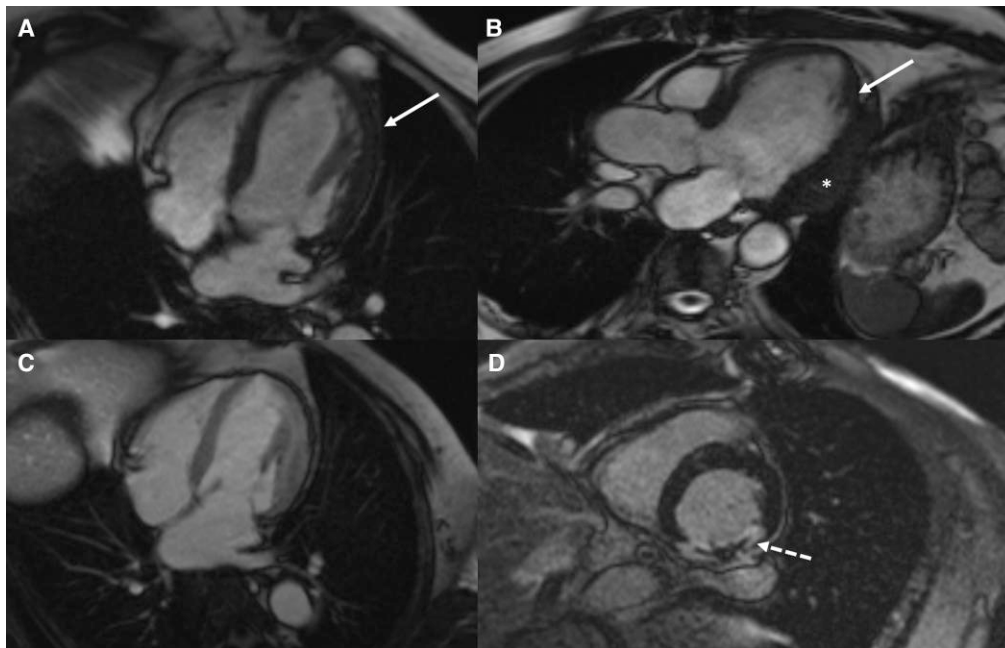



Figure 2 Cardiovascular magnetic resonance images taken after the left ventricle aneurysmectomy. (A and B) Four-chamber and three-chamber long axis demonstrating resection of the aneurysmal wall (white arrow) with presence of probable organized haematoma (white star); (C) long axis four-chamber view of early gadolinium images highlighting no evidence of a thrombus; (D) short axis view of late gadolinium images highlighting the reconstructed new inferolateral wall and infarcted area (white dashed arrow).

an overall mortality benefit,⁹ therefore, ESC does not routinely recommend this procedure but mentions this procedure should be considered in patients with large aneurysms with arrhythmias or uncontrolled heart failure,⁵ often this will be done at the time of a coronary artery bypass graft procedure (CABG).¹⁰ In the 2018 ESC/EACTS guidelines for a LV aneurysmectomy during CABG is deemed to be a Class IIa indication and should be considered with patients who have evidence of a large aneurysm, large thrombus formation, LV arrhythmias, or symptomatic patients class NYHA III/IV.¹⁰ There is no specific definition of what is deemed to be a large thrombus or the size an aneurysm should be to benefit from this procedure, further studies would need to be conducted to clarify this. A 2010 study showed short- and long-term survival benefit and NYHA classification improvement with an almost 90% survival in patients with initially severe LV impairment at 3 years compared with previous documented 5 year survival of up to 73% in revascularized patients only.¹¹ In this particular case the patient, had been discussed in a MDT and it was felt given the large aneurysm with a large thrombus and the patients continuous refractory symptoms of heart failure indicated he would benefit from LV aneurysmectomy. Ultimately this form of management should be considered and discussed in an MDT when faced with patients that exhibit a large aneurysm associated with a large LV thrombus despite optimal medical care. Ultimately if left untreated can place the patient at risk of systemic embolism, ventricular rupture, increased ventricular arrhythmias, and potential death.

Lead author biography



Dr Marwaha completed her medical training at St Georges University of London and has a BSc Degree in Cardiovascular Sciences from Imperial College London. She holds a national training number in cardiology and holds accreditations in multiple cardiac imaging modalities. She has experience in general cardiology, inherited cardiac conditions and sports cardiology. She is currently a Cardiac Risk of the Young research Fellow at St Georges, University of London and conducts re-

search and doing her PhD in cardiomyopathy and athletes' heart. She has experience in teaching junior registrars, medical students, and international students and is currently the module lead on the MSc Sports Cardiology programme at St Georges University of London.

Supplementary material

Supplementary material is available at *European Heart Journal – Case Reports* online.

Slide sets: A fully edited slide set detailing this case and suitable for local presentation is available online as Supplementary data.

Consent: The authors confirm that written consent for submission and publication of this case report including images and associated text has been obtained from the patient's next-of-kin in line with COPE guidance.

Conflict of interest: None declared.

Funding: None declared.

References

- Weaver WD, Simes RJ, Betriu A, Grines CL, Zijlstra F, Garcia E, Grinfeld L, Gibbons RJ, Ribeiro EE, DeWood MA, Ribichini F. Comparison of primary coronary angioplasty and intravenous thrombolytic therapy for acute myocardial infarction: a quantitative review. *JAMA* 1997;**278**:2093–2098.
- Asinger RW, Mikell FL, Elsperger J, Hodges M. Incidence of left-ventricular thrombosis after acute transmural myocardial infarction. Serial evaluation by two-dimensional echocardiography. *N Engl J Med* 1981;**305**:297–302.
- Phan J, Nguyen T, French J, Moses D, Schlaphoff G, Lo S, Juergens C, Dimitri H, Richards D, Thomas L. Incidence and predictors of left ventricular thrombus formation following acute ST-segment elevation myocardial infarction: a serial cardiac MRI study. *Int J Cardiol Heart Vasc* 2019;**24**:100395.
- Delewi R, Zijlstra F, Piek JJ. Left ventricular thrombus formation after acute myocardial infarction. *Heart* 2012 Dec;**98**:1743–1749.
- Ibáñez B, James S, Agewall S, Antunes MJ, Bucciarelli-Ducci C, Bueno H, Caforio ALP, Crea F, Goudevenos JA, Halvorsen S, Hindricks G, Kastrati A, Lenzen MJ, Prescott E, Roffi M, Valgimigli M, Varenhorst C, Vranckx P, Widimský P. 2017 ESC Guidelines for the management of acute myocardial infarction in patients presenting with ST-segment elevation. *Rev Esp Cardiol* 2017;**70**:1082.
- Ruzza A, Czer LSC, Arabia F, Vespignani R, Esmailian F, Cheng W, De Robertis MA, Trento A. Left ventricular reconstruction for postinfarction left ventricular aneurysm: review of surgical techniques. *Tex Heart Inst J* 2017;**44**:326–335.
- Cohen M, Packer M, Gorlin R. Indications for left ventricular aneurysmectomy. *Circulation* 1983 Apr;**67**:717–722.
- Hui DS, Restrepo CS, Calhoon JH. Surgical decision making for left ventricular aneurysmectomy. *Ann Thorac Surg* 2020;**110**:e559–e561.
- Jones RH, Velazquez EJ, Michler RE, Sopko G, Oh JK, O'Connor CM, Hill JA, Menicanti L, Sadowski Z, Desvigne-Nickens P, Rouleau J-L, Lee KL. Coronary bypass surgery with or without surgical ventricular reconstruction. *N Engl J Med* 2009;**360**:1705–1717.
- Neumann FJ, Sousa-Uva M, Ahlsson A, Alfonso F, Banning AP, Benedetto U, Byrne RA, Collet JP, Falk V, Head SJ, Jüni P, Kastrati A, Koller A, Kristensen SD, Niebauer J, Richter DJ, Seferovic PM, Sibbing D, Stefanini GG, Windecker S, Yadav R, Zembala MO, ESC Scientific Document Group. 2018 ESC/EACTS Guidelines on myocardial revascularization. *Eur Heart J* 2019;**40**:87–165.
- Serrano CV, Ramires JAF, de Matos Soeiro A, César LAM, Hueb WA, Dallan LA, Jatene FB, Stolf NAG. Efficacy of aneurysmectomy in patients with severe left ventricular dysfunction: favorable short- and long-term results in ischemic cardiomyopathy. *Clinics* 2010;**65**:947–952.