



Case series

Clinical management and outcomes of primary ovarian leiomyosarcoma – Experience from a sarcoma specialist unit

Elena Cojocaru^{a,1}, Githmi Palahepitiva Gamage^{b,1}, John Butler^c, Desmond P. Barton^d,
Khin Thway^a, Cyril Fisher^e, Christina Messiou^{f,g}, Aisha B. Miah^a, Shane Zaidi^a,
Spyridon Gennatas^a, Charlotte Benson^a, Paul Huang^f, Robin L. Jones^{a,f,*}

^a Sarcoma Unit, The Royal Marsden Hospital, 203 Fulham Rd, London SW3 6JJ, UK

^b Royal College of Surgeons in Ireland, Ireland

^c Gynaecological Unit, The Royal Marsden Hospital, 203 Fulham Rd, London SW3 6JJ, UK

^d St George's Hospital, Blackshaw Road, London, Greater London SW17 0QT, UK

^e Department of Musculoskeletal Pathology, University Hospitals Birmingham, Birmingham B15 2GW, UK

^f The Institute of Cancer Research, Chester Beatty Laboratories, 237 Fulham Road, London SW3 6JB, UK

^g Radiology Department, The Royal Marsden Hospital, 203 Fulham Rd, London SW3 6JJ, UK

ARTICLE INFO

Keywords:

Ovarian leiomyosarcoma

Ovary

Sarcoma

Prognosis

Treatment

Chemotherapy

ABSTRACT

Ovarian sarcomas account for 1% of all ovarian malignancies and amongst these, primary ovarian leiomyosarcoma is the rarest subtype. Primary ovarian leiomyosarcoma has a very poor prognosis, with less than 20% of patients being alive at 5 years. Only a few cases have been published in the literature and there is very limited knowledge on the clinical behaviour and optimal management of these tumours. We have performed a retrospective analysis of a prospectively maintained database to identify all primary ovarian leiomyosarcoma diagnosed and treated at the Royal Marsden NHS Foundation Trust between 1998 and 2020. Sixteen patients were identified from our database and fifteen were eligible for the analysis. Twelve patients presented with localized disease and underwent initial surgery and three patients had metastatic disease at presentation. Recurrence-free survival post-surgery was 16 months. Eight patients received first-line chemotherapy and four patients received second-line chemotherapy. Two patients had indolent metastatic disease and benefited from local therapies only. The median overall survival in the metastatic setting in our cohort was 51 months, which is consistent with previously published cases. Primary ovarian leiomyosarcoma is an extremely rare malignancy with a poor prognosis. This study is the largest case series of primary ovarian leiomyosarcoma published to date, providing clinically important information regarding survival and metastatic rate as well as treatment outcomes in the metastatic setting.

1. Background

Primary ovarian leiomyosarcoma is a very rare form of malignancy which mainly occurs in women aged 45–60 years (Nazneen, et al., 2016; Pankaj et al., 2013; Goodalla et al., 2011; Arslan, 2011; Meng, 2016; Monk et al., 1993). Ovarian smooth muscle tumors represent 1% of all ovarian malignancies and ovarian leiomyosarcoma accounts approximately for 0.1% of all ovarian malignancies (Goodalla et al., 2011; Taşkın, 2007). Other sarcoma subtypes originating in the ovary include rhabdomyosarcomas, fibrosarcomas and stromal cell sarcomas

(Goodalla et al., 2011). It is believed that these tumours arise from the malignant degeneration of smooth muscle present in the ovary, originating in the blood vessels, ovarian ligaments or the ovarian mesenchyme (Friedman and Mazur, 1991; Kurian et al., 2005).

The initial symptoms are vague and can include lower abdominal pain, altered bowel and bladder habit, vaginal bleeding. Some patients present with bilateral hydronephrosis and incontinence (Pankaj et al., 2013; Goodalla et al., 2011; Inoue et al., 2000). The tumour marker CA-125 is usually within normal values or mildly increased (Rasmussen, 1997; Tanaka et al., 2018; Kaur, 2014). The International Federation of

* Corresponding author at: Sarcoma Unit, 203 Fulham Rd, Chelsea, London SW3 6JJ, UK.

E-mail address: robin.jones@rmh.nhs.uk (R.L. Jones).

¹ Joint first authors.

<https://doi.org/10.1016/j.gore.2021.100737>

Received 19 December 2020; Received in revised form 7 February 2021; Accepted 15 February 2021

Available online 2 March 2021

2352-5789/© 2021 The Authors.

Published by Elsevier Inc.

This is an open access article under the CC BY-NC-ND license

(<http://creativecommons.org/licenses/by-nc-nd/4.0/>).

Gynecology and Obstetrics (FIGO) classification and TNM Classification staging system are utilized to determine the appropriate management (Arslan, 2011; Tanaka et al., 2018; Furutake et al., 2017). The stage and the size of the tumour and the mitotic index impact the prognosis (Pankaj et al., 2013; Bouie, 2005), however, as in other gynecological sarcomas, primary ovarian leiomyosarcoma are not routinely graded.

Histologically, primary ovarian leiomyosarcoma is diagnosed based on the presence of eosinophilic spindle-shaped cells with enlarged, variably pleomorphic nuclei, arranged in intersecting fascicles or sheets (Pankaj et al., 2013; Furutake et al., 2017; Kumar Vijaya et al., 2015; Bodner et al., 2003). The nuclei have blunted, or truncated ends and the cells have a dense cytoplasm. Other histological features are cellular atypia, presence of coagulative necrosis and increased, often atypical, mitoses (Friedman and Mazur, 1991). On immunohistochemistry, the

tumours are diffusely strongly positive for desmin, smooth muscle actin (SMA), h-caldesmon, and sometimes bcl-2 (Pankaj et al., 2013; Tanaka et al., 2018; Furutake et al., 2017; Bouie, 2005; Kumar Vijaya et al., 2015; Bodner et al., 2003; Lerwill et al., 2004). It also expresses estrogen and progesterone receptors (Bouie, 2005).

Due to their rarity, there is very limited knowledge on the clinical behaviour and optimal management of these tumours. This study aims to provide a benchmark to guide clinical practice and future research.

2. Ethics approval and consent to participate

Institutional approval for use of the data was sought through the service evaluation that was approved (SE 934, date 24/05/2020) by the Royal Marsden Institutional Review Board. Because this was a

Table 1

Patients characteristics at diagnosis and outcomes of first line metastatic systemic therapy in ovarian leiomyosarcoma.

Patient	FIGO stage at diagnosis	Treatment at diagnosis	Relapse-free survival (months) from surgery or adjuvant chemotherapy to disease recurrence or last follow-up	1st line metastatic chemotherapy	Best response	Progression-free survival of first line of systemic therapy (months)	Status at data-cut	Overall survival or time to last follow-up if alive (months)
1	IVB	TAH + BSO followed by palliative chemotherapy	N/A	ifosfamide-doxorubicin × 8 cycles	Partial response (60% reduction by RECIST 1.1)	12	Dead of disease	25
2	IA	TAH + BSO	No recurrence at 15 months	no systemic therapy received	N/A		Lost to follow-up	15
3	IA	TAH + BSO	14	doxorubicin x6 cycles (at the local hospital – no information on outcome)	Unknown		Dead of disease	51
4	IA	TAH + BSO	31	gemcitabine-docetaxel x6 cycles	Partial response (31% reduction by RECIST 1.1)	8	Dead of disease	77
5	IVB	Palliative chemotherapy	N/A	doxorubicin x6 cycles	Stable disease (19% reduction by RECIST 1.1)	11	Dead of disease	18
6	IA	RSO	16	no systemic therapy received	N/A		Alive with evidence of disease	98
7	IA	TAH + BSO	15	gemcitabine-docetaxel x6 cycles	Stable disease	7	Dead of disease	56
8	IA	TAH + BSO	3	carboplatin-gemcitabine x5 cycles	Stable disease	4	Dead of disease	22
9	IA	LSO	No recurrence at 8 months	no systemic therapy received	N/A	N/A	Alive with no evidence of disease	8
10	IIB	BSO followed by 5 cycles Gemcitabine-Docetaxel adjuvant chemotherapy	11	doxorubicin	N/A		Lost to follow-up	12
11	IVB	No treatment due to poor performance status at diagnosis	N/A	no systemic therapy received	N/A		Dead of disease	2
12	IA	BSO	40	no systemic therapy received	N/A		Alive with evidence of disease	47
13	IA	LSO	No recurrence at 15 months	no systemic therapy received	N/A		Alive with no evidence of disease	15
14	IIB	TAH + BSO	No recurrence at 13 months	no systemic therapy received	N/A		Alive with no evidence of disease	13
15	IIIA2	TAH + BSO followed by 1 cycle of adjuvant gemcitabine-docetaxel chemotherapy	7	epirubicin-carboplatin x4 cycles	stable disease		Alive with evidence of disease	11

TAH-BSO total abdominal hysterectomy and bilateral salpingo-oophorectomy; RSO right salpingo-oophorectomy; LSO left salpingo-oophorectomy.

retrospective study, written informed consent was not obtained from the subjects. At Royal Marsden Hospital, for retrospective clinical studies such as case reports and treatment effects, we confirm with patients the consent for comprehensive clinical studies. All participants in this study agree on its comprehensive research participation.

3. Patients and methods

We performed a retrospective search of the prospectively maintained Royal Marsden Hospital Sarcoma Database and identified all women diagnosed with primary ovarian leiomyosarcoma between January 1998 and March 2020. The diagnosis of primary ovarian leiomyosarcoma was confirmed by two experienced sarcoma specialist histopathologists (KT, CF). Following surgery for localised disease (FIGO stages I-III), surveillance with computed tomography (CT) scan of the chest, abdomen and pelvis, was performed every 3 months for the first 2 years, and then every 6 months up to 5 years and then annually for a total of 10 years. For patients treated with palliative chemotherapy, restaging was performed following every 2–3 cycles. Response evaluation criteria in solid tumors 1.1 (RECIST 1.1) was used to assess response to therapy. Descriptive statistical analysis was performed using Statistical Product and Service Solutions (SPSS) software. Survival was estimated using Kaplan Meier curves. Data-cut for the analysis was 04/05/2020.

Our institution is a tertiary sarcoma center, with expertise in diagnosis and treatment of leiomyosarcomas. Herein we present our approach to management of ovarian leiomyosarcomas at diagnosis and at relapse.

4. Results

Patient demographics and tumour characteristics (Table 1)

Sixteen women with a diagnosis of ovarian leiomyosarcoma were identified from our database, with one excluded as she was referred for a second opinion only. Of the 15 patients analyzed, the median age at diagnosis was 56 years (range 30–76). In the same period of time, 1958 patients with leiomyosarcoma were diagnosed and treated in our institution, meaning that ovarian leiomyosarcoma represented 0.8% of all leiomyosarcoma tumours in our hospital.

The ovarian masses were unilateral in 14 patients and bilateral in one patient (Patient 14). This patient had multifocal disease, with both ovaries involved and the uterus, but no other distant disease. Although there was relatively little atypia, there were enough features to warrant diagnosis of leiomyosarcoma in all 3 areas. It remains unclear as to whether the ovarian neoplasm represents metastases from the uterine neoplasm, or it represents synchronous malignant disease. Twelve patients (80%) had localized disease at diagnosis: FIGO stage IA in 9 patients, IIB in 2 patients and IIIA2 in one patient. Other three patients (20%) had metastatic disease at presentation, corresponding to stage IVB FIGO. Median tumour size at diagnosis, based on the largest diameter, was 20 cm (range 6 – 26 cm). Only 3 patients in our cohort had a CA125 test performed at baseline and all values were within normal limits.

4.1. Treatment of localized disease (FIGO stages I-IIIa)

Surgery of the primary tumour was performed in all 12 patients presenting with localized disease as shown in Table 1. Only two patients (patients 10 and 15) received adjuvant chemotherapy with gemcitabine-docetaxel. One woman was treated with 5 cycles of adjuvant gemcitabine-docetaxel. Another woman withdrew consent after one cycle of adjuvant chemotherapy. The median relapse-free survival post-surgery in this group of localized disease was 16 months (95% CI 13.4 – 18.5), with four patients remaining relapse-free at their last follow-up.

4.2. Treatment of relapsed or metastatic disease (FIGO stage IVB)

In our cohort of fifteen patients, three women had metastatic disease at initial diagnosis and eight other women developed metastatic relapse after initially being treated for localised cancer. The treatment of these eleven patients was determined by their disease burden. The most common sites of metastatic relapse were lungs, liver, bones and adrenal glands. One patient with advanced cancer at diagnosis did not receive any treatment due to poor performance status and died within 2 months of presentation (Patient 11).

For two patients, palliative surgery was offered for low volume metastatic disease (Patients 6 and 12). Neither of these two patients have received any form of systemic therapy, and at the time of data-cut, they were still under surveillance with no macroscopic or low volume metastatic disease.

First-line palliative chemotherapy was offered to eight patients with metastatic ovarian leiomyosarcoma. Doxorubicin alone or in combination with ifosfamide as first-line palliative chemotherapy was administered in four out of eight patients. One woman (Patient 1) had 60% reduction in her disease, after receiving eight cycles of ifosfamide-doxorubicin, by RECIST 1.1. First-line gemcitabine plus docetaxel (six cycles) was given in two cases (Patients 4 and 7), with one partial response seen in Patient 4 (31% tumoral reduction by RECIST).

Two patients, Patients 8 and 15, presented with two different biopsy-proven malignancies and received platinum-based regimens as first-line treatment, with the best response being stable disease. Patient 8 had a metastatic leiomyosarcoma of the ovary and a primary lung cancer, therefore, she received carboplatin-gemcitabine as first-line therapy. Patient 15 was treated with epirubicin-carboplatin as she had a concomitant head and neck squamous cell carcinoma alongside with her metastatic ovarian leiomyosarcoma. Her sarcoma remained stable after 4 cycles of treatment received to date. Both these patients underwent resection of their second malignancy. It is possible that the high incidence (2 out of 15 patients) of a second cancer in our cohort of ultra-rare cancers is due to the close radiological surveillance, although a familial predisposition could not be excluded. The median duration from the start of first-line palliative chemotherapy to progressive disease in all patients was 8 months (range 4–12).

Second-line chemotherapy was given to 4 patients and included trabectedin, doxorubicin and pazopanib. The best response in this group was stable disease. The median duration from the start of second-line systemic therapy to progressive disease was 7.5 months (range 3–11). Third- and fourth-line systemic chemotherapy was given in 4 and 3 patients, respectively. Regimens contained single agent ifosfamide, doxorubicin, trabectedin, dacarbazine or cyclophosphamide. The best radiological response for third- and fourth-line treatment was stable disease.

Two women (Patients 4 and 5) have received radiation with palliative intent for symptomatic bone deposits. However, radiotherapy did not offer any local disease control for these two patients. Although most of these tumours expressed oestrogen or progesterone receptors, none of our patients received endocrine therapy for their cancer, mainly due to lack of published evidence or aggressive behavior necessitating treatment with chemotherapy.

4.3. Overall survival

At the time of the analysis, seven patients have died of their disease. The median follow-up for our cohort was 18 months (range 2–98). The median survival rates were lower for the group of patients with metastatic disease at presentation (FIGO stage IV) with a median overall survival of 18 months (95%CI 0.0 – 43.6), compared to the patients with localized disease at diagnosis (FIGO stages I-IIIa) where median overall survival was 56 months (95% CI 45.5–66.4), $p = 0.004$, hazard ratio for localized disease = 0.75 (95%CI 0.0–0.7) (Fig. 1). The estimated median overall survival for the 11 patients with metastatic disease in our study

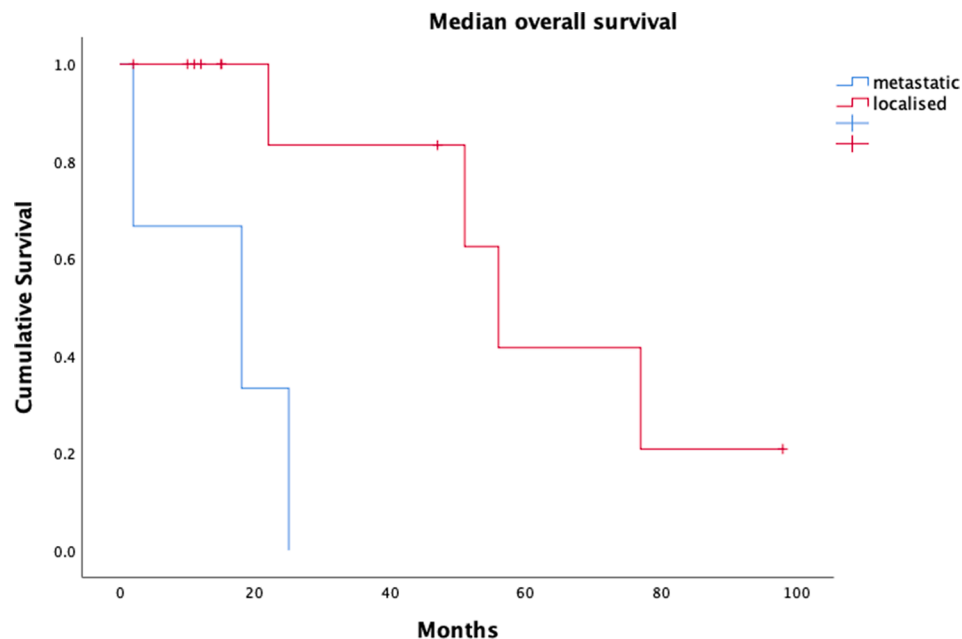


Fig. 1. Median overall survival for all patients with primary ovarian leiomyosarcoma. Metastatic corresponds to stage IV FIGO, whereas localised is stage I-III FIGO.

was 51 months (95%CI 0.0–113.5). Subgroup analysis was not possible due to low number of patients.

5. Discussion

Primary ovarian leiomyosarcomas are a very rare sarcoma subtype, accounting for 0.8% of all leiomyosarcomas in our database and have limited treatment options in the metastatic setting. The prognosis of this cancer is poor, with reported 5-year survival rates less than 20% (Anderson et al., 1987; Dai, 2011). Furutake and colleagues have analyzed the survival data of 56 cases reported in the literature. The median overall survival was 48 months and 40% of these patients died within 24 months. The median survival was 14 months for stage III/IV FIGO and 18 months for stage II FIGO, compared to 63 months for stage I FIGO (Furutake et al., 2017).

In our study, only 4 patients (26%) were recurrence-free at the time of data-cut analysis. However, as the surveillance period was short (8–15 months), it is possible that these patients would eventually relapse during their follow-up period. Other 2 patients with metastatic disease (13%) had indolent low volume disease, having been managed with a combination of active surveillance and local therapies. This suggests that some patients with metastatic primary ovarian leiomyosarcomas can have an indolent clinical course, and systemic therapy can be kept in reserve. This is supported by the fact that the median overall survival for all patients with metastatic disease in our series was 51 months. The overall survival within our cohort is consistent with previously published cases (Pankaj et al., 2013; Goodalla et al., 2011; Arslan, 2011; Meng, 2016; Monk et al., 1993; Rasmussen, 1997; Nazneen, et al., 2016; Taşkin, 2007; Friedman and Mazur, 1991; Kurian et al., 2005; Inoue et al., 2000; Tanaka et al., 2018; Kaur, 2014; Furutake et al., 2017; Bouie, 2005; Kumar Vijaya et al., 2015; Bodner et al., 2003; Lerwill et al., 2004; Dixit, 1993; Brahima, 2017; Hensley et al., 2014).

The recommended initial treatment for primary ovarian leiomyosarcoma is complete resection (Dixit, 1993; Brahima, 2017). The Gynecological cancer InterGroup (GCIG) consensus review on uterine and ovarian leiomyosarcoma published in 2014 proposes total hysterectomy (TAH) and bilateral salpingo-oophorectomy (BSO) as initial surgical approach for ovarian leiomyosarcoma (Hensley et al., 2014). There is no proven benefit for adjuvant chemotherapy (Monk et al., 1993; Rasmussen, 1997; Taşkin, 2007; Tanaka et al., 2018; Furutake et al., 2017;

Kumar Vijaya et al., 2015; Bodner et al., 2003). Surgery should be followed by close surveillance for 10 years. The majority of patients will have local or distant relapse within the first two years. In the metastatic setting, our data, as well as retrospective case reports, suggest that prolonged tumour control can be obtained with chemotherapy, surgery, radiotherapy or radiofrequency ablation in some women with bone, liver or lung metastases (Rasmussen, 1997; Furutake et al., 2017). Palliative chemotherapy used for other soft tissue sarcomas has shown some benefit in metastatic leiomyosarcoma, most commonly used regimens containing doxorubicin +/- ifosfamide, gemcitabine-docetaxel, trabectedin and platinum salts.

The response rate and time to progression for patients treated with palliative systemic therapy are broadly similar to metastatic leiomyosarcoma arising from other anatomic locations, despite the clear limitations of such a comparison. Our study suggests that patients with metastatic primary ovarian leiomyosarcoma requiring systemic therapy should be treated with a similar algorithm to other leiomyosarcomas (Bathan et al., 2013).

To our knowledge, this is the largest case series of primary ovarian leiomyosarcomas published to date, providing important information regarding the high metastatic rate of this tumour and treatment outcomes in the metastatic setting. The limitations of this study include a low number of patients and the retrospective descriptive analyses. Further collaborative work with other specialist gynecological and sarcoma centers is required to improve the outcome of patients with this very rare disease.

CRedit authorship contribution statement

Elena Cojocaru: Conceptualization, Data curation, Supervision. **Githmi Palahepitiva Gamage:** Conceptualization, Data curation, Supervision. **John Butler:** Data curation, Supervision. **Desmond P. Barton:** Data curation, Supervision. **Khin Thway:** Supervision. **Cyril Fisher:** Supervision. **Christina Messiou:** Supervision. **Aisha B. Miah:** Supervision. **Shane Zaidi:** Supervision. **Spyridon Gennatas:** Data curation, Supervision. **Charlotte Benson:** Supervision. **Paul Huang:** Supervision. **Robin L. Jones:** Conceptualization, Supervision.

Declaration of Competing Interest

The authors declare that they have no known competing financial interests or personal relationships that could have appeared to influence the work reported in this paper.

Acknowledgements

We thank to Mr Omar Al-Muderis for his help in collecting the data.

References

- Anderson, B., Turner, D.A., Benda, J., 1987. Ovarian sarcoma. *Gynecol. Oncol.* 26 (2), 183–192. [https://doi.org/10.1016/0090-8258\(87\)90272-1](https://doi.org/10.1016/0090-8258(87)90272-1). PMID: 3643159.
- Arslan, O.S., et al., 2011. A rare tumor of the female genital tract: primary ovarian leiomyosarcoma. *Arch. Gynecol. Obstet.* 283 (Suppl 1), 83–85. <https://doi.org/10.1007/s00404-010-1735-3>. PMID: 21061129.
- Bathan, A.J., Constantinidou, A., Pollack, S.M., Jones, R.L., 2013. Diagnosis, prognosis, and management of leiomyosarcoma: recognition of anatomic variants. *Curr. Opin. Oncol.* 25 (4).
- Bodner K, Bodner-Adler B, Czerwenka K, Hudelist G, Kimberger O, Leodolter S, Mayerhofer K: Bcl-2 expression in a primary leiomyosarcoma of the ovary: a case report. *Wien Klin Wochenschr.* 2003 Mar 31;115(5-6):191-5. PMID 12741081.
- Bouie, S.M., 2005. Cracchiolo B and Heller D (2005) Epithelioid leiomyosarcoma of the ovary. *Gynecol. Oncol.* 97 (2), 697–699. <https://doi.org/10.1016/j.ygyno.2005.02.008>.
- Brahima, et al., 2017. A rare ovarian tumour: primitive leiomyosarcoma of the ovary. *J. Gynecol. Reprod. Med.* 1 (2).
- Dai, Y., et al., 2011. Primary sarcoma of the ovary: clinicopathological characteristics, prognostic factors and evaluation of therapy. *Chin. Med. J. (Engl)* 124 (9), 1316–1321. PMID: 21740740.
- Dixit, S., et al., 1993. Leiomyosarcoma of the ovary. *J. Postgrad. Med.* 39 (3), 151–153. PMID: 8051647.
- Friedman, H.D., Mazur, M., 1991. Primary ovarian leiomyosarcoma. An immunohistochemical and ultrastructural study. *Arch. Pathol. Lab Med.* 115 (9), 941–945. PMID: 1929791.
- Furutake, Y., Fukagawa, T., Suga, Y., et al., 2017. Gemcitabine and docetaxel in a patient with primary ovarian leiomyosarcoma: a case report and review of literature. *Int. Can. Conf. J.* (7), 11–15. <https://doi.org/10.1007/s13691-017-0309-7> (Accessed: 24 Feb 2020).
- Goodalla, E.J., Madhuria, T., Manuela, S.B., 2011. The management dilemma of leiomyosarcoma of the ovary. *World J. Oncol.* 2 (5), 265–266. <https://doi.org/10.1007/s13691-017-0309-7> (Accessed: 25 Feb 2020).
- Hensley, M.L., Barrette, B.A., Baumann, K., Gaffney, D., Hamilton, A.L., Kim, J.W., Maenpaa, J.U., Pautier, P., Siddiqui, N.A., Westermann, A.M., Ray-Coquard, I., 2014. Gynecologic Cancer InterGroup (GCG) consensus review: uterine and ovarian leiomyosarcomas. *Int. J. Gynecol. Can.* 24 (9 Suppl 3), S61–S66. <https://doi.org/10.1097/JG.C.0000000000000261>. PMID: 25341583; PMCID: PMC4830912.
- Inoue, J., Gomibuchi, H., Minoura, S., 2000. A case of a primary ovarian leiomyosarcoma. *J. Obstet. Gynaecol. Res.* 26 (6), 401–407. <https://doi.org/10.1111/j.1447-0756.2000.tb01349.x>. PMID: 11152324.
- Kaur, et al., 2014. Primary ovarian leiomyosarcoma: a case report with review. *Int. J. Reprod. Contracept. Obstet. Gynecol.* 3 (1), 258–260.
- Kumar Vijaya J, Khurana Anil, Kaur Paramjeet, Chuahan Ashok K, Singh Sunita (2015) A rare presentation of primary leiomyosarcoma of ovary in a young woman. *ecancer*, (9), p524. Available at: <https://doi.org/10.1007/s13691-017-0309-7> (Accessed: 25 Feb 2020).
- Kurian, R.R., Preethi, J., Remadevi, A.V., 2005. Leiomyosarcoma of ovary—a case report, *Indian. J. Pathol. Microbiol.* 48 (1), 19–20.
- Lerwill, M.F., Sung, R., Oliva, E., Prat, J., Young, R.H., 2004. Smooth muscle tumors of the ovary: a clinicopathologic study of 54 cases emphasizing prognostic criteria, histologic variants, and differential diagnosis. *Am. J. Surg. Pathol.* 28 (11), 1436–1451. <https://doi.org/10.1097/01.pas.0000141393.99300.d0>. PMID: 15489647.
- Meng, H.E., et al., 2016. Synchronous leiomyosarcoma and fibroma in a single ovary: a case report and review of the literature. *Oncol. Lett.* 11, 2510–2514. PMID 27073508.
- Monk, B.J., Nieberg, R., Berek, J.S., 1993. Primary leiomyosarcoma of the ovary in a perimenarchal female. *Gynecol. Oncol.* 48, 389–393. <https://doi.org/10.1006/gyno.1993.1067>. PMID: 8462904.
- Nazneen et al, Prolonged survival of a young female with high-grade pleomorphic leiomyosarcoma of ovary without recurrence, *The journal of Obstetrics and Gynaecology of India* (November – December 2016), 66 (S2): S639-S641.
- Pankaj, S., Choudhary, V., Singh, R.J., Harsvardhan, R., 2013. High grade pleomorphic leiomyosarcoma of ovary in young female: a case report. *World J. Surg. Res.* 2, 7–11.
- Rasmussen, C.C., et al., 1997. Stage IIIC ovarian leiomyosarcoma in a premenopausal woman with multiple recurrences: prolonged survival with surgical therapy. *Gynecol. Oncol.* 66 (3), 519–525. <https://doi.org/10.1006/gyno.1997.4824>. PMID: 9299270.
- Tanaka, A., Miyoshi, A., Kanao, S., Takeda, M., Mimura, M., Nagamatsu, M., Yokoi, T., 2018. Case Report of a Primary Ovarian Leiomyosarcoma Diagnosed by H-Caldesmon Staining. *Journal of Clinical Gynecology and Obstetrics, North America*, 7(1), p26-29. Available at: <https://doi.org/10.14740/jcgo477w> (Accessed: 26 Feb 2020).
- Taşkın, S., et al., 2007. Primary ovarian leiomyosarcoma: A review of the clinical and immunohistochemical features of the rare tumor. *Obstet. Gynecol. Surg.* 62, 480–488. <https://doi.org/10.1097/01.ogx.0000268629.16151.71>.