



Review Article

## Traumatic atlantoaxial rotatory subluxation in adults – A case report and literature review

Hugo Layard Horsfall<sup>1</sup>, Aref-Ali Gharooni<sup>1</sup>, Alaa Al-Mousa<sup>2</sup>, Anan Shtaya<sup>3</sup>, Erlick Pereira<sup>3</sup>

<sup>1</sup>Division of Neurosurgery, Department of Clinical Neurosciences, Addenbrooke's Hospital and University of Cambridge, Cambridge, United Kingdom, <sup>2</sup>Department of General and Special Surgery, Faculty of Medicine, The Hashemite University, Zarqa, Jordan, <sup>3</sup>Department of Neurosurgery, St George's University Hospital NHS Foundation Trust, London, United Kingdom.

E-mail: Hugo Layard Horsfall - hl526@cam.ac.uk; Aref-Ali Gharooni - aag56@cam.ac.uk; \*Alaa Al-Mousa - amousa80@yahoo.com; Anan Shtaya - ashtaya@sgul.ac.uk; Erlick Pereira - dr.eacp@gmail.com



**\*Corresponding author:**

Alaa Al-Mousa,  
Department of General and  
Special Surgery, Faculty of  
Medicine, The Hashemite  
University, Zarqa, Jordan.

amousa80@yahoo.com

Received : 24 September 2020

Accepted : 07 October 2020

Published : 06 November 2020

DOI

10.25259/SNI\_671\_2020

Quick Response Code:



### ABSTRACT

**Background:** Traumatic atlantoaxial rotatory subluxation (AARS) is extremely rare in adult versus pediatric populations. Patients usually present with post-traumatic neck pain and torticollis. Surgical management aims at reducing the deformity and stabilizing the spine utilizing external orthotics, and/or internal reduction/fixation.

**Methods:** A 65-year-old female fell downstairs at home. She complained of neck pain with right-sided tenderness and torticollis. The radiographic studies and CT scan demonstrated AARS. This led to an emergent open reduction with internal fixation at the C1-C2 level.

**Results:** We identified 25 similar cases of AARS in the English literature. Patients averaged 28.7 years of age and mostly sustained motor vehicle accidents largely treated with traction/orthotics; only six patients required surgical open reduction/internal fixation.

**Conclusion:** In this case, the patient's C1-C2 deformity required open reduction/internal fixation rather than bracing alone.

**Keywords:** Atlantoaxial, Atlantoaxial dislocations, Atlantoaxial rotatory subluxation, Cervical spine, Rotatory, Subluxation, Trauma

### INTRODUCTION

Atlantoaxial dislocations are a heterogeneous group of C1-C2 rotatory subluxations involving the inferior atlanto and superior axial facet articulations.<sup>[3,5]</sup>

Definitive management of such traumatic unilateral atlantoaxial rotatory subluxation (AARS) varies due to the unique biomechanics of these injuries; they often require an individualized approach.<sup>[6]</sup> Type I lesions notably occur without attendant ligamentous rupture, allowing the dens to "pivot." Here, we describe a rare case of traumatic Type 1 C1-C2 AARS that occurred in a 65-year-old female due to a fall that required open reduction/internal fixation.

### CASE REPORT

A 65-year-old female sustained a fall from ten steps at her home. She presented with stiffness/neck pain and reduced range of movement. On examination, she had cervical (C5-C7) and

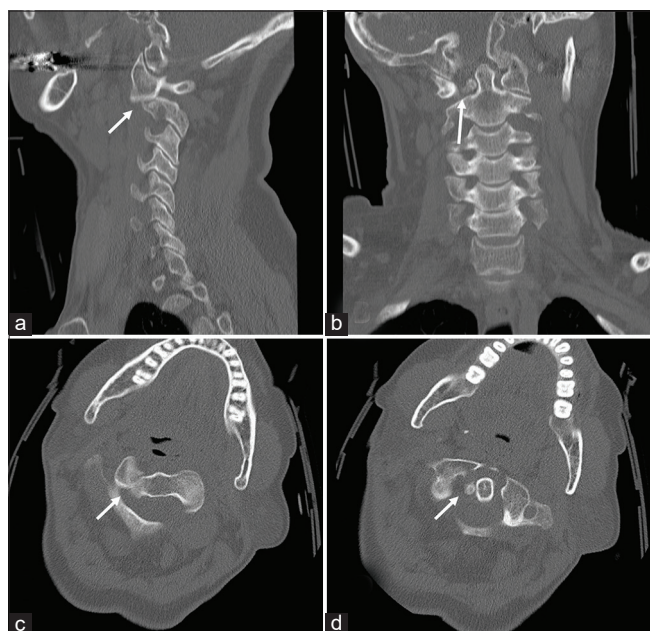
This is an open-access article distributed under the terms of the Creative Commons Attribution-Non Commercial-Share Alike 4.0 License, which allows others to remix, tweak, and build upon the work non-commercially, as long as the author is credited and the new creations are licensed under the identical terms.

©2020 Published by Scientific Scholar on behalf of Surgical Neurology International

thoracic (T7-L2) spine tenderness and torticollis toward the right. The neurological examination was normal. When plain films demonstrated a T11 fracture, she was placed in a TLSO. In addition, the CT showed a unilateral atlantoaxial rotatory subluxation with a locked right C1 facet and a right-sided intracanalicular bony fragment adjacent to the odontoid process [Figure 1a-d]. The cervical MR confirmed AARS with mal-alignment, right rotatory subluxation of C1 (e.g., less than a third of the articular surfaces were in contact), and a thinned ligamentum flavum narrowing of the spinal canal at the C1 level without spinal cord compression. Further, the transverse and alar ligaments remained intact (Fielding Type I AARS injury) [Figure 2].

### Surgery

Within 24 h of the fall, and after a failed attempt at external reduction under general anesthesia, the patient underwent an open surgical reduction, and Harms-technique of C1-C2 fusion.<sup>[4]</sup> The patient's T11 fracture although initially managed conservatively (e.g., with bed rest and analgesia) 3 weeks later required T10-T12 percutaneous spinal screw/fixation. The patient uneventfully recovered from both surgeries. The 3-month postoperative cervical films showed satisfactory C1-C2 fusion without instability. Further, at 6 months post-surgery, she was fully neurologically intact [Figures 3 and 4].



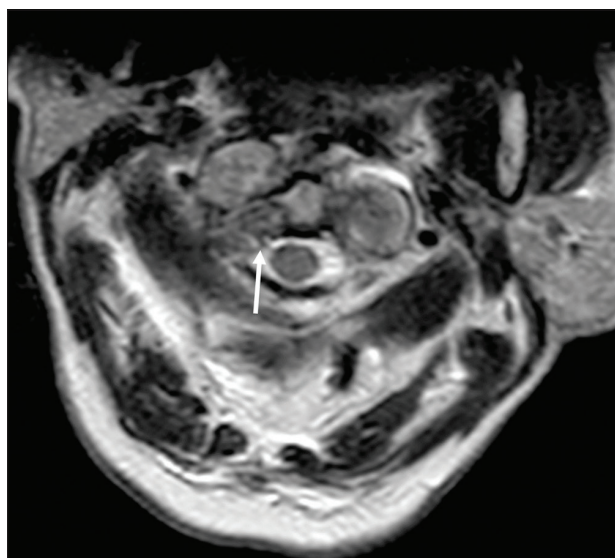
**Figure 1:** Preoperative CT cervical spine. Sagittal (a), coronal (b), and axial (c and d) bone window CT cervical spine images demonstrate the right atlantoaxial rotatory subluxation (arrows), where the atlas has rotated on the odontoid with no anterior displacement.

### DISCUSSION

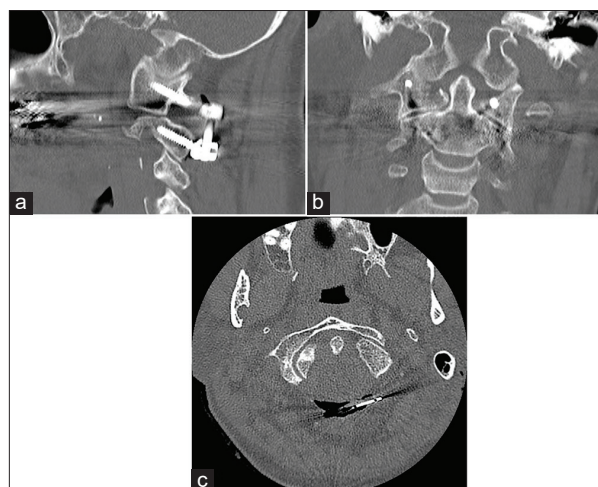
Atlantoaxial subluxation is rare in the elderly, and early diagnosis and treatment are essential to ensure satisfactory neurological outcomes. Although CT remains the gold standard for documenting these injuries, those with suspected AARS should also undergo MRI for fuller evaluation of the attendant soft tissue injuries (e.g., ligamentous injuries, and/or extent of spinal cord compression).<sup>[1,2]</sup>

### Literature review of AARS

Using MEDLINE, we identified 25 adults who previously sustained C1-C2 AARS injuries [Tables 1 and 2]. For adults



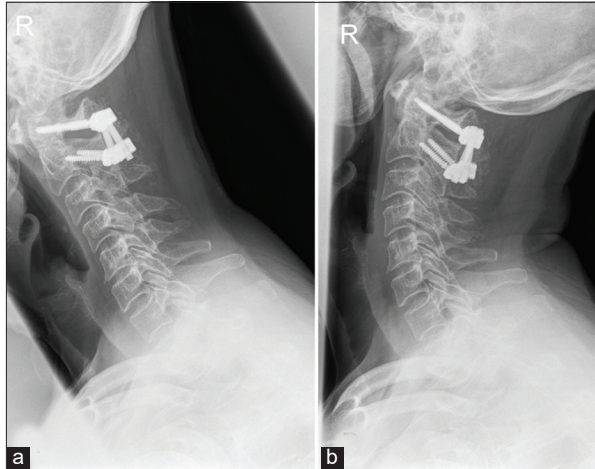
**Figure 2:** Preoperative axial T2W MRI image shows the rotatory subluxation (arrow).



**Figure 3:** Postoperative CT cervical spine. Sagittal (a), coronal (b), and axial (c) bone window CT cervical spine day 2 after surgery demonstrates the restoration of C1-C2 alignment.

**Table 1:** Summary of reported cases of atlantoaxial subluxation in adults.

Report	Sex, age	Mechanism	Time to diagnosis (days)	Fielding classification	Management	Outcome
Jones, 1984	Male, 18	Sports accident	0	Type III	Halter traction + cervical collar	No sequelae
Robertson and Swan, 1992	Male, 18	Sports accident	0	Type IV	Halter traction + SOMI brace	30° loss of rotation to right
Wise et al., 1997	Female, 29	Road traffic accident	0	Type III	Gardner-Well tongs traction and halo vest	No sequelae
Castel et al., 2001	Male, 41	Sports accident	30	Type I	Cervical traction + Minerva jacket	No sequelae
Crook and Eynon, 2005	Female, 15	Sports accident	0	Type I	Cervical traction + cervical collar	No sequelae
Kim et al., 2007	Male, 34	Mechanical fall	1	Type II	Cervical traction + posterior fusion + hard collar	No sequelae
Haliasos and Norris, 2007	Female, 19	Road traffic accident	0	Type I	Cervical traction + cervical collar	No sequelae
Sinigaglia et al., 2008	Female, 26	Road traffic accident	45	N/A	Cervical traction + halo vest	Neck stiffness and headache
	Female, 21	Road traffic accident	1	N/A	Cervical traction + halo vest	No sequelae
	Male, 29	Road traffic accident	1	N/A	Cervical traction + cervical collar	No sequelae
Wang et al., 2008	Female, 44	Undescribed	180	Type I	Halo vest	Weakness in both hands
Singh et al., 2009	Female, 25	Road traffic accident	0	Type I	Cervical traction + halo brace	No sequelae
Jeon et al., 2009	Female, 25	Road traffic accident	5	Type I	Cervical traction + cervical collar	No sequelae
Marti et al., 2011	Female, 24	Stretching and cervical rotation by herself	1	Type I	Cervical traction + halo vest	No sequelae
Dholakia et al., 2012	Female, 21	Road traffic accident	180	Type I	Open reduction and internal fixation	No sequelae
Venkatesan et al., 2012	Female, 20	Road traffic accident	0	Type I	Cervical traction + cervical collar	Occipital pain
	Female, 52	Road traffic accident	0	Type II	Halo-traction + cervical collar	Occipital pain and neck rotation limited to 30° bilaterally
Maida et al., 2012	Female, 27	Road traffic accident	Few days	Type I	Manual reduction + cervical collar + posterior fusion	Loss of 30° of cervical rotation and occipital neuralgia
Escobar et al., 2012	Female, 19	Road traffic accident	0	Type I	Cervical traction + cervical collar	No sequelae
Taratino et al., 2014	Female, 34	Epileptic seizure	60	Type I	Cervical traction + posterior fusion + brace + collar	No sequelae
Min Han et al., 2014	Male, 22	Road traffic accident	0	Type I	Cervical traction + cervical collar	No sequelae
Garcia-Pallero et al., 2016	Female, 28	Road traffic accident	7	Type I	Cervical traction + cervical collar	Mild occipital neuralgia
Hawi et al., 2016	Female, 34	Road traffic accident	0	Type I	Cervical traction + cervical collar	No sequelae
Eghbal et al., 2017	Male, 35	Mechanical fall	11	Type I	Cervical traction + posterior fusion	No sequelae
Opoku-Darko et al., 2017	Female, 20	Road traffic accident	0	Type II	Cervical traction + posterior fusion	No sequelae
This case report	Female, 65	Mechanical fall	1	Type I	Cervical traction + posterior fusion	No sequelae



**Figure 4:** Flexion (a) and extension (b) cervical spine X-ray at 3 months follow-up shows absence of C1-C2 instability.

**Table 2:** Summary of reported cases characteristics.

Age	28.7 (15–65)
M:F	7:19
Fielding Type I	17 out of 23 (73.9%)
Operative treatment	7 out of 26 (26.9%)

with Type I Fielding injuries, immobilization can result in good outcomes. However, for older patients, this may not sufficiently reduce the subluxation in a timely fashion. Therefore, some older patients may require open reduction/internal fixation due to osteophytic changes accompanied by locked facets to maximize the quality of outcomes.

## CONCLUSION

AARS (especially Fielding I) following cervical trauma is rare in the elderly.

Both CT and MRI studies are essential for documenting the extent of C1-C2 injury, and there should be a low threshold for open operative reduction/fixation.

## Declaration of patient consent

Patient's consent not required as patients identity is not disclosed or compromised.

## Financial support and sponsorship

Nil.

## Conflicts of interest

There are no conflicts of interest.

## REFERENCES

1. Chaudhary SB, Martinez M, Shah NP, Vives MJ. Traumatic atlantoaxial dislocation with hangman fracture. *Spine J* 2015;15:e15-8.
2. García-Pallero MA, Torres CV, Delgado-Fernández J, Sola RG. Traumatic atlantoaxial rotatory fixation in an adult patient. *Eur spine J* 2019;28:284-9.
3. Missori P, Miscusi M, Paolini S, DiBiasi C, Finocchi V, Peschillo S, et al. A C1-2 locked facet in a child with atlantoaxial rotatory fixation. Case report. *J Neurosurg* 2005;103 Suppl 6:563-6.
4. Sikander M, Martin S, Dabbous B, Griffiths S, Pereira SK, Cadoux-Hudson T. Combined C1-C2 transarticular with C1 lateral mass screw fixation for the treatment of atlantoaxial instability: A single center experience. *J Spinal Surg* 2016;3: 133-9.
5. Singh VK, Singh PK, Balakrishnan SK, Leitao J. Traumatic bilateral atlantoaxial rotatory subluxation mimicking as torticollis in an adult female. *J Clin Neurosci* 2009;16:721-2.
6. Tarantino R, Donnarumma P, Marotta N, Missori P, Viozzi I, Landi A, et al. Atlanto axial rotatory dislocation in adults: A rare complication of an epileptic seizure-case report. *Neurol Med Chir (Tokyo)* 2014;54:413-6.

**How to cite this article:** Horsfall HL, Gharooni A, Al-Mousa A, Shtaya A, Pereira E. Traumatic atlantoaxial rotatory subluxation in adults – A case report and literature review. *Surg Neurol Int* 2020;11:376.