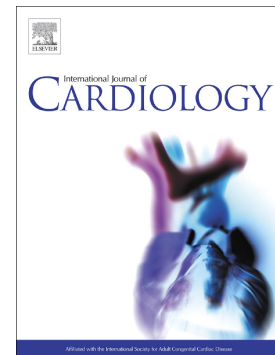


Diagnosis of arrhythmogenic cardiomyopathy: The Padua criteria

Domenico Corrado, Martina Perazzolo Marra, Alessandro Zorzi, Giorgia Beffagna, Alberto Cipriani, Manuel De Lazzari, Federico Migliore, Kalliopi Pilichou, Alessandra Rampazzo, Ilaria Rigato, Stefania Rizzo, Gaetano Thiene, Aris Anastasakis, Angeliki Asimaki, Chiara Bucciarelli-Ducci, Kristine H. Haugaa, Francis E. Marchlinski, Andrea Mazzanti, William J. McKenna, Antonis Pantazis, Antonio Pelliccia, Christian Schmied, Sanjay Sharma, Thomas Wichter, Barbara Bauce, Cristina Basso



PII: S0167-5273(20)33293-9

DOI: <https://doi.org/10.1016/j.ijcard.2020.06.005>

Reference: IJCA 28681

To appear in: *International Journal of Cardiology*

Received date: 29 May 2020

Accepted date: 1 June 2020

Please cite this article as: D. Corrado, M.P. Marra, A. Zorzi, et al., Diagnosis of arrhythmogenic cardiomyopathy: The Padua criteria, *International Journal of Cardiology* (2018), <https://doi.org/10.1016/j.ijcard.2020.06.005>

This is a PDF file of an article that has undergone enhancements after acceptance, such as the addition of a cover page and metadata, and formatting for readability, but it is not yet the definitive version of record. This version will undergo additional copyediting, typesetting and review before it is published in its final form, but we are providing this version to give early visibility of the article. Please note that, during the production process, errors may be discovered which could affect the content, and all legal disclaimers that apply to the journal pertain.

DIAGNOSIS OF ARRHYTHMOGENIC CARDIOMYOPATHY: THE PADUA CRITERIA

Domenico Corrado^{1,*} domenico.corrado@unipd.it, Martina Perazzolo Marra¹, Alessandro Zorzi¹, Giorgia Bèffagna¹, Alberto Cipriani¹, Manuel De Lazzari¹, Federico Migliore¹, Kalliopi Pilichou¹, Alessandra Rampazzo², Ilaria Rigato¹, Stefania Rizzo¹, Gaetano Thiene¹, Aris Anastasakis³, Angeliki Asimaki⁴, Chiara Bucciarelli-Ducci⁵, Kristine H Haugaa⁶, Francis E Marchlinski⁷, Andrea Mazzanti⁸, William J McKenna⁹, Antonis Pantazis¹⁰, Antonio Pelliccia¹¹, Christian Schmied¹², Sanjay Sharma¹³, Thomas Wichter¹⁴, Barbara Baucè¹, Cristina Basso¹

¹Department of Cardiac, Thoracic and Vascular Sciences, University of Padova, Italy

²Department of Biology, University of Padova, Italy

³Unit of Inherited and Rare Cardiovascular Diseases, Onassis Cardiac Surgery Centre, Leof. Andrea Siggrou 356, Kallithea 176 74, Greece

⁴Molecular and Clinical Sciences Research Institute, St. George's University of London NHS Trust, Cranmer Terrace, London SW17 0RE, UK

⁵Department of Cardiology, Bristol Heart Institute, University Hospitals Bristol NHS Foundation, Trust Headquarters, Marlborough St, Bristol BS1 3NU, UK

⁶Department of Cardiology, Center for Cardiologial Innovation, Oslo University Hospital, Rikshospitalet, Sognsvannsveien 20, 0372 Oslo, Norway

⁷Cardiac Electrophysiology Program, Cardiovascular Division Hospital of the University of Pennsylvania, 9 Founders Pavilion - Cardiology, 3400 Spruce St., Philadelphia, PA, 19104, USA

⁸Department of Molecular Medicine, University of Pavia, Corso Str. Nuova 25, Pavia, Italy

⁹Institute of Cardiovascular Science, University College London, London, UK

¹⁰Inherited Cardiovascular Conditions services, The Royal Brompton and Harefield Hospitals, Sydney St, Chelsea, London SW3 6NP, UK

¹¹Department of Cardiology, Institute of Sports Medicine and Science, Largo Piero Gabrielli, 1, 00197 Roma, Italy

¹²Department of Cardiology, University Heart Center Zurich, University Hospital Zurich, Raemistrasse 100, 8091 Zurich, Switzerland

¹³Cardiology Clinical Academic Group, St George's University of London, Cranmer Terrace, Tooting, London SW17 0RE, UK

¹⁴Heart Center Osnabrück, Bad Rothenfelde Niels-Stensen-Kliniken Marienhospital Osnabrück, Ulmenallee 5 - 11, 49214 Bad Rothenfelde, Germany

*Corresponding author at: Department of Cardiac, Thoracic and Vascular Science, Via Giustiniani, 2 - 35121 Padova (Italy).

ABSTRACT

The original designation of “Arrhythmogenic right ventricular (dysplasia/) cardiomyopathy”(ARVC) was used by the scientists who first discovered the disease, in the pre-genetic and pre-cardiac magnetic resonance era, to describe a new heart muscle disease predominantly affecting the right ventricle, whose cardinal clinical manifestation was the occurrence of malignant ventricular arrhythmias. Subsequently, autopsy investigations, genotype-phenotype correlations studies and the increasing use of contrast-enhancement cardiac magnetic resonance showed that the fibro-fatty replacement of the myocardium represents the distinctive phenotypic feature of the disease that affects the myocardium of both ventricles, with left ventricular involvement which may parallel or exceed the severity of right ventricular involvement. This has led to the new designation of “Arrhythmogenic Cardiomyopathy” (ACM), that represents the evolution of the original term of ARVC. The present International Expert Consensus document proposes an upgrade of the criteria for diagnosis of the entire spectrum of the phenotypic variants of ACM. The proposed “Padua criteria” derive from the diagnostic approach to ACM, which has been developed over 30 years by the multidisciplinary team of basic researchers and clinical cardiologists of the Medical School of the University of Padua. The Padua criteria are a working framework to improve the diagnosis of ACM by introducing new diagnostic criteria regarding tissue characterization findings by contrast-enhanced cardiac magnetic resonance, depolarization/repolarization ECG abnormalities and ventricular arrhythmia features for diagnosis of the left ventricular phenotype. The proposed diagnostic criteria need to be further validated by future clinical studies in large cohorts of patients.

INTRODUCTION

The original designation of “Arrhythmogenic right ventricular (dysplasia/) cardiomyopathy (ARVC)” was used by the scientists who first discovered the disease, in the pre-genetic and pre-

cardiac magnetic resonance (CMR) era, to describe a new heart muscle disease predominantly affecting the right ventricle (RV), whose cardinal clinical manifestation was the occurrence of malignant ventricular arrhythmias.¹⁻⁶ Subsequently, autopsy investigations, genotype-phenotype correlations studies and the increasing use of contrast-enhancement CMR (CE-CMR) showed that the fibro-fatty replacement of the myocardium represents the distinctive phenotypic feature of the disease and affects not only the RV but also the left ventricle. (LV).^{2,6-10} In the last decade there have been several pathologic and clinical studies that characterized the structural and electrical findings of the LV disease phenotype (Figure 1) and provided significant insights into diagnosis of left-sided disease.⁹⁻¹⁸ This has led to the new designation of “Arrhythmogenic Cardiomyopathy (ACM)” that represents the evolution of the original term ARVC and reflects the modern concept of a biventricular muscle disease with LV involvement which may parallel or exceed the severity of RV involvement.¹⁹

A recent International Expert Report has provided an extensive critical review of the clinical performance of the available diagnostic criteria for ACM and identified potential areas of improvement.² Major limitations of the current approach to the disease diagnosis addressed by the document include: (i) the incomplete understanding of the genetic background of the disease and the large genetic noise due to several variants of uncertain significance; ii) the absence of specific criteria for diagnosis of the broader spectrum of the disease phenotypes which includes left-sided variants; iii) the lack of tissue characterization findings by CE-CMR which offers the potential to identify myocardial fibrosis and play a key role for accurate diagnosis of the LV phenotype.

The present report represents a further step towards the necessary upgrading of the criteria for diagnosis of the entire spectrum of phenotypic variants of ACM and provides a modern clinical flow-chart for the diagnosis of ACM. The proposed criteria derive from the diagnostic approach to ACM, which has been developed over 30 years by the multidisciplinary team of basic

researchers and clinical cardiologists of the Medical School of the University of Padua. The writing panel was enriched by the inclusion of International Experts.

Definition and classification

“Arrhythmogenic Cardiomyopathy” is currently defined as a genetic heart muscle disease which affects the RV, the LV or both, whose most distinctive phenotypic feature is myocardial scar (fibro or fibrofatty myocardial replacement) which underlies global and/or regional ventricular dysfunction and predisposes to potentially lethal scar-related ventricular arrhythmias, regardless of the severity of the systolic ventricular dysfunction.^{8,20} While the adjective “arrhythmic” refers to the nonspecific outcome of every heart disease which manifests with rhythm and conduction disturbances, the adjective “arrhythmogenic” (the suffix *-genic* according to its etymology from ancient Greek *-γενής* means “tending to generate” arrhythmias) is disease-specific and denotes the distinctive *propensity* of ACM to develop ventricular arrhythmias, as a clinical reflection of the underlying fibro-fatty myocardial replacement which is the pathologic hallmark of the disease.

The current classification of ACM includes the following phenotypic variants:¹⁹ (i) the “*dominant-right*” variant, i.e., the classic ARVC phenotype characterized by the predominant RV involvement, with no or minor LV abnormalities; (ii) the “*biventricular disease*” variant characterized by the parallel involvement of the RV and LV; and (iii) the “*dominant-left*” variant (also referred to as “arrhythmogenic left ventricular cardiomyopathy; ALVC”) characterized by the predominant LV involvement, with no or minor RV abnormalities.

Recently, an expert panel of the Heart Rhythm Society (HRS) has provided a broader definition of ACM as an “arrhythmogenic heart muscle disorder not explained by ischemic, hypertensive, or valvular disease.²¹ ACM incorporates a broad spectrum of systemic (i.e., sarcoidosis, amyloidosis), inflammatory (i.e., myocarditis), an infectious (i.e., Chagas disease), or genetic (e.i.,

desmosomal ARVC or arrhythmogenic left ventricular cardiomyopathy [ALVC], lamin A/C, filamin-C, phospholamban) disorders and ion channel diseases”.²¹ According to the HRS document perspective, the common denominator of all these conditions is the “clinical presentation with symptoms or documentation of atrial fibrillation, conduction disease, and/or RV and/or LV arrhythmia”. There is a general agreement among the panelists of the present document that the “arrhythmic clinical presentation” does not provide a pathobiologically and clinically appropriate rationale for a re-definition of ACM as a non-specific entity which includes a miscellaneous group of heterogeneous heart muscle diseases.

DIAGNOSTIC CRITERIA

Similar to the previous 1994 and 2010 scoring systems (Online Supplemental Tables 1),^{4,22} the Padua criteria for diagnosis of ACM are based on a multi-parametric approach encompassing functional and structural ventricular abnormalities, tissue characterization findings, depolarization and repolarization electrocardiographic alterations and ventricular arrhythmias, and familial/genetic background which are grouped into 6 categories.

Table 1 summarizes the “Padua criteria” for each category for diagnosis of both the RV and LV involvement. The criteria reported in the left column represent an upgrade of the 2010 International Task Force (ITF) diagnostic criteria for the classic right-dominant ACM (ARVC), while those reported in the right column are new criteria for diagnosis of left-sided ACM (ALVC).

The novelty of the Padua diagnostic criteria essentially consists in the introduction of tissue characterization by CE-CMR for detection of fibro-fatty myocardial replacement of both ventricles and the addition of new ECG criteria, including depolarization/ repolarization abnormalities and ventricular arrhythmias, specific for the LV involvement.

The accuracy of diagnostic criteria for left-sided ACM varies according to the disease variant, whether *biventricular* or *left-dominant*. In the context of *biventricular* ACM, the disease-

specificity of the left-sided abnormalities is ensured by the concomitant fulfilment of ITF criteria for the RV phenotype. Hence, in patients who meet the upgraded 2010 diagnostic criteria for the RV phenotype, “biventricular” ACM can be reasonably diagnosed on the basis of phenotypic features of LV involvement, mostly morpho-functional and structural LV abnormalities. On the other hand, in patients with no (or minor) clinical RV abnormalities (not fulfilling the upgraded 2010 ITF criteria), the diagnosis of *left-dominant* ACM (ALVC) cannot be achieved on the basis of the LV phenotypic criteria only. In fact, morpho-functional and structural LV abnormalities of ACM do not provide a sufficient disease-specificity because of the overlap with the phenotypic features of other heart muscle diseases such as DCM, myocarditis, or cardiac sarcoidosis. Hence, diagnosis of “left-dominant” ACM requires, in addition to consistent LV phenotypic features, the demonstration of a positive genotyping for ACM-causing gene-mutation.

The approach used in the 1994 and 2010 ITF scoring systems for classifying morpho-functional, structural, histological, ECG, arrhythmic, and genetic features of the ARVC as “major” and “minor” criteria on the basis of their disease-specificity is maintained in the Padua criteria. With regard to the newly proposed diagnostic criteria for LV involvement, they are classified as “major” when they are deemed *specific and necessary* for diagnosis and “minor” when they are *not required*, but contribute to refine the characterization of the LV phenotype.

At variance with genetically-determined cardiac ion channel disorders, pathogenic mutations, ECG abnormalities or arrhythmias are not sufficient for diagnosis of ACM, which is a structural heart muscle disease. By analogy with the diagnosis of hypertrophic cardiomyopathy, that requires demonstration of critical LV hypertrophy,²³ at least one RV or LV criterion from categories I (i.e., morpho-functional ventricular abnormalities) or II (i.e., structural myocardial abnormalities), either major or minor is mandatory to reach a definite diagnosis of ACM according to the Padua criteria.

I. Morpho-functional ventricular abnormalities (i.e., global and regional ventricular dilatation and systolic dysfunction)

Right ventricle: Previous distinction of morpho-functional criteria in *major* and *minor*, based on the severity of global RV dilatation and dysfunction, appears more useful for prognostic than for diagnostic purposes and has been eliminated. The upgraded 2010 diagnostic criteria have been simplified to include only one **major morpho-functional criterion**, which is fulfilled when regional wall motion abnormalities, such as RV akinesia, dyskinesia or bulging are associated with either RV dilatation or dysfunction, regardless of their severity. In addition, a new **minor morpho-functional criterion** has been introduced which is met by the demonstration of regional RV wall motion abnormalities in the absence of RV dilatation and/or systolic dysfunction. The introduction of this latter criterion aims to increase the diagnostic sensitivity in a sizeable proportion of patients who show consistent RV wall motion abnormalities with normal global cavity size and preserved systolic function. This pattern reflects the segmental nature of RV lesions which may manifest as areas of fibro-fatty myocardial replacement that may alter the regional contractility without compromising the global hemodynamics of the RV.^{10,18,19,24-26} The “minor” diagnostic power of this criterion is explained by the limited specificity of the subjective evaluation of wall motion abnormalities on echocardiography and CMR imaging.

In the 2010 ITF criteria, reference values of normal RV end-diastolic volumes (up to 110 ml/m² in men and 100 ml/m² in women) were derived from 462 healthy controls of the multiethnic study of atherosclerosis (MESA), in which quantification of ventricular volumes was obtained using the older fast gradient echo CMR cine technique that underestimates volumes because of incomplete and lower endocardial border definition.⁴ Cardiac chamber volumes are more accurately measured by the modern CMR cine technique with steady-state free precession (SSFP) images which provides superior contrast between blood and endocardium at the endocardial border with less blood flow dependence.^{27,28} Diagnostic accuracy of both echocardiography and cine-CMR imaging findings is increased by the use of reference values for RV cavity size and systolic function normalized for age, sex and body surface area (BSA), according to current nomograms provided by international societies of cardiovascular imaging.²⁸

It is noteworthy that the cut-off values of RV dilatation may lack specificity in the athletic population because physiologic adaptive changes of the RV in athlete's heart may produce an increase of RV volume that goes well beyond the upper limit of normality reported in the general population.¹⁹ In this regard, proper reference values for RV volume in the athlete's heart are currently available and should be used in the differential diagnosis of physiologic versus pathologic RV dilatation in athletes, especially if engaged in sports such as rowing or canoeing associated with the greatest RV dimensional remodeling.²⁹

Left ventricle: Demonstration of LV systolic dysfunction (by depression of LV ejection fraction or reduction of LV global longitudinal strain), with or without LV dilatation is a **minor morpho-functional criterion** for diagnosing "biventricular" or "dominant-left" disease variants. This criterion is classified as *minor* because its low disease-specificity and because most patients show regional LV involvement without an increase of the cavity size and/or reduction of the global systolic function.⁸⁻¹⁹ This finding reflects the pathologic nature of ACM myocardial lesions which manifest as segmental and non-transmural (epi-midmyocardial) areas of fibro-fatty myocardial replacement, not compromising the global hemodynamics of the LV. In this regard, strain echocardiography has the ability to detect subtle changes and is useful in early disease.^{30,31} Diagnostic accuracy is increased by the use of reference values for LV cavity size and systolic function normalized for age, sex and body surface area (BSA), according to current nomograms provided by international societies of cardiovascular imaging.²⁷

Accordingly, also the imaging evidence of a regional LV wall hypokinesia or akinesia (rarely dyskinesia) with a preserved LV global systolic function is a useful morpho-functional

II. Structural myocardial abnormalities

(i.e., fibrous or fibro-fatty myocardial replacement)

Structural myocardial abnormalities of both ventricles are routinely investigated by CE-CMR, which has become the leading imaging modality for ACM diagnosis due to its capability of tissue characterization.^{2,30,31}

Although direct tissue characterization is obtained only by endomyocardial biopsy (EMB), the invasive nature and the potential risk of serious complications (although rare and occurring in low volume cardiovascular centers) of this technique limit its indication to selected cases of non-familial ACM for differential diagnosis with disease phenocopies.¹⁹ Specifically, EMB is indicated in probands with a sporadic form of ACM and negative genotyping, in whom the ultimate diagnosis depends on histologic study of the myocardium to exclude mimics such as myocarditis, sarcoidosis or other heart muscle disorders. Histologic demonstration of replacement-type fibrosis, with or without fatty tissue, on EMB samples remains a **major structural criterion** for diagnosis. The distinction of EMB findings in “**major**” and “**minor**” appears not longer justified.³² Due to possible sampling error, negative EMB findings do not exclude the diagnosis of ACM. Because the risk/benefit ratio of LV EMB is not known, at the present time this approach is not indicated for diagnosis of ACM.

Right ventricle: Tissue characterization by CE-CMR offers the potential to demonstrate the presence of RV myocardial LGE/fibrosis, with or without fatty tissue replacement on dedicated sequences. Tissue characterization findings by CE-CMR were not included in the previous 2010 ITF criteria because of the limited experience in their interpretation one decade ago. The assessment of LGE or fatty tissue in the thin RV free wall was considered difficult to the low resolution of CMR equipment, the protocol design, the inversion time set to null the LV myocardium and the inversion recovery sequence not fat suppressed.² Despite these limitations, the yield of RV LGE in ACM patients has been reported up to 88%, indicating that demonstration of LGE in the RV wall provides a significant added diagnostic value.^{26,33-35} The current availability of new generation CMR equipment with updated pulse sequences offers the potential to further enhance the accuracy for the identification of RV intramyocardial fibro-fatty scar tissue.² Recent studies demonstrated the usefulness of combined

regional wall motion assessment and tissue characterization by CMR for the diagnosis of ACM. The highest accuracy (98%) is achieved when wall motion alterations and pre/post-contrast signal abnormalities are considered together.³⁶ Accordingly, the demonstration of regional RV LGE (confirmed in two orthogonal planes, i.e. horizontal long-axis and short-axis views) with transmural involvement of the RV free wall is included in our upgrade of the 2010 criteria and classified **as a major structural myocardial criterion**. Indeed, it increases the specificity of the interpretation of RV wall motion abnormalities by demonstrating an underlying myocardial scar.

Left ventricle: Tissue characterization findings by CE-CMR offers the unique potential to diagnose the condition in all affected patients with LV involvement the presence of LGE/fibrosis, localized in the subepicardial (less often the mid-myocardial) layers of the LV free wall and most often affecting the inferolateral regions, with or without septal involvement.^{2,8-18} The coexistence of fatty myocardial infiltration is often observed on dedicated sequences in the same regions of LGE or in remote LV areas. Most important, the typical LV remodelling pattern resulting from this fibro(-fatty) myocardial scar involvement consists of an hypokinetic (or normokinetic) LV, with no or mild cavity dilatation.^{2,12,13,18} LV systolic dysfunction may become more severe in the advanced stages, being directly related to the disease progression and increasing extent of LGE, affecting multiple segments of the LV free wall and septum, with a more transmural involvement.¹⁸

Although all patients with LV involvement show LV LGE on CE-CMR, a sizeable proportion of them do not have associated global LV systolic dysfunction or overt wall motion abnormality.^{2,8,9,10,18,24,37,38} Hence, tissue characterization plays a key role allowing identification of LGE/fibrosis which is a the most sensitive feature for diagnosis of left-sided ACM. As a corollary, LV involvement cannot be ruled out based solely on imaging findings negative for LV functional abnormalities on echo, cine-CMR or angiography. Accordingly, demonstration of LV myocardial LGE/fibrosis in the form of a stria (or band) pattern affecting ≥ 1 segment (on the traditional “Bull’s Eye” system) is a **major and needed structural criterion** for diagnosis of left-sided ACM.

Of importance, the pattern of “junctional” LGE, which is characterized by focal/patchy involvement of the posterior (or less frequently anterior) ventricular septum at the site of RV attachment, is excluded from the diagnosis of ACM because of its non-pathologic nature.³⁸

III. ECG depolarization abnormalities

Late potentials on SAECG are not longer included among the Padua criteria, since the use of SAECG technique has been abandoned by most centres because of its non-specific findings and limited diagnostic accuracy.²

Right ventricle: The presence of epsilon waves in right precordial leads was classified as major ECG criterion in both the 1994 and the 2010 ITF criteria. However, diagnostic value of the epsilon wave has been questioned in the last decade, because its identification and interpretation are largely influenced by ECG filtering and sampling rate, giving rise to large interobserver variability.³⁹ Among the Padua diagnostic criteria for ACM, epsilon waves in right precordial leads are classified as a **minor ECG criterion**, likewise the ECG pattern of a QRS delayed S-wave upstroke with TAD ≥ 55 ms in right precordial leads (particularly if followed by negative T waves).⁴

Left ventricle: Low QRS voltages in the limb leads (“peak-to-peak QRS amplitude < 0.5 mV) may predict LV involvement in the context of ACM.^{12-14,17,18,24} The mechanism involved in the reduction of QRS voltages reasonably consists of the decrease of LV myocardial mass by fibrofatty replacement, which mostly accounts for the generation of the electrical activity causing the depolarization current responsible for the QRS complex. Why it mainly affects the limb leads remains to be elucidated. The low sensitivity of low QRS voltages (not exceeding 30%) may be explained by a dose-effect relationship between myocardial replacement by fibrofatty scar and reduction in QRS amplitudes in limb leads. This is in keeping with the finding of significantly higher number of LV segments affected by LGE in patients with low QRS voltages in limb leads than in those without this ECG abnormality.²⁴ Because of its low estimated specificity compared

with other diseases and normal control, low QRS voltages in the limb leads should be considered a **minor ECG repolarization criterion**.

IV. ECG repolarization abnormalities

Left ventricle: LV involvement can be predicted by the presence of T-wave inversion in the leads exploring the LV, mostly the left precordial leads V4-V6.^{8,9,18,19,24} However, this repolarization pattern is classified as a **minor ECG criterion**, because of its low disease-specificity. Most important, the extent of T wave inversion from right precordial (V1-V3) to left precordial leads (V4-V6) may predict a more severe RV dilation/dysfunction, rather than the involvement of the LV. As demonstrated by a recent ECG-CMR correlation study,²⁴ a severely dilated RV is displaced toward the axilla and a greater proportion of the ventricle is positioned under the ECG leads placed more laterally. Hence, the traditional LV leads (V4-V6) explore the electrical activity of the dilated and displaced RV rather than that of the LV.

V. Ventricular arrhythmias

In the upgraded criteria, premature ventricular beats (PVB) are evaluated not only in terms of absolute number (>500 PVB per 24 hours) and complexity (non-sustained or sustained VT), but also with regard to the morphology of the ectopic QRS.^{40,41} Hence, it is important for diagnosis to record ventricular arrhythmia morphology on 12-ECG leads by exercise testing or 12-lead 24-hour Holter monitoring.

Right ventricle: Similarly to non-sustained and sustained VT, PVBs originating from RV regions other than the RVOT have greater specificity for ACM (**major ventricular arrhythmia criterion**) than those from the RVOT (**minor ventricular arrhythmia criterion**).

Left ventricle: Ventricular arrhythmias with a RBBB morphology (suggesting the origin from the LV) may be an ECG marker of LV involvement (**minor ventricular arrhythmia criterion**).^{8,9,18,19,24}

VI. Family history/molecular genetics

According to the expert recommendations for genetic testing in ACM, genotyping is indicated to identify a pathogenic or likely pathogenic mutation in a proband with consistent phenotypic features of the disease and to apply mutation-specific cascade genetic testing for detection of gene carriers among family members in order to identify genetically affected individuals at a preclinical phase.^{2,42} The limitations of current understanding of the genetic basis of ACM and the high genetic noise due to frequent disease associated genetic variants both in the normal population and other cardiomyopathies pose the risk of misdiagnosis due to potential misinterpretation of molecular genetic results.^{43,44} Accordingly, confirmatory genotyping to achieve a diagnosis in a patient with borderline phenotypic manifestations may be considered in selected cases provided that the results are interpreted by experts on the molecular genetics of ACM.⁴⁵

While in patients with *biventricular* ACM is the concomitant fulfilment of RV diagnostic criteria to guarantee the disease-specificity of the left-sided abnormalities, in patients with *left-dominant* ACM and no clinically detectable RV involvement, demonstration of a pathogenic mutation in ACM-related genes (*major criterion*) is *necessary* for diagnosis, because it is the most specific finding linking the LV phenotypic features to ACM.

DIAGNOSIS OF PHENOTYPIC VARIANTS OF ACM

Figure 3 illustrates the proposed score for diagnosis of phenotypic variants of ACM. A definite diagnosis of “**dominant right**” (“ARVC”) variant is met in patients fulfilling the RV criteria; i.e., 2 major, 1 major and 2 minor, or 4 minor criteria from different categories (≥ 1 criterion, either major or minor, from categories I or II needed), in the absence of LV involvement. The diagnosis of “**biventricular**” variant (i.e., involvement of both ventricles) is met in patients fulfilling the RV criteria for “definite” or “borderline” diagnosis (i.e., 1 major and 1 minor, or 3 minor criteria from different categories; ≥ 1 criterion, either major or minor, from categories I or II needed), who also show morpho-functional and/or structural abnormalities of the LV according to

the present diagnostic criteria. The diagnosis of “**dominant-left**” (“**ALVC**”) variant is met in patients who show structural (with or without morpho-functional) abnormalities of the LV, *plus* demonstration of a ACM-causing gene-mutation, in the absence of morpho-functional and/or structural signs of RV involvement (not fulfilling the RV criteria for either “definite” or “borderline” diagnosis). Figure 3 summarizes the proposed flow-chart for clinical diagnosis of ACM, which is based on the Padua protocol for management of ACM probands and families.

CONCLUSIONS

Over the last decade there has been an increasing awareness that the phenotypic spectrum of ACM was broader than previously expected and included biventricular and left-dominant variants. The lack of specific ITF diagnostic criteria resulted in the under-recognition of patients with the non-classic ARVC phenotype. The Padua criteria represent a working framework to improve the diagnosis of ACM with the aim to fill the gap of previous 1994 and 2010 ITF criteria, by introducing new diagnostic criteria regarding CE-CMR tissue characterization findings, depolarization/repolarization ECG abnormalities and ventricular arrhythmia features for diagnosis of the LV phenotype. The proposed diagnostic criteria need to be validated by further clinical studies in large cohorts of patients. Future research should focus on a better understanding of the genetic background, the identification of diagnostic biomarkers and the evaluation of natural history, risk stratification and management of patients diagnosed with left-sided ACM.

The following are the supplementary data related to this article.

Supplementary online Table 1

Acknowledgements

Supported by the Registry for Cardio-cerebro-vascular Pathology, Veneto Region, Venice, Italy; Target Projects 2016-02363774, Ministry of Health, Rome, Italy; PRIN-20173ZWACS, Ministry of Education, Rome, Italy; and Excellence Project 2017 CARIPARO Foundation, Padova, Italy.

REFERENCES

1. Marcus FI, McKenna WJ, Sherrill D, Basso C, Bauce B, Bluemke DA, Calkins H, Corrado D, Cox MG, Daubert JP, Fontaine G, Gear K, Hauer R, Nava A, Picard MH, Protonotarios N, Saffitz JE, Sanborn DM, Steinberg JS, Tandri H, Thiene G, Towbin JA, Tsatsopoulou A, Wichter T, Zareba W. Diagnosis of arrhythmogenic right ventricular

- cardiomyopathy/dysplasia: proposed modification of the task force criteria. *Circulation* 2010;121(13):1533-41.
2. Corrado D, van Tintelen PJ, McKenna WJ, Hauer RNW, Anastakis A, Asimaki A, Basso C, Baucé B, Brunckhorst C, Bucciarelli-Ducci C, Duru F, Elliott P, Hamilton RM, Haugaa KH, James CA, Judge D, Link MS, Marchlinski FE, Mazzanti A, Mestroni L, Pantazis A, Pelliccia A, Marra MP, Pilichou K, Platonov PGA, Protonotarios A, Rampazzo A, Saffitz JE, Saguner AM, Schmied C, Sharma S, Tandri H, Te Riele ASJM, Thiene G, Tsatsopoulou A, Zareba W, Zorzi A, Wichter T, Marcus FI, Calkins H; International Experts . Arrhythmogenic right ventricular cardiomyopathy: evaluation of the current diagnostic criteria and differential diagnosis. *Eur Heart J*. 2019 Oct 21. pii: ehz669. doi: 10.1093/eurheartj/ehz669. [Epub ahead of print] PubMed PMID: 31637441.
 3. Corrado D, Link MS, Calkins H. Arrhythmogenic Right Ventricular Cardiomyopathy. *N Engl J Med* 2017;376(1):61-72.
 4. Marcus FI, Fontaine GH, Guiraudon G, Frank R, Laurenceau JL, Malergue C, Grosgogeat Y. Right ventricular dysplasia: a report of 24 adult cases. *Circulation*. 1982; 65:384–398
 5. Thiene G, Nava A, Corrado D, Rossi L, Pennelli N. Right ventricular cardiomyopathy and sudden death in young people. *N Engl J Med* 1988;318(3):129-33.
 6. Basso C, Thiene G, Corrado D, Angelini A, Nava A, Valente M. Arrhythmogenic right ventricular cardiomyopathy. Dysplasia, dystrophy, or myocarditis? *Circulation* 1996;94(5):983-91.
 7. Corrado D, Basso C, Thiene G, McKenna WJ, Davies MJ, Fontaliran F, Nava A, Silvestri F, Blomstrom-Lundqvist C, Wlodarska EK, Fontaine G, Camerini F. Spectrum of clinicopathologic manifestations of arrhythmogenic right ventricular cardiomyopathy/dysplasia: a multicenter study. *J Am Coll Cardiol* 1997;30(6):1512-20.
 8. Sen-Chowdhry S, Syrris P, Prasad SK, Hughes SE, Merrifield R, Ward D, Pennell DJ, McKenna WJ. Left-dominant arrhythmogenic cardiomyopathy: an under-recognized clinical entity. *J Am Coll Cardiol*. 2008 Dec 16;52(25):2175-87
 9. Sen-Chowdhry S, Syrris P, Ward D, Asimaki A, Sevdalis E, McKenna WJ. Clinical and genetic characterization of families with arrhythmogenic right ventricular dysplasia/cardiomyopathy provides novel insights into patterns of disease expression. *Circulation* 2007;115(13):1710-20.
 10. Marra MP, Leoni L, Baucé B, Corbetti F, Zorzi A, Migliore F, Silvano M, Rigato I, Tona F, Tarantini G, Cacciavillani L, Basso C, Buja G, Thiene G, Iliceto S, Corrado D. Imaging study of ventricular scar in arrhythmogenic right ventricular cardiomyopathy: comparison

- of 3D standard electroanatomical voltage mapping and contrast-enhanced cardiac magnetic resonance. *Circ Arrhythm Electrophysiol.* 2012 Feb;5(1):91-100.
11. Miles C, Finocchiaro G, Papadakis M, Gray B, Westaby J, Ensam B, Basu J, Parry-Williams G, Papatheodorou E, Paterson C, Malhotra A, Robertus JL, Ware JS, Cook SA, Asimaki A, Witney A, Ster IC, Tome M, Sharma S, Behr ER, Sheppard MN. Sudden Death and Left Ventricular Involvement in Arrhythmogenic Cardiomyopathy. *Circulation.* 2019 Apr 9;139(15):1786-1797
 12. Segura-Rodríguez D, Bermúdez-Jiménez FJ, Carriel V, López-Fernández S, González-Molina M, Oyonarte Ramírez JM, Fernández-Navarro L, García-Roa MD, Cabrerizo EM, Durand-Herrera D, Alaminos M, Campos A, Macías R, Álvarez M, Tercedor L, Jiménez-Jáimez J. Myocardial fibrosis in arrhythmogenic cardiomyopathy: a genotype-phenotype correlation study. *Eur Heart J Cardiovasc Imaging.* 2020 Apr 1;21(4):378-386.
 13. Augusto JB, Eiros R, Nakou E, Moura-Ferreira S, Treibel TA, Captur G, Akhtar MM, Protonotarios A, Gossios TD, Savvatis K, Syrris P, Mohiddin S, Moon JC, Elliott PM, Lopes LR. Dilated cardiomyopathy and arrhythmogenic left ventricular cardiomyopathy: a comprehensive genotype-imaging phenotype study. *Eur Heart J Cardiovasc Imaging.* 2020 Mar 1;21(3):326-336.
 14. Hall CL, Akhtar MM, Sabater-Molina M, Futema M, Asimaki A, Protonotarios A, Dalageorgou C, Pittman AM, Suarez MP, Aguilera B, Molina P, Zorio E, Hernández JP, Pastor F, Gimeno JR, Syrris P, McKenna WJ. Filamin C variants are associated with a distinctive clinical and immunohistochemical arrhythmogenic cardiomyopathy phenotype. *Int J Cardiol.* 2020 May 15;307:101-108
 15. Ortiz-Genga MF, Cuenca S, Dal Ferro M, Zorio E, Salgado-Aranda R, Climent V, Padrón-Barthe L, Duro-Aguado I, Jiménez-Jáimez J, Hidalgo-Olivares VM, García-Campo E, Lanzillo C, Suárez-Mier MP, Yonath H, Marcos-Alonso S, Ochoa JP, Santomé JL, García-Giustiniani D, Rodríguez-Garrido JL, Domínguez F, Merlo M, Palomino J, Peña ML, Trujillo JP, Martín-Vila A, Stolfó D, Molina P, Lara-Pezzi E, Calvo-Iglesias FE, Nof E, Calò L, Barriales-Villa R, Gimeno-Blanes JR, Arad M, García-Pavía P, Monserrat L. Truncating FLNC Mutations Are Associated With High-Risk Dilated and Arrhythmogenic Cardiomyopathies. *J Am Coll Cardiol.* 2016 Dec 6;68(22):2440-2451
 16. Groeneweg JA, van der Zwaag PA, Olde Nordkamp LR, Bikker H, Jongbloed JD, Jongbloed R, Wiesfeld AC, Cox MG, van der Heijden JF, Atsma DE, de Boer K, Doevendans PA, Vink A, van Veen TA, Dooijes D, van den Berg MP, Wilde AA, van Tintelen JP, Hauer RN. Arrhythmogenic right ventricular

- dysplasia/cardiomyopathy according to revised 2010 task force criteria with inclusion of non-desmosomal phospholamban mutation carriers. *Am J Cardiol.* 2013;112:1197-206.
17. Te Rijdt WP, Ten Sande JN, Gorter TM, van der Zwaag PA, van Rijsingen IA, Boekholdt SM, van Tintelen JP, van Haelst PL, Planken RN, de Boer RA, Suurmeijer AJH, van Veldhuisen DJ, Wilde AAM, Willems TP, van Dessel PFHM, van den Berg MP. Myocardial fibrosis as an early feature in phospholamban p.Arg14del mutation carriers: phenotypic insights from cardiovascular magnetic resonance imaging. *Eur Heart J Cardiovasc Imaging* 2019;20:92-100
 18. Cipriani A, Bauce B, De Lazzari M, Rigato I, Bariani R, Meneghin S, Pilichou K, Motta R, Aliberti C, Thiene G, McKenna WJ, Zorzi A, Iliceto S, Basso C, Perazzolo Marra M, Corrado D. Arrhythmogenic Right Ventricular Cardiomyopathy: Characterization of Left Ventricular Phenotype and Differential Diagnosis With Dilated Cardiomyopathy. *J Am Heart Assoc.* 2020 Mar 3;9(5):e014628.
 19. Corrado D, Basso C, Judge DP. Arrhythmogenic Cardiomyopathy. *Circ Res* 2017;121(7):784-802.
 20. Hoorntje ET, Te Rijdt WP, James CA, Pilichou K, Basso C, Judge DP, Bezzina CR, van Tintelen JP. Arrhythmogenic cardiomyopathy: pathology, genetics, and concepts in pathogenesis. *Cardiovasc Res.* 2017 Oct 1;113(12):1521-1531.
 21. Towbin JA, McKenna WJ, Abrams DJ, Ackerman MJ, Calkins H, Darrieux FCC, Daubert JP, de Chillou C, DePasquale EC, Desai MY, Estes NAM 3rd, Hua W, Indik JH, Ingles J, James CA, John RM, Judge DP, Keegan R, Krahn AD, Link MS, Marcus FI, McLeod CJ, Mestroni L, Priori SG, Saffitz JE, Sanatani S, Shimizu W, Peter van Tintelen J, Wilde AAM, Zareba W. 2019 HRS Expert Consensus Statement on Evaluation, Risk Stratification, and Management of Arrhythmogenic Cardiomyopathy. *Heart Rhythm* 2019; 16(11):e373-e407.
 22. McKenna WJ, Thiene G, Nava A, Fontaliran F, Blomstrom-Lundqvist C, Fontaine G, Camerini F. Diagnosis of arrhythmogenic right ventricular dysplasia/cardiomyopathy. Task Force of the Working Group Myocardial and Pericardial Disease of the European Society of Cardiology and of the Scientific Council on Cardiomyopathies of the International Society and Federation of Cardiology. *Br Heart J* 1994;71:215-218
 23. Elliott PM, Anastakis A, Borger MA, Borggrefe M, Cecchi F, Charron P, Hagege AA, Lafont A, Limongelli G, Mahrholdt H, McKenna WJ, Mogensen J, Nihoyannopoulos P, Nistri S, Pieper PG, Pieske B, Rapezzi C, Rutten FH, Tillmanns C, Watkins H. 2014 ESC Guidelines on diagnosis and management of hypertrophic cardiomyopathy: the Task Force

- for the Diagnosis and Management of Hypertrophic Cardiomyopathy of the European Society of Cardiology (ESC). *Eur Heart J*. 2014;35:2733-79
24. De Lazzari M, Zorzi A, Cipriani A, Susana A, Mastella G, Rizzo A, Rigato I, Bauce B, Giorgi B, Lacognata C, Iliceto S, Corrado D, Perazzolo Marra M. Relationship between electrocardiographic findings and cardiac magnetic resonance phenotypes in arrhythmogenic cardiomyopathy. *J Am Heart Assoc* 2018;7:e009855.
 25. Sen-Chowdhry S, Prasad SK, Syrris P, Wage R, Ward D, Merrifield R, Smith GC, Firmin DN, Pennell DJ, McKenna WJ. Cardiovascular magnetic resonance in arrhythmogenic right ventricular cardiomyopathy revisited: comparison with task force criteria and genotype. *J Am Coll Cardiol*. 2006;48:2132-40.
 26. te Riele AS, Tandri H, Bluemke DA. Arrhythmogenic right ventricular cardiomyopathy (ARVC): cardiovascular magnetic resonance update. *J Cardiovasc Magn Reson* 2014;16:50
 27. Petersen SE, Khanji MY, Plein S, Lancellotti P, Bucciarelli-Ducci C. European Association of Cardiovascular Imaging expert consensus paper: a comprehensive review of cardiovascular magnetic resonance normal values of cardiac chamber size and aortic root in adults and recommendations for grading severity. *Eur Heart J Cardiovasc Imaging* 2019;20:1321-1331
 28. Corrado D, Cipriani A, De Lazzari M, Perazzolo Marra M. Right ventricular dilatation in arrhythmogenic right ventricular cardiomyopathy: need for a revision of the 2010 International Task Force criteria. *Eur Heart J* 2020;41:1452-1453
 29. D'Ascenzi F, Anselmi F, Piu P, Fiorentini C, Carbone SF, Volterrani L, Focardi M, Bonifazi M, Mondillo S. Cardiac magnetic resonance normal reference values of biventricular size and function in male athlete's heart. *J Am Coll Cardiol Img* 2019;12:1756-65.
 30. Borgquist R, Haugaa KH, Gilljam T, Bundgaard H, Hansen J, Eschen O, Jensen HK, Holst AG, Edvardsen T, Svendsen JH, Platonov PG. The diagnostic performance of imaging methods in ARVC using the 2010 Task Force criteria. *Eur Heart J Cardiovasc Imaging*. 2014 Nov;15(11):1219-25. doi: 10.1093/ehjci/jeu109. Epub 2014 Jun 17. PMID: 24939949.
 31. Haugaa KH, Basso C, Badano LP, Bucciarelli-Ducci C, Cardim N, Gaemperli O, Galderisi M, Habib G, Knuuti J, Lancellotti P, McKenna W, Neglia D, Popescu BA, Edvardsen T. Comprehensive multi-modality imaging approach in arrhythmogenic cardiomyopathy-an expert consensus document of the European Association of Cardiovascular Imaging. *Eur Heart J Cardiovasc Imaging* 2017;18(3):237-253.

32. Basso C, Ronco F, Marcus F, Abudurehman A, Rizzo S, Frigo AC, Bauce B, Maddalena F, Nava A, Corrado D, Grigoletto F, Thiene G. Quantitative assessment of endomyocardial biopsy in arrhythmogenic right ventricular cardiomyopathy/dysplasia: an in vitro validation of diagnostic criteria. *Eur Heart J* 2008;29(22):2760-71
33. Tandri H, Saranathan M, Rodriguez ER, Martinez C, Bomma C, Nasir K, Rosen B, Lima JA, Calkins H, Bluemke DA: Noninvasive detection of myocardial fibrosis in arrhythmogenic right ventricular cardiomyopathy using delayed-enhancement magnetic resonance imaging. *J Am Coll Cardiol.* 2005, 45: 98-103.
34. Hunold P, Wieneke H, Bruder O, Krueger U, Schlosser T, Erbel R, Barkhausen J: Late enhancement: a new feature in MRI of arrhythmogenic right ventricular cardiomyopathy?. *J Cardiovasc Magn Reson.* 2005, 7: 649-55.
35. Pfluger HB, Phrommintikul A, Mariani JA, Cherayath JG, Taylor AJ: Utility of myocardial fibrosis and fatty infiltration detected by cardiac magnetic resonance imaging in the diagnosis of arrhythmogenic right ventricular dysplasia—a single centre experience. *Heart Lung Circ.* 2008, 17: 478-83.
36. Aquaro GD, Barison A, Todiere G, Grigoratos C, Ait Ali L, Di Bella G, Emdin M, Festa P. Usefulness of Combined Functional Assessment by Cardiac Magnetic Resonance and Tissue Characterization Versus Task Force Criteria for Diagnosis of Arrhythmogenic Right Ventricular Cardiomyopathy. *Am J Cardiol* 2016;118:1730-1736
37. Zorzi A, Rigato I, Pilichou K, Perazzolo Marra M, Migliore F, Mazzotti E, Gregori D, Thiene G, Daliento L, Iliceto S, Rampazzo A, Basso C, Bauce B, Corrado D. Phenotypic expression is a prerequisite for malignant arrhythmic events and sudden cardiac death in arrhythmogenic right ventricular cardiomyopathy. *Europace* 2016;18:1086-94.
38. Zorzi A, Perazzolo Marra M, Rigato I, De Lazzari M, Susana A, Niero A, Pilichou K, Migliore F, Rizzo S, Giorgi B, De Conti G, Sarto P, Serratoso L, Patrizi G, De Maria E, Pelliccia A, Basso C, Schiavon M, Bauce B, Iliceto S, Thiene G, Corrado D. Nonischemic left ventricular scar as a substrate of life-threatening ventricular arrhythmias and sudden cardiac death in competitive athletes. *Circ Arrhythm Electrophysiol* 2016;9(7).
39. Platonov PG, Calkins H, Hauer RN, Corrado D, Svendsen JH, Wichter T, Biernacka EK, Saguner AM, Te Riele AS, Zareba W. High interobserver variability in the assessment of epsilon waves: Implications for diagnosis of arrhythmogenic right ventricular cardiomyopathy/dysplasia. *Heart Rhythm* 2016;13:208-16.
40. Corrado D, Drezner JA, D'Ascenzi F, Zorzi A. How to evaluate premature ventricular beats in the athlete: critical review and proposal of a diagnostic algorithm. *Br J Sports Med.* 2019. pii: bjsports-2018-100529. doi: 10.1136/bjsports-2018-100529. [Epub ahead of

- print] Review. PubMed PMID:31481389.
41. Muser D, Santangeli P, Castro SA, Casado Arroyo R, Maeda S, Benhayon DA, Liuba I, Liang JJ, Sadek MM, Chahal A, Magnani S, Pieroni M, Santarossa E, Desjardins B, Dixit S, Garcia FC, Callans DJ, Frankel DS, Alavi A, Marchlinski FE, Selvanayagam JB, Nucifora G. Risk stratification of patients with apparently idiopathic premature ventricular contractions. A Multicenter International CMR Registry. *JACC: Clinical Electrophysiology* 2019. DOI: 10.1016/j.jacep.2019.10.015
 42. Ackerman MJ, Priori SG, Willems S, Berul C, Brugada R, Calkins H, Camm AJ, Ellinor PT, Gollob M, Hamilton R, Hershberger RE, Judge DP, Le Marec H, McKenna WJ, Schulze-Bahr E, Semsarian C, Towbin JA, Watkins H, Wilde A, Wolpert C, Zipes DP. HRS/EHRA expert consensus statement on the state of genetic testing for the channelopathies and cardiomyopathies: this document was developed as a partnership between the Heart Rhythm Society (HRS) and the European Heart Rhythm Association (EHRA). *Europace* 2011;13:1077-109.
 43. Kapplinger JD, Landstrom AP, Salisbury BA, Callis TE, Pollevick GD, Tester DJ, Cox MG, Bhuiyan Z, Bikker H, Wiesfeld AC, Hauer RN, van Tintelen JP, Jongbloed JD, Calkins H, Judge DP, Wilde AA, Ackerman MJ. Distinguishing arrhythmogenic right ventricular cardiomyopathy/dysplasia-associated mutations from background genetic noise. *J Am Coll Cardiol* 2011;57(23):2317-27.
 44. Andreasen C, Nielsen JB, Refsgaard L, Holst AG, Christensen AH, Andreasen L, Sajadieh A, Haunso S, Svendsen JH, Olesen MS. New population-based exome data are questioning the pathogenicity of previously cardiomyopathy-associated genetic variants. *Eur J Hum Genet* 2013;21(9):918-28.
 45. Richards S, Aziz N, Bale S, Bick D, Das S, Gastier-Foster J, Grody WW, Hegde M, Lyon E, Spector E, Voelkerding K, Rehm HL. Standards and guidelines for the interpretation of sequence variants: a joint consensus recommendation of the American College of Medical Genetics and Genomics and the Association for Molecular Pathology. *Genet Med* 2015; 17(5):405-24

Table 1. “Padua criteria” for diagnosis of Arrhythmogenic Cardiomyopathy

Category	Right ventricle (upgraded 2010 ITF diagnostic criteria)	Left ventricle (new diagnostic criteria)
I. Morpho- functional ventricular abnormalities	<p><i>By echocardiography, CMR or angiography:</i></p> <p>Major</p> <ul style="list-style-type: none"> • Regional RV akinesia, dyskinesia, or bulging <p><i>plus</i> one of the following:</p> <ul style="list-style-type: none"> - global RV dilatation (increase of RV EDV according to the imaging test specific monograms for age and gender) - global RV systolic dysfunction (reduction of RV EF according to the imaging test specific monograms for age, sex, and BSA) <p>Minor</p> <ul style="list-style-type: none"> • Regional RV akinesia, dyskinesia or aneurysm of RV free wall 	<p><i>By echocardiography, CMR or angiography:</i></p> <p>Minor</p> <ul style="list-style-type: none"> • Global LV systolic dysfunction (depression of LV EF according to the imaging test monograms for age and sex, and BSA or reduction of echocardiographic global longitudinal strain), with or without LV dilatation (increase of LV EDV according to the imaging test specific monograms for age, sex, and BSA) <p>Minor</p> <ul style="list-style-type: none"> • Regional LV hypokinesia or akinesia of LV free wall, septum, or both
II. Structural myocardial abnormalities	<p><i>By CE-CMR:</i></p> <p>Major</p> <ul style="list-style-type: none"> • Transmural LGE (stria pattern) of ≥ 1 RV region(s) (inlet, outlet, and apex in 2 orthogonal views) <p><i>By EMB (limited indications):</i></p> <p>Major</p> <ul style="list-style-type: none"> • Fibrous replacement of the myocardium in ≥ 1 sample, with or without fatty tissue 	<p><i>By CE-CMR:</i></p> <p>Major</p> <ul style="list-style-type: none"> • LV LGE (stria pattern) of ≥ 1 Bull’s Eye segment(s) (in 2 orthogonal views) of the free wall (subepicardial or midmyocardial), septum, or both (excluding septal junctional LGE)
III. Repolarization abnormalities	<p>Major</p> <ul style="list-style-type: none"> • Inverted T waves in right precordial leads ($V_1, V_2,$ and V_3) or beyond in individuals with complete pubertal development (in the absence of complete RBBB) 	<p>Minor</p> <ul style="list-style-type: none"> • Inverted T waves in left precordial leads (V_4-V_6) (in the absence of complete LBBB)

Category	Right ventricle (upgraded 2010 ITF diagnostic criteria)	Left ventricle (new diagnostic criteria)
	<p><i>Minor</i></p> <ul style="list-style-type: none"> Inverted T waves in leads V1 and V2 in individuals with completed pubertal development (in the absence of complete RBBB) Inverted T waves in V1, V2, V3 and V4 in individuals with completed pubertal development in the presence of complete RBBB. 	
IV. Depolarization abnormalities	<p><i>Minor</i></p> <ul style="list-style-type: none"> Epsilon wave (reproducible low-amplitude signals between end of QRS complex to onset of the T wave) in the right precordial leads (V1 to V3) Terminal activation duration of QRS ≥ 55 ms measured from the nadir of the S wave to the end of the QRS, including R', in V1, V2, or V3 (in the absence of complete RBBB) 	<p><i>Minor</i></p> <ul style="list-style-type: none"> Low QRS voltages (< 0.5 mV peak to peak) in limb leads (in the absence of obesity, emphysema, or pericardial effusion)
V. Ventricular arrhythmias	<p><i>Major</i></p> <ul style="list-style-type: none"> Frequent ventricular extrasystoles (> 500 per 24 hours), non-sustained or sustained ventricular tachycardia of LBBB morphology <p><i>Minor</i></p> <ul style="list-style-type: none"> Frequent ventricular extrasystoles (> 500 per 24 hours), non-sustained or sustained ventricular tachycardia of LBBB morphology with inferior axis ("RVOT pattern") 	<p><i>Minor</i></p> <ul style="list-style-type: none"> Frequent ventricular extrasystoles (> 500 per 24 hours), non-sustained or sustained ventricular tachycardia with a RBBB morphology (excluding the "fascicular pattern")
VI. Family history/genetics	<p><i>Major</i></p> <ul style="list-style-type: none"> ACM confirmed in a first-degree relative who meets diagnostic criteria ACM confirmed pathologically at autopsy or surgery in a first-degree relative Identification of a pathogenic or likely pathogenic 	

Category	Right ventricle (upgraded 2010 ITF diagnostic criteria)	Left ventricle (new diagnostic criteria)
	<p>ACM mutation in the patient under evaluation</p> <p>Minor</p> <ul style="list-style-type: none"> • History of ACM in a first-degree relative in whom it is not possible or practical to determine whether the family member meets diagnostic criteria • Premature sudden death (<35 years of age) due to suspected ACM in a first-degree relative • ACM confirmed pathologically or by diagnostic criteria in second-degree relative 	

ACM=arrhythmogenic cardiomyopathy; BSA=body surface area; EDV=end diastolic volume; EF=ejection fraction; ITF= International Task Force; LBBB= left bundle-branch block; LGE= late gadolinium enhancement; LV=left ventricle; RBBB= right bundle-branch block; RV=right ventricle; RVOT=right ventricular outflow tract

FIGURE LEGENDS

Figure 1. Electrocardiographic, CE-CMR imaging, and histological features of a representative patient with a predominant-left ACM related to a *DSP* gene defect. Basal ECG showing low voltages in limb leads and flattened T- waves in the inferolateral leads (A). Post- contrast CMR images in long- axis (B) and short- axis (C) views showing normal LV cavity size and subepicardial LGE (white arrows) involving the LV free wall (boxed area) and septum (“ring-like” pattern), from basal to apical regions. Histologic examination of the boxed area showing fibro- fatty myocardial replacement affecting the subepicardial LV layer (Heidenhain trichrome stain) (D); close up detailing residual myocytes embedded within fibrous and fatty tissue (E.E stain) (E). ACM= arrhythmogenic cardiomyopathy; CMR=cardiac magnetic resonance; *DSP*= Desmoplakin gene; LGE=late gadolinium enhancement; LV=left ventricular. *From Cipriani et al.*¹⁸

Figure 2. Diagnosis of phenotypic variants of ACM. Although dominant-right (ARVC) and biventricular disease variants can be diagnosed in those patients fulfilling RV and LV phenotypic criteria, the diagnosis of dominant-left (ALVC), without clinically demonstrable RV abnormalities, needs demonstration of an ACM-causing gene-mutation, in association with a consistent LV phenotype. [§]In family members with a consistent LV phenotype the diagnosis of ALVC may be also made if ACM is confirmed in a first-degree relative either clinically on the base of diagnostic criteria or pathologically at autopsy or surgery.

Figure 3. Proposed flow-chart for clinical diagnosis of ACM. Patients with a suspicion of ACM because of family history, symptoms, ECG abnormalities, ventricular arrhythmias, or imaging features undergo a non-invasive clinical evaluation which includes 12-lead ECG, echocardiography, exercise testing, and 24-hour Holter monitoring. In addition, morpho-functional ventricular abnormalities and structural myocardial tissue alterations are routinely investigated by contrast-

enhanced CMR, which has become the leading imaging modality for diagnosis and characterization of the disease phenotype, with particular reference with the left-sided variants. Transthoracic two-dimensional echocardiography is indicated as part of the initial evaluation of a patient with suspected ACM. The availability of echocardiographic findings at initial evaluation is important in view of the subsequent serial imaging follow-up. Right ventricular angiography is not of additional diagnostic value and is reserved to patients in whom endomyocardial biopsy is planned. Cardiac catheterization is indicated when oxygen saturation measurement is required for differential diagnosis between ACM and congenital heart diseases with a left to right shunt, if the CMR findings are inconclusive. Clinical and molecular genetic screening is performed for identification of the ACM-causing genetic defect and pre-clinical diagnosis among family members. Concurrent with the family genotyping, all relatives should have a comprehensive clinical study including CE-CMR for individual evaluation of the disease phenotype and co-segregation analysis with the identified gene-variant. Based on molecular genetic testing, the disease can be related to ACM-causing mutations of either desmosomal or non-desmosomal genes. Gene elusive, either familial or non-familial disease, require further evaluation to exclude disease mimics, including overlapping phenotype with other genetic heart muscle diseases such as familial dilated cardiomyopathy, congenital phenocopies such as left-to-right shunt or Ebstein anomaly, and acquired phenocopies such as idiopathic dilated cardiomyopathy, cardiac sarcoidosis, myocarditis, pulmonary artery hypertension, or Chagas disease.

Figure 1

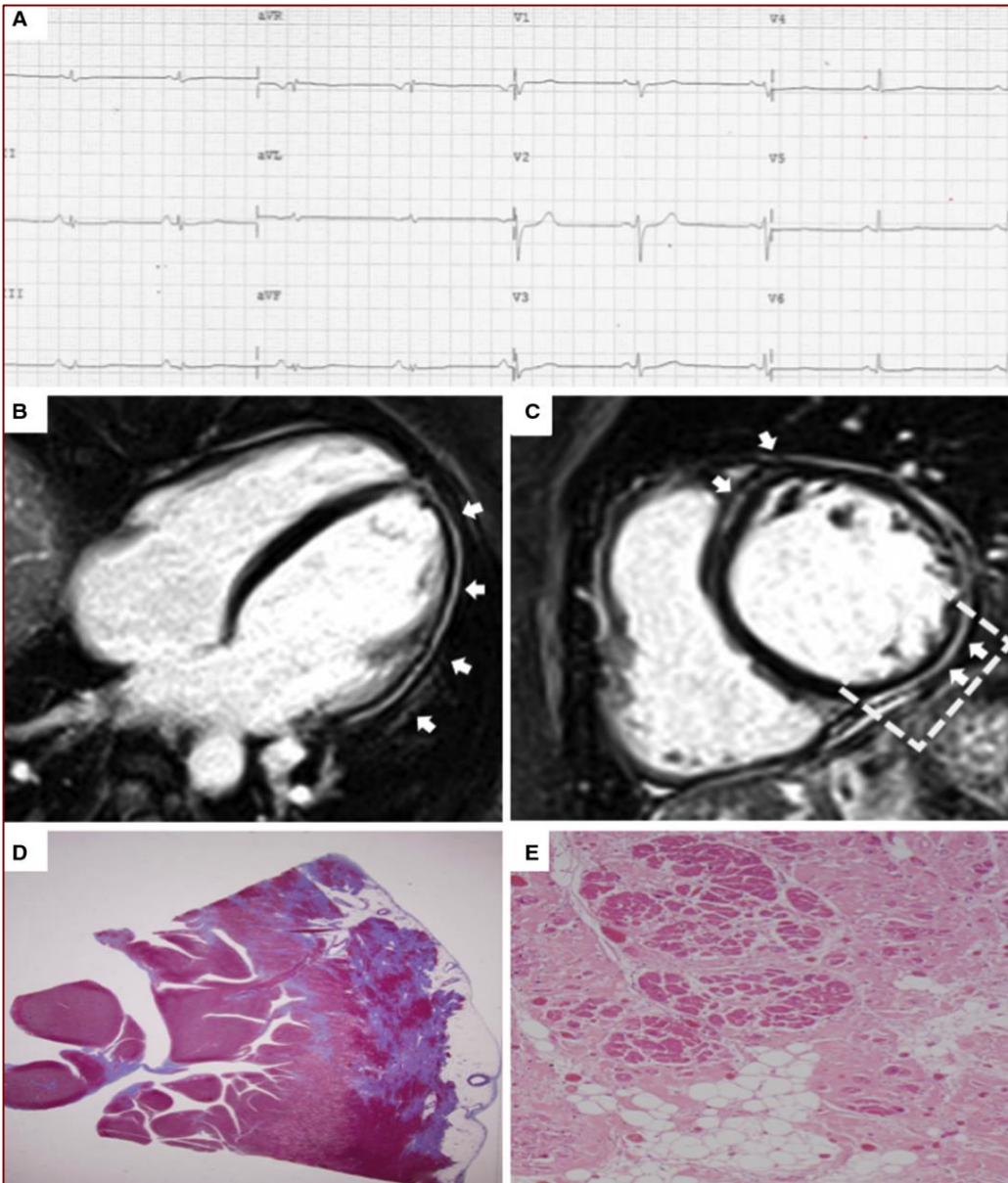


Figure 2

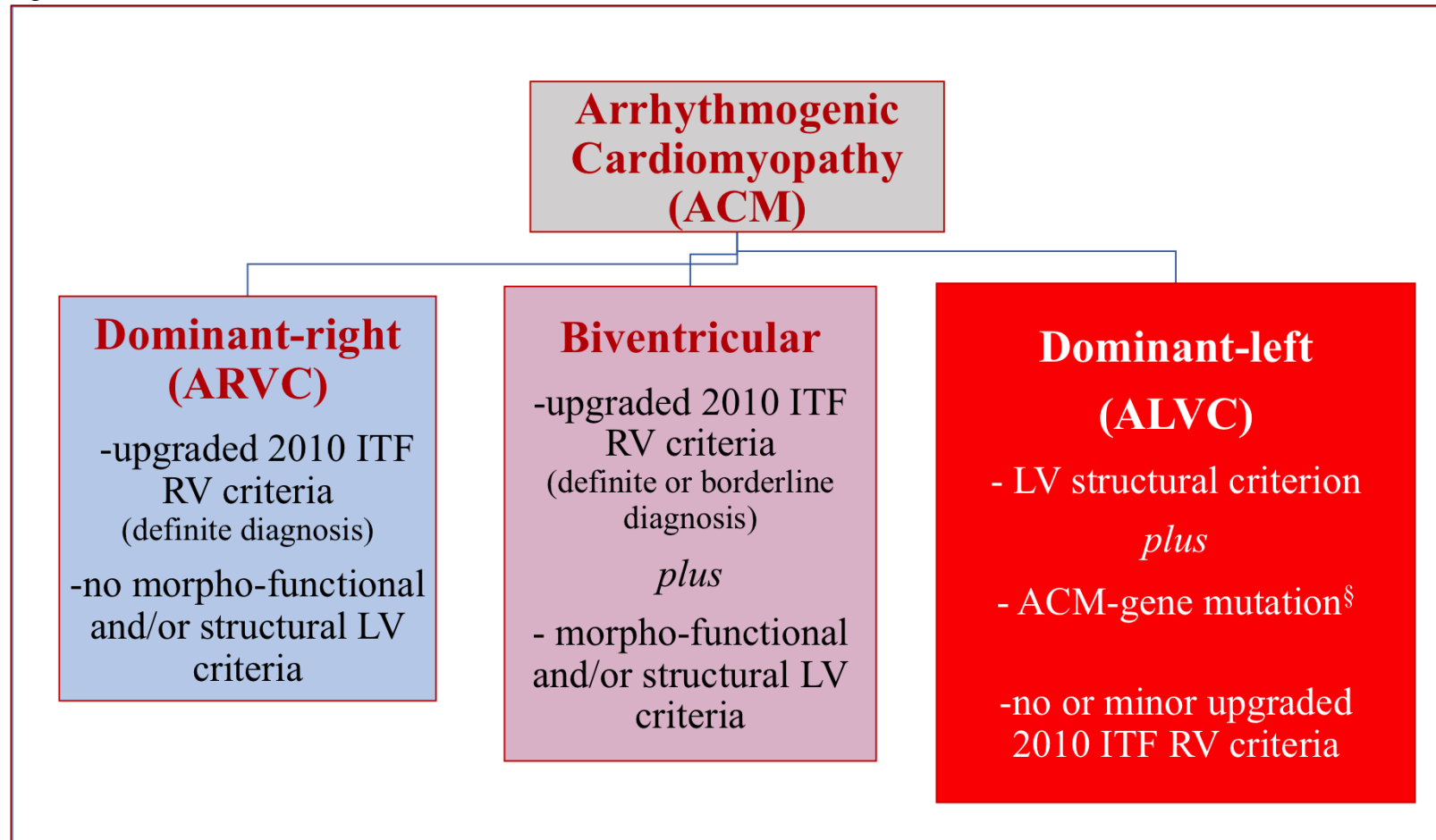
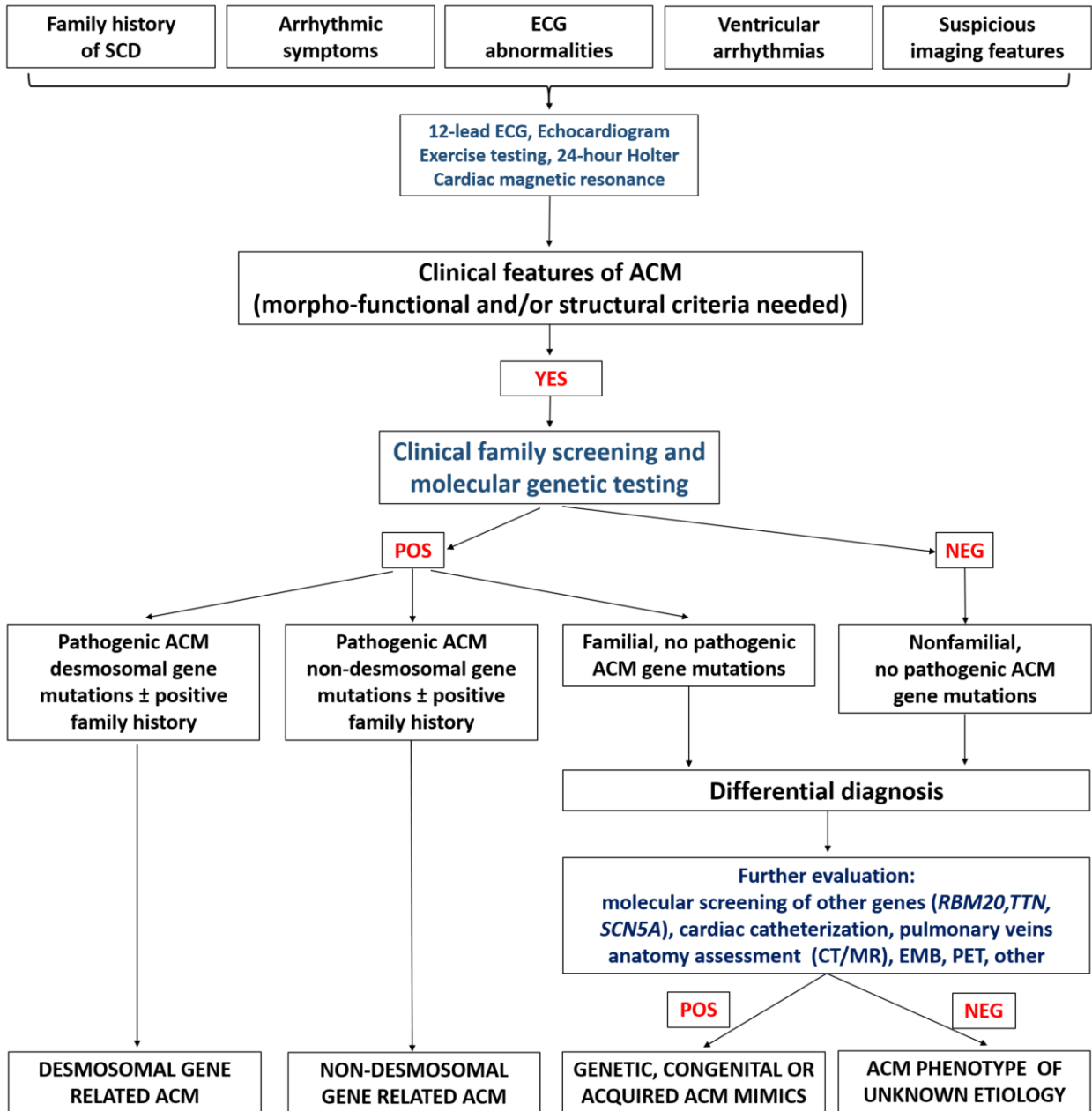


Figure 3



HIGHLIGHTS

- The original designation of “Arrhythmogenic right ventricular dysplasia/cardiomyopathy” was used to describe a heart muscle disease predominantly affecting the right ventricle whose cardinal clinical manifestation was the occurrence of malignant ventricular arrhythmias;
- Subsequent investigations showed that the fibro-fatty replacement of the myocardium represents the distinctive phenotypic feature of the disease and affects not only the right ventricle but also, and sometimes predominantly, the left ventricle;
- The main limitation of the 2010 International Task Force diagnostic criteria was the lack of specific criteria for diagnosis of the broader spectrum of the disease phenotypes which includes left-sided variants;
- The present report represents a proposal for upgrading of the arrhythmogenic cardiomyopathy diagnostic criteria encompassing the entire spectrum of phenotypic variants (dominant-right, biventricular and dominant-left).