

Assessment of acute headache in adults – what the general physician needs to know

Authors: Krishna Chinthapalli,^A Anne-Marie Logan,^B Rohit Raj^C and Niranjana Nirmalanathan^D

ABSTRACT

Headache is common. Up to 5% of attendances to emergency departments and acute medical units are due to headache. Headache is classified as either primary (eg migraine, cluster headache) or secondary to another cause (eg meningitis, subarachnoid haemorrhage). Even in the acute setting the majority of cases are due to primary causes. The role of the attending physician is to take a comprehensive history to diagnose and treat benign headache syndromes while ruling out sinister aetiologies. This brief article summarises the approach to assessment of headache presenting in acute and emergency care.

Introduction

Headache is the commonest neurological symptom. 1–4% of emergency department (ED) attendances are due to headache, although only a small minority of these have a serious cause such as intracranial haemorrhage or meningitis.^{1,2}

Headaches are classified as either primary or secondary.³ Primary headaches, such as migraine, have an independent pathophysiology with no other cause and are usually benign and recurrent. Secondary headaches are a symptom of another disorder. In all settings, including EDs, primary headache disorders are much commoner than secondary disorders.⁴

Assessment of headache in the acute setting

Management of headache in the acute setting should focus on excluding serious secondary causes, making a positive diagnosis, managing symptoms, and establishing a continuing care plan. Clinical assessment is based primarily on the history. A focused clinical examination helps exclude serious pathology. Investigations should be requested only where necessary. Imaging is not a substitute for robust clinical assessment.

Patients often find it difficult to describe their headache beyond its intensity and location. The clinician must 'take the history' and

draw out the relevant features. The focus should be on the onset and evolution of symptoms. For example, patients may report a sudden severe headache, but this is not synonymous with the term 'thunderclap headache'. The most useful initial question is 'How long did the headache take to reach its maximum intensity?' Table 1 lists other suggested questions. When considering associated features, specifically enquire about features of migraine, autonomic dysfunction and raised intracranial pressure. Broadly speaking, thunderclap headache and subacute progressive headache are more likely to be associated with secondary pathology, while recurrent episodic headache and chronic headache (>15 days a month for >3 months) are more likely to be due to a primary cause.

Key points

Diagnosis of headache in the acute setting depends primarily on the clinician taking a thorough history, supported by a focused examination

Primary headaches, especially migraine, are common in the acute setting – it is important to positively diagnose and treat these

Bacterial meningitis almost always presents with one of fever, neck stiffness and altered mental status in addition to headache

A thunderclap headache reaches maximum intensity within 60 seconds. In such cases, a CT scan of the brain and lumbar puncture are necessary to exclude subarachnoid haemorrhage

Medication overuse headache should be considered in anyone taking frequent analgesia for a primary headache disorder. Patients should be given advice on this condition

Fewer than 1 in 1,000 people under 50 years presenting with an isolated headache will have a brain tumour

KEYWORDS: headache, emergency, subarachnoid haemorrhage, meningitis, migraine, cluster headache ■

Authors: ^Aneurology specialty trainee, Atkinson Morley Regional Neurosciences Centre, St George's Hospital, London, UK; ^Bheadache practitioner, Atkinson Morley Regional Neurosciences Centre, St George's Hospital, London, UK; ^Cconsultant in acute medicine, St George's Hospital, London, UK; ^Dconsultant neurologist, St George's Hospital, London, UK

Table 1. Useful questions

Questions	Notes
Have you ever had headaches before?	'Yes' suggests primary headaches more likely, although the patient may have more than one headache type
Before the current episode, how many times a month (or a year) would you get a headache?	Patients with long-standing migraine are often undiagnosed and may discount their typical headaches as 'normal headaches that everyone gets' unless asked explicitly. Also ask about 'menstrual headaches' and 'hungry headaches' as a marker of migraine
Is this your worst ever headache?	'Yes' suggests secondary headaches more likely
How long did the headache take to reach maximum intensity?	Possibly the most useful question. 'Sudden onset' is not sufficiently specific; 'thunderclap' headache should peak within 1 minute (at most 5 minutes); cluster headache develops over up to 30 minutes; migraine develops over hours
What is the duration of headache?	Migraine and many secondary headaches are present from hours to days; headaches lasting minutes or those present for months or years tend to be more benign
When did you last have a 'crystal clear' headache-free day?	A useful question in chronic headache (>15 days/month for >3 months), especially when initially reported to be constant
When do you get the headaches?	Timing of attacks may be helpful – cluster headaches are commoner at night; morning headaches may be seen in obstructive sleep apnoea and raised intracranial pressure (ICP)
Are there any triggers for the headache?	Eg stress, menstruation, diet, caffeine, alcohol, dehydration and other triggers are associated with migraine
Do you have a warning before your headache?	Migraine may be heralded by a prodrome of loss of appetite, lethargy, drowsiness or difficulty concentrating in the hours before the headache ~30% have a true aura, lasting less than 60 minutes and includes more focal neurological symptoms such as visual scotoma or paraesthesia
Where is the headache?	Location is not usually very helpful for diagnosis – most headache disorders may cause headache in any location Strictly unilateral 'side-locked' headaches are characteristic of cluster headache and related disorders (trigeminal autonomic cephalalgias) but can also occur in migraine
Associated features	
Nausea or vomiting	Migraine or raised intracranial pressure (if severe vomiting always consider raised ICP)
Blurred vision or visual loss	Migraine, acute angle-closure glaucoma or raised ICP
Photophobia	Migraine, meningism, uveitis
Phonophobia	
Osmophobia	Migraine
Motion sensitivity / intolerance / aggravation by routine activity	
Restlessness / agitation	Cluster headache (contrast with the motion intolerance of migraine)
Lacrimation	
Rhinorrhoea	Trigeminal autonomic cephalalgias such as cluster headache, if unilateral; may also occur in migraine (bilateral or unilateral)
Conjunctival injection	
Visual obscurations (transient 'graying out' of vision for seconds, particularly on Valsalva manoeuvres)	Raised intracranial pressure
Pulsatile tinnitus	
'Red flag' symptoms	See Table 2 'SNOOP4'

Examination should particularly assess for disturbance of vital signs, meningism, altered consciousness and obvious focal neurological deficit. Take particular care over ocular examination for ophthalmoplegia, ptosis, pupillary abnormalities and

fundoscopy looking for papilloedema which are easily missed and may reflect serious pathology.

We will discuss serious secondary headache disorders which need to be excluded before turning to the primary headaches.

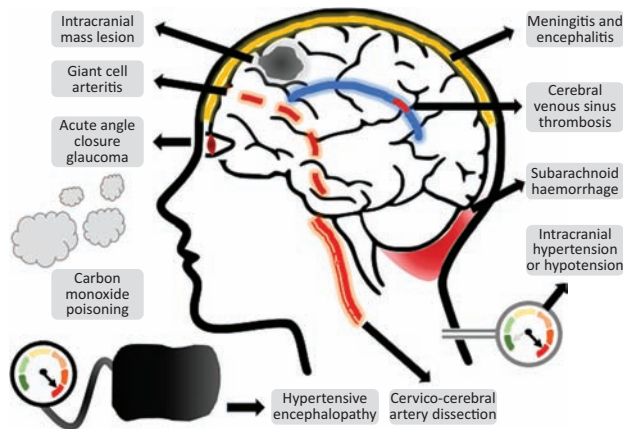


Fig 1. Some of the important secondary causes of acute headache.

Secondary headaches

Many secondary causes of headache are clinically obvious (eg stroke or acute head trauma). Diagnostic difficulty arises primarily where headache is the only symptom, or one of only a few (Fig 1). The SNOOP4 mnemonic may be used to remember 'red flags' for serious secondary headaches (Table 2).⁵ These features and diagnoses should be carefully considered in all patients.

Bacterial meningitis

Acute bacterial meningitis presents with headache in 87% of cases, usually progressive over hours or days, and generalised. The classic triad of neck stiffness, fever and altered mental status is only present in 44% of cases.⁶ However, meningitis is very unlikely (<1%) in a patient with none of the triad.⁶ Be careful to distinguish neck stiffness from neck pain (present in 75% of migraineurs).⁷ Kernig's and Brudzinski's signs are well known but should not be relied upon (sensitivity is as low as 5%). Other features may include nausea, seizures, rash in meningococcal disease, and focal neurologic deficits.

If meningitis is suspected, take immediate blood cultures and give intravenous antibiotics and dexamethasone. As per recent UK guidelines,⁸ a computed tomography (CT) scan should not be performed as it delays lumbar puncture (LP) and treatment, except in suspected raised intracranial pressure with risk of brain shift (Table 3). Serum:CSF glucose ratio <0.36 is the most accurate laboratory predictor of bacterial meningitis.⁹ Management should follow established guidelines.⁸

Thunderclap headache: subarachnoid haemorrhage and other vascular causes

Non-traumatic subarachnoid haemorrhage (SAH) is due to rupture of an intracranial aneurysm in >80% of cases, with a mortality of up to 50%.¹⁰ It only accounts for a small percentage of acute headaches seen in ED but must not be missed. Misdiagnosis quadruples the risk of death after 1 year.¹¹

Table 2. SNOOP4 mnemonic to assess for secondary causes of headache

Systemic symptoms and signs	Possible causes
Fever, rigors, sweats, weight loss	Infection, giant cell arteritis, neoplasia
History of immunosuppression or cancer	
Pregnancy	Secondary vascular cause, especially cerebral venous sinus thrombosis
Family history of intracranial aneurysm	Subarachnoid haemorrhage
Obesity	Idiopathic intracranial hypertension
Neurological symptoms and signs	
Focal neurological deficit	Any secondary cause (migraine aura may also cause focal deficit, but this evolves over minutes and usually resolves within 1 hour)
Meningism	Infection, subarachnoid haemorrhage
Visual obscurations, pulsatile tinnitus	Idiopathic intracranial hypertension, mass lesions
Onset sudden	
Did the pain reach maximum intensity within 60 seconds (thunderclap headache)?	Secondary vascular causes
Onset for the first time over 50 years age	Any secondary cause (especially giant cell arteritis)
Progressive headache (in intensity or duration of episodes)	Consider possibility of neoplasia or medication-overuse headache
Precipitated by Valsalva manoeuvre	Chiari malformation, intracranial structural lesion – especially posterior fossa; intracranial hypotension
Postural relationship	
Worse when standing	Intracranial hypotension
Worse when lying	Raised intracranial pressure
Papilloedema	Raised intracranial pressure

Secondary causes include intracranial infection, inflammation including giant cell arteritis, neoplasia and vascular disease. Vascular disease includes stroke, subarachnoid haemorrhage, venous sinus thrombosis, reversible cerebral vasoconstriction syndrome and arterial dissection. Adapted from Dodick.⁵

Table 3. Indications for neuroimaging before lumbar puncture in suspected bacterial meningitis**Indications for neuroimaging before LP**

Focal neurologic signs
 Presence of papilloedema
 Continuous or uncontrolled seizures
 GCS <12

Inability to view the fundus and GCS<12 are not absolute contraindications. Taken from the UK joint specialist societies' guideline on the diagnosis and management of acute meningitis and meningococcal sepsis in immunocompetent adults.⁸

GCS = Glasgow Coma Scale

The classical presentation is of a 'thunderclap' headache (time to maximal intensity within 60 seconds). A 'worst ever' thunderclap headache, occurring on exertion is found in 70–85% of people with SAH and 3–10% of other new headaches in ED.¹² Only 5% of SAH headaches resolve within 24 hours – the diagnosis is very unlikely when resolution occurs within 1 hour without treatment.¹³ However, resolution of headache with analgesia should not be taken to indicate a benign cause. The Ottawa SAH rule has been proposed to triage patients for investigation (Table 4).¹⁴

Investigation of suspected SAH requires urgent brain CT imaging – sensitivity decreases with time. Non-contrast CT is reported to be >97% sensitive within 6 hours when interpreted by an experienced neuroradiologist. In routine practice, up to 20% of cases may be missed on multi-slice helical CT imaging within 6 hours.¹⁵ Therefore, if the scan is negative, an LP must be performed >12 hours after headache onset for

spectrophotometric assessment of xanthochromia.¹⁶ If LP is normal, then SAH is excluded up to 2 weeks after onset.¹⁷ Following diagnosis, CT or magnetic resonance (MR) angiography (CTA; MRA) is performed. If no aneurysm is found despite the presence of SAH, then catheter angiography remains the gold standard.¹⁶ CTA should not be used for diagnosis as ~3% of the population have an intracranial aneurysm.¹⁸

Only 11–25% of thunderclap headaches are due to SAH. The differential diagnosis includes other vascular headaches. Carotid artery dissection (particularly suggested by preceding neck trauma, or Horner's syndrome) and vertebrobasilar dissection (occipital or neck pain and nausea or vertigo) may present with acute headache,¹⁹ often before the onset of subsequent stroke. Diagnosis is by CT/MR/catheter angiography.

Cerebral venous sinus thrombosis particularly affects women, especially in pregnancy and peripartum. Headache is present in 90%, often as the first symptom, and is often gradual but may be 'thunderclap' in 10%. Features of raised intracranial pressure may occur, as may seizures (40%) and focal neurologic deficits (20%).²⁰ Diagnosis is by CT/MR venography.

Reversible cerebral vasoconstriction syndrome (RCVS) is an increasingly recognised, although poorly understood, disorder. It is usually characterised by recurrent thunderclap headaches associated with reversible constriction of cerebral arteries. There may be an identifiable trigger event. The thunderclap headaches occur several times over weeks, with each episode lasting just minutes to hours, in contrast to SAH.²¹ Strokes and seizures, although unusual, sometimes occur. Initial brain imaging is often normal. Diagnosis is confirmed by angiography and treatment is supportive.

Other causes of thunderclap headache with normal routine imaging include pituitary apoplexy, hypertensive encephalopathy and spontaneous intracranial hypotension.

Other serious secondary headaches

Giant cell arteritis (GCA) should be considered in all adults >50 years of age with new chronic headache, especially if there is systemic malaise. Headache in GCA is only infrequently temporal.²² Scalp tenderness is not specific and occurs in many headaches, including migraine. Jaw and tongue claudication are specific but occur in < 50%. Full blood count (FBC), erythrocyte sedimentation rate (ESR) and C-reactive protein (CRP) should be performed. If suspected, start high dose steroids and arrange confirmatory temporal artery biopsy later.

Up to 6% of ED attendees with headache may have carbon monoxide toxicity.²³ A high index of suspicion is needed. Toxicity causes non-specific headache, dizziness, nausea and confusion. 'Cherry red' skin and lip discoloration are rare.²⁴ Blood gas measurement of carboxyhaemoglobin is confirmatory. Treatment is with 100% high-flow oxygen.²⁴

Acute angle-closure glaucoma may present, particularly in the elderly, primarily as frontal headache with nausea and halo-like visual phenomena. It is thus sometimes misdiagnosed as migraine.²⁵ The pupil may be fixed or irregular with conjunctival injection.²⁵ If suspected, intraocular pressure measurement is diagnostic.

Although headaches occur in >50% of adults with malignant brain tumours,²⁶ they are the sole presenting symptom in just 2%.²⁷ Conversely, 0.08% of adults under 50 years with a new headache will have a tumour, rising to 0.28% over 50 years.²⁶

Table 4. Ottawa subarachnoid haemorrhage rule for investigation of new non-traumatic severe headaches**Inclusion criteria**

Age >15 years
 New severe headache with maximum intensity within 1 hour
 No known brain tumour, intracranial aneurysm or previous SAH
 No previous chronic or recurrent headaches (3 or more similar headaches in last 6+ months)

Criteria for further investigations of headache

Age >40 years

Thunderclap headache

Headache onset during exertion
 Neck pain or stiffness
 Witnessed loss of consciousness
 Limited neck flexion on examination

Patients must fulfil all inclusion criteria before the rule can be applied. Then if any of the criteria for further investigations are positive, a CT scan of the brain is indicated. Applied as stated, sensitivity up to 100%, with specificity 15%. Taken from Perry *et al.*¹⁴

CT = computed tomography; SAH = subarachnoid haemorrhage

Most patients also have seizures, focal neurologic deficits or altered mental status.²⁷ Headache characteristics are variable, but may manifest raised pressure features. Fundoscopy to exclude papilloedema is therefore mandatory in all chronic headache patients. In obese, young women with raised increased intracranial pressure (ICP) headache and papilloedema with normal imaging, consider idiopathic intracranial hypertension (venous sinus thrombosis should first be excluded in this context).

Primary headaches

'Headache' is a symptom, not a diagnosis. Where there is no clinically suspected secondary headache, a primary headache diagnosis should be sought and actively managed. The most prevalent primary headaches are migraine (~15%), tension type headache (~60%) and cluster headache (~0.1%).

Migraine is one of the top 10 causes of disability worldwide²⁸ with 8–14% of sufferers presenting to ED at some time. It is characterised by photophobia, phonophobia, osmophobia and motion intolerance, with moderate to severe throbbing pain and nausea and/or vomiting.³ However, these distinguishing features may diminish when symptoms become chronic, leaving unremitting pain and high disability. Only one-third of patients experience aura.²⁹ In practice, most episodic, recurrent disabling headache is due to migraine.

Migraine is under-reported by patients and under-diagnosed. Effective acute treatment of episodic migraine reduces the risk of progression to chronic migraine.³⁰ Initial management in ED may be with combination therapy of a triptan and high-dose NSAID (eg 900 mg aspirin or 500 mg naproxen).³¹ Dopamine antagonist antiemetics (domperidone or metoclopramide) can be used with analgesia and have an independent action on acute migraine and migraine-associated gastroparesis. Opiates should be avoided. Establish follow-up with primary care or neurology services for consideration of longer-term prophylaxis.³²

By contrast, tension-type headache (TTH) is a featureless bilateral headache which is not disabling acutely. This is rarely the diagnosis in ED patients. When suspected, further elaboration of the history typically reveals the diagnosis to be migraine.

Cluster headache manifests as excruciating, strictly unilateral headache with prominent ipsilateral autonomic dysfunction. Migraine is unilateral in 60% of cases,²⁹ and may also show autonomic disturbance. However, cluster attacks typically last 30 minutes to, at most, 4 hours, while untreated migraine in adults lasts >4 hours and sometimes days. Moreover, patients with cluster headache are typically very restless while migraineurs are motion intolerant. Acute treatment is with sumatriptan 6 mg subcutaneous injections or 100% oxygen delivered through a non-rebreathing face mask. Standard analgesics (including oral triptans) are rarely effective. A tapering course of high-dose prednisolone may be initiated. Verapamil is the first line prophylactic but should be initiated under specialist guidance.³³

Medication overuse headache

Medication overuse headache (MOH) is a common complication of primary headache disorders (prevalence is 1%), leading to chronic headache.³ It is diagnosed when medications such as triptans, opioids and combination analgesics are used on >10 days/month or NSAIDs or paracetamol on >15 days/month. MOH resembles the underlying primary headache type, but is

refractory to preventative medications until analgesic overuse is rectified. The number of days a painkiller is used is more important than the overall dose taken per day.

Following diagnosis of a primary headache disorder in the acute setting establish continuity of care to help prevent re-presentation. Encourage the patient to keep a headache diary including frequency, duration and timing of attacks. Patients with migraine or TTH should be warned explicitly about prevention of MOH. ■

Further reading

UK guidelines on management of headache are available from NICE.³¹ We particularly recommend the detailed guidelines on the management of primary headaches available online from the British Association for the Study of Headache.³²

References

- Goldstein JN, Camargo CA, Pelletier AJ, Edlow JA. Headache in United States emergency departments: demographics, work-up and frequency of pathological diagnoses. *Cephalalgia* 2006;26:684–90.
- Locker TE, Thompson C, Rylance J, Mason SM. The utility of clinical features in patients presenting with nontraumatic headache: an investigation of adult patients attending an emergency department. *Headache* 2006;46:954–61.
- Headache Classification Committee of the International Headache Society (IHS). The International Classification of Headache Disorders, 3rd edition. *Cephalalgia* 2018;38:1–211.
- Cerbo R, Villani V, Bruti G, Di Stani F, Mostardini C. Primary headache in Emergency Department: prevalence, clinical features and therapeutic approach. *J Headache Pain* 2005;6:287–9.
- Dodick D. Pearls: headache. *Semin Neurol* 2010;30:74–81.
- van de Beek D, de Gans J, Spanjaard L *et al.* Clinical Features and prognostic factors in adults with bacterial meningitis. *N Engl J Med* 2004;351:1849–59.
- Calhoun AH, Ford S, Millen C *et al.* The prevalence of neck pain in migraine. *Headache* 2010;50:1273–7.
- McGill F, Heyderman RS, Michael BD *et al.* The UK joint specialist societies guideline on the diagnosis and management of acute meningitis and meningococcal sepsis in immunocompetent adults. *J Infect* 2016;72:405–38.
- Tamune H, Takeya H, Suzuki W *et al.* Cerebrospinal fluid/blood glucose ratio as an indicator for bacterial meningitis. *Am J Emerg Med* 2014;32:263–6.
- Macdonald RL, Schweizer TA. Spontaneous subarachnoid haemorrhage. *Lancet* 2017;389:655–66.
- Kowalski RG, Claassen J, Kreiter KT *et al.* Initial misdiagnosis and outcome after subarachnoid hemorrhage. *JAMA* 2004;291:866–9.
- Mac Grory B, Vu L, Cutting S *et al.* Distinguishing characteristics of headache in nontraumatic subarachnoid hemorrhage. *Headache* 2018;58:364–70.
- Čomić H, Rinkel GJE, Vergouwen MDI. The initial time-course of headache in patients with spontaneous subarachnoid hemorrhage. *J Neurol Sci* 2017;379:55–7.
- Perry JJ, Stiell IG, Sivilotti MLA *et al.* Clinical decision rules to rule out subarachnoid hemorrhage for acute headache. *JAMA* 2013;310:1248–55.
- Mark DG, Hung Y-Y, Offerman SR *et al.* Nontraumatic subarachnoid hemorrhage in the setting of negative cranial computed tomography results: external validation of a clinical and imaging prediction rule. *Ann Emerg Med* 2013;62:1–10.e1.
- Steiner T, Juvela S, Unterberg A *et al.* European Stroke Organization Guidelines for the Management of Intracranial Aneurysms and Subarachnoid Haemorrhage. *Cerebrovasc Dis* 2013;35:93–112.

- 17 Savitz SI, Levitan EB, Wears R, Edlow JA. Pooled analysis of patients with thunderclap headache evaluated by CT and LP: is angiography necessary in patients with negative evaluations? *J Neurol Sci* 2009;276:123–5.
- 18 Vlak MH, Algra A, Brandenburg R, Rinkel GJ. Prevalence of unruptured intracranial aneurysms, with emphasis on sex, age, comorbidity, country, and time period: a systematic review and meta-analysis. *Lancet Neurol* 2011;10:626–36.
- 19 Sheikh HU. Headache in intracranial and cervical artery dissections. *Curr Pain Headache Rep* 2016;20:8.
- 20 Agrawal K, Burger K, Rothrock JF. Cerebral sinus thrombosis. *Headache* 2016;56:1380–9.
- 21 Cappelen-Smith C, Calic Z, Cordato D. Reversible cerebral vasoconstriction syndrome: recognition and treatment. *Curr Treat Options Neurol* 2017;19:21.
- 22 Solomon S, Cappa KG. The headache of temporal arteritis. *J Am Geriatr Soc* 1987;35:163–5.
- 23 Clarke S, Keshishian C, Murray V *et al.* Screening for carbon monoxide exposure in selected patient groups attending rural and urban emergency departments in England: a prospective observational study. *BMJ Open* 2012;2:e000877.
- 24 Hampson NB, Piantadosi CA, Thom SR, Weaver LK. Practice recommendations in the diagnosis, management, and prevention of carbon monoxide poisoning. *Am J Respir Crit Care Med* 2012;186:1095–101.
- 25 Gordon-Bennett P, Ung T, Stephenson C, Hingorani M. Misdiagnosis of angle closure glaucoma. *BMJ* 2006;333:1157–8.
- 26 Kernick D, Stapley S, Goadsby P, Hamilton W. What happens to new-onset headache presented to primary care? A case-cohort study using electronic primary care records. *Cephalalgia* 2008;28:1188–95.
- 27 Schankin CJ, Ferrari U, Reinisch VM *et al.* Characteristics of brain tumour-associated headache. *Cephalalgia* 2007;27:904–11.
- 28 Steiner TJ, Stovner LJ, Birbeck GL. Migraine: the seventh disabler. *Cephalalgia* 2013;33:289–90.
- 29 Dodick DW. Migraine. *Lancet* 2018;391:1315–30.
- 30 Lipton RB, Fanning KM, Serrano D *et al.* Ineffective acute treatment of episodic migraine is associated with new-onset chronic migraine. *Neurology* 2015;84:688–95.
- 31 National Institute for Health and Care Excellence. *Headaches in over 12s: diagnosis and management [CG150]*. London: NICE, 2012.
- 32 McGregor E, Steiner T, Davies P. *Guidelines for all healthcare professionals in the diagnosis and management of migraine, tension-type, cluster and medication-overuse headache, 3rd edn*. British Association for the Study of Headache, 2010.
- 33 Hoffmann J, May A. Diagnosis, pathophysiology, and management of cluster headache. *Lancet Neurol* 2018;17:75–83.

Address for correspondence: Dr Niranjanan Nirmalanathan, St George's University Hospitals NHS Foundation Trust, Department of Neurology, Atkinson Morley Wing, Blackshaw Road, London SW17 0QT, UK. Email: n.nirmalanathan@nhs.net



Federation of the
Royal Colleges of Physicians

Download the new Physicians' CPD app

Record and reflect on the go

- Add and reflect on your educational activities, wherever you are – your changes will sync automatically with your online CPD diary*
- Voice transcribe your development needs and reflections instantly
- Access our list of over 5,000 approved activities
- Keep track of your CPD and monitor your progress to achieving your annual credit requirements

Free for CPD
diary users

'An excellent and user-friendly app. I shall be using my CPD diary more frequently now!'
– Dr Andrew Lansdown, Consultant Endocrinologist

Simply download the Physicians' CPD app on your smartphone or tablet today and log in using your CPD diary account details.
Now available on the iOS App Store and the Google Play Store



<https://cpd.rcplondon.ac.uk>

*Registration to the CPD diary is required to use the Physicians' CPD app.