


Journal Pre-proof

External Compressive Bracing with Initial Reduction of Pectus Carinatum:
Compliance is the Key

Stephanie Fraser, Leanne Harling, Akshay Patel, Tom Richards, Ian Hunt



PII: S0003-4975(19)31411-0

DOI: <https://doi.org/10.1016/j.athoracsur.2019.08.026>

Reference: ATS 33048

To appear in: *The Annals of Thoracic Surgery*

Received Date: 18 September 2018

Revised Date: 1 July 2019

Accepted Date: 8 August 2019

Please cite this article as: Fraser S, Harling L, Patel A, Richards T, Hunt I, External Compressive Bracing with Initial Reduction of Pectus Carinatum: Compliance is the Key, *The Annals of Thoracic Surgery* (2019), doi: <https://doi.org/10.1016/j.athoracsur.2019.08.026>.

This is a PDF file of an article that has undergone enhancements after acceptance, such as the addition of a cover page and metadata, and formatting for readability, but it is not yet the definitive version of record. This version will undergo additional copyediting, typesetting and review before it is published in its final form, but we are providing this version to give early visibility of the article. Please note that, during the production process, errors may be discovered which could affect the content, and all legal disclaimers that apply to the journal pertain.

© 2019 by The Society of Thoracic Surgeons

External Compressive Bracing with Initial Reduction of Pectus Carinatum:

Compliance is the Key

Running Head: External bracing in pectus carinatum

Stephanie Fraser¹, Leanne Harling², Akshay Patel¹, Tom Richards¹, Ian Hunt¹

¹Department of Thoracic Surgery, St George's Hospital NHS Foundation Trust

²Department of Surgery and Cancer, Imperial College London

Corresponding Author:

Mr Ian Hunt

Department of Thoracic Surgery

St George's Hospital NHS Foundation Trust

Blackshaw Rd, London SW17 0QT

Email: ian.hunt@stgeorges.nhs.uk

Word Count: 2585

Abstract

Background: To assess the impact of manipulation and a tailored programme for compressive bracing on the quality of life of patients with flexible pectus carinatum

Methods: 249 sequential patients attending clinic for assessment of pectus carinatum deformities underwent out-patient manipulation and then followed a prescribed schedule of continuous external compressive bracing but without significant progressive tightening.

Results: There was successful sustained reduction of the deformity in 244 patients with high reported rates of concordance (98%) and satisfaction (94%). Patients experienced a reduction in symptoms of anxiety and depression ($p < 0.0001$) and had improved body satisfaction ($p < 0.0001$). Mild skin irritation occurred in 18% of patients ($n=44$) and there were two severe cases of skin irritation, one of which resulted in abandonment of bracing.

Conclusions: Manipulation and non-tightening compressive bracing was associated with complete concordance, high levels of successful bracing, improved confidence and reduced psychological morbidity.

Key Words: 'pectus carinatum'; 'bracing'; 'chest wall'

Pectus Carinatum (PC) is the second most common anterior chest wall deformity presenting to clinicians with an incidence of up to 1 in 1000 adolescent patients [1]. It occurs due to a defect in the growth of costal cartilage between the ribs and the sternum resulting in rotation, elongation and asymmetry. The abnormal costal cartilages protrude outwards creating a peaked deformity commonly known as 'pigeon chest' with varying degrees of severity.

The significant physiological and psychological morbidity associated with the deformity has been extensively described in the literature[2]. Previous studies have demonstrated an improvement in quality of life following minimally invasive surgical repair of PC[3]. However, this link has not yet been proven for compressive bracing for PC.

Traditionally, patient were offered an operation to resect the deformed cartilage and perform a sternal osteostomy to reduce the deformity into a near anatomical position. However, this is associated with a resultant scar and significant potential for surgical morbidity such as pain, infection, bleeding and pneumothoraces[4].

The introduction of external compression of pectus carinatum deformity as an alternative to surgery was initially described as plaster cast treatment[5] and later as dynamic chest compression[6]. Progressive compressive bracing exploits the period of growth and development prior to secondary ossification during which the anterior chest wall is still flexible and avoids any potential risks of surgery in a young patient population. Timing, however, is key as there is a window of opportunity to manipulate the costal cartilages into a more anatomical position while the chest wall is still pliable. Bracing is currently advised as a first-line non-operative treatment for pectus carinatum in guidelines published by the American Paediatric Surgical Association [7]. There are currently no guidelines for bracing in adults in the UK.

There have been few major complications reported with bracing. The main limitation, therefore is the tolerability of the treatment in young patients. The current literature highlights high levels of treatment abandonment and low levels of successful bracing. Banever et al reported that only 50% (15 out of 30 patients) achieved correction of their deformity; similarly Martinez-Ferro reported 54% completion of bracing (112 out of 208 patients with a 15% recurrence rate of those that braced)[8]. De Beer reported an almost 10% drop out rate (27 out of 286 patients with only 78 patients having completed bracing)[9]. Frey et al reported a high number of patients which were not suitable for their programme of bracing (57 out of 100 patients; correction of deformity in only 26 out of 100)[10]. We hypothesise that the reasons for treatment failure often relate either to prolonged bracing protocols (up to two years in some cases[11]) and the slow improvement in the correction of the deformity.

We therefore developed a technique and protocol which involves immediate correction of the deformity within the first patient consultation and application of a custom-fitted non-compressive external brace together with prescribed schedule of brace wear, factors the authors felt contributed to a significantly higher level of compliance previously reported reflected in higher quality of life outcomes.

Patients and Methods

All consecutive patients presenting to the senior author for correction of Pectus Carinatum deformity between 1st January 2015 and 8th February 2018 were assessed retrospectively. Ethical approval was obtained from Spire St Anthony's Hospital. Statistical analysis was performed using STATA 12.0.

Eighty percent of patients were referred by a physician or GP with around 20% of patients self-referring to clinic. All patients with a flexible pectus carinatum deformity were included in

the study, regardless of their age or demographics. Only 6 patients initially presenting to clinic were felt to have deformities which were too stiff and inflexible for either manipulation or bracing. Data collected included the patient's age, height, weight, chest wall measurements, associated features, associated symptoms and medical history. The measurements taken to describe the morphology of the deformity is described elsewhere[12]. All measurements were repeated at each follow up appointment and patients were assessed for any complications of bracing. Information around appropriate wearing of the brace, including a wearing schedule was provided and patients were encouraged to follow the schedule.

Prior to starting and during the bracing programme, a patient satisfaction questionnaire was completed. This was a uniquely created survey for pectus patients which asked patients to report their compliance with bracing, any associated symptoms and the psychological impact of their deformity. Patient's responses were either descriptive or rated on a scale of 1 to 10.

Manipulation of the anterior chest wall and specifically the cartilaginous deformity was performed during the first consultation using a physical therapy technique of 'soft tissue release'. This involved application of topical anaesthetic and heat prior to an infrared massage and around ten minutes of manipulation of the cartilaginous portion of the deformity. Controlled and sustained pressure flattened the deformity. This was maintained carefully and a custom-fitted brace applied directly without additional pressure (further details of the technique are shown in the **supplementary video**). The pressure for initial correction was measured in all patients presenting after April 2018. The measurement was recorded in pounds per square inch (PSI) as the pressure required to correct the deformity both before and after manipulation. The brace was worn continuously without removal for 5 days with the exception of a 'brace' assessment including a skin check on day 2, after which a bracing schedule was prescribed, and oral and written information provided. This varied

based on the flexibility of the pectus deformity and was tailored to each individual patient. The timeline of bracing schedule is shown in **Figure 1**.

Bracing was considered complete any time after 32 weeks if the patient had fully weaned from routine bracing and was satisfied with the cosmetic result. Many patients continued to intermittently brace during subsequent growth spurts after the completion of bracing to maintain the reduction achieved by treatment.

Results

Two hundred and sixty patients included in this analysis were considered eligible for treatment. Of these, six patients were lost of follow up (4 of whom lived abroad) and 5 patients chose not to undergo bracing following their consultation and opted for other or no treatment. Thirty-four patients were assessed as having stiff deformities which were not appropriate for manipulation, but who underwent bracing with traditional progressive tightening. The remaining 215 patients underwent successful reduction of their deformity at their initial consultation without immediate complication. Patients were followed up for a mean of 32.6 weeks (range 8–83) (**Figure 2**). The demographic features of this cohort of patients is shown in **Table 1**.

At the time of this study, 159 patients had completed the bracing protocol and 85 patients continued in the weaning phase of bracing. Many patients were discharged prior to their third and fourth follow up appointments if they had completed the programme with good results.

Compliance with bracing was high with the majority of patients bracing continuously in the first 12 weeks. The average number of hours the brace was worn per day at first follow up

was 22.3 hours. This included patients that were on an early weaning protocol, meaning that concordance with the prescribed number of bracing hours was 98% for the 249 patients.

Of the 159 patients that have completed bracing, the median duration of wear was 32 weeks for active bracing and 40 weeks until the end of the maintenance phase. **Table 2** depicts the distribution of bracing duration. Age was not significantly associated with duration of either active or total bracing duration ($p=0.843$ and 0.440 respectively). Ten patients braced for more than a year, and the average of this cohort (14.6 years) was similar to the whole population group.

There was an immediate and statistically significant reduction in the peak of the deformity of around 3.5cm ($p<0.0001$) which was maintained throughout the study period. The pressure for initial correction also significantly reduced by day 1 following manipulation of the deformity (average 9.6 PSI vs 4.5 PSI). A summary of the change in anterior-posterior (AP) and medial-lateral (ML) differences pre- and post- bracing is shown in **Figure 4**.

Patients described an immediate improvement in the subjective assessment of the appearance of their chest wall (**Figure 5**). A summary of the quantitative self-reported satisfaction scores is shown in **Table 3**. When asked to rate the appearance of their chest before treatment, the median self-reported score was 3/10 (range 1 - 8). At their first follow up appointment, this increased to 8/10 (range 2 - 10), which was consistent throughout their follow up (2nd follow-up: Median 9(4-10); 3rd follow up: Median 9(6-10)). This improvement was statistically significant ($p<0.0001$) at each follow-up when compared to baseline.

Patients also reported high levels of satisfaction with treatment. When asked at first follow up whether the treatment was as good as they had hoped, 94% of respondents ($n=204/217$) scored 5 or more out of 10 with a median score of 8/10.

The questionnaire revealed high levels of psychological morbidity including anxiety and depression in patients with pectus deformities. When asked prior to intervention whether they felt worried, sad or unhappy about their chest, 158/240 respondents (66%) scored 5 or more out of 10 with a median score of 6/10. This significantly reduced following manipulation and bracing (1st follow-up: Median 2(1-10); 2nd follow-up: Median 2(1-10); 3rd follow up: Median 1(1-9)), with only 43/216 patients (20%) reporting high levels of anxiety or depression (5 or more out of 10) at first follow up. This improvement was statistically significant ($p < 0.0001$) at each follow-up when compared to baseline.

Patients did not report a significant change in their overall health despite continuous wear of the external brace. There was a transient increase in the patient's median score for breathlessness of +1 while wearing the brace at the initial follow up which was significant ($p < 0.0001$), however, this resolved during the maintenance phase of bracing. There was no change in the reported level of chest pain ($p = 0.9446$). Despite some patients reporting pain or breathlessness before and during the bracing programme, this did not lead to abandonment of bracing in any patients and was therefore not a negative predictor of compliance.

Complications

There were no immediate complications following manipulation and no mechanical failures regarding the external brace. The only reported complication was skin irritation that occurred in 18% of patients ($n = 46/249$). Forty-four of these cases were considered mild to moderate. Emollient or barrier creams were applied and all of these cases had resolved by the second follow up appointment (around 28 weeks). Of the 2 severe skin complications, one patient developed ring-worm (dermatophytosis/tinea) that required treatment but did not affect his ability to brace. The second case occurred in an older patient who developed skin ulceration which resulted in abandonment of bracing as discussed below.

Abandonment of bracing

Of the 5 patients (2.0%; 5/249) who failed to complete the above protocol for bracing, the average age was 20.2 years, significantly greater than the rest of the cohort (14.9 years).

Two patients chose to stop wearing their brace and two stopped bracing due to significant medical co-morbidities. Only one patient had a significant complication which required them to stop bracing. This was a 26-year-old patient with a stiff deformity who developed skin ulceration five days after manipulation and bracing. Bracing was terminated to allow the skin to heal without subsequent complication.

Long-term follow up

On long term follow up, there were no significant complications, but seven self-reported cases of mild recurrence during the five-year study period. Each patient was advised to undergo a further period of active bracing which fully reduced the recurrence without additional intervention.

Comment

External compressive bracing for flexible pectus carinatum has been demonstrated to be a safe and efficacious first line treatment. It is associated with low levels of morbidity and the main drawback is the need for compliance in a young population group. Many protocols which involve gradual reduction of the deformity and long periods of bracing have resulted in high attrition rates (**Table 4**). We hypothesise that the success of manipulation and external bracing relates to the immediate and complete correction of the deformity which provides motivation to continue bracing as the patient can see an instant difference which is maintained by the brace.

One of the key factors in determining success of bracing relates to patient selection. Our protocol now includes an alternative algorithm for older patients with stiff deformities. This was in response to the case of skin ulceration which highlighted the increased pressure of manipulation in deformities without sufficient flexibility. As a result, these patients are no longer manipulated, but instead undergo progressive tightened. In addition, the program has introduced a pressure gauge to measure the pressure (PSI) required to correct the PC prior to manipulation and helps select patients at greater risk of skin irritation. It is worth noting, however, that compared to previous research, patients with a high pressure of correction were able to successfully brace without complication. We hypothesize that this is in part the result of the manipulation which reduced the PSI within 24 hours of the procedure.

In young patients with supple chest walls, we have adopted a fast-tracked protocol to early weaning following manipulation. These patients have a less intensive and more flexible brace wearing schedule which often suits this young patient population. These patients however, may require longer periods of maintenance bracing and in some instances are advised to brace for a few hours a day during growth spurts.

The high levels of depression and anxiety documented pre-bracing highlight the importance of treatment, counselling and education. It also supports the body of evidence regarding the significant morbidity and reduced quality of life for young patients with pectus deformities.

The marked and consistent improvement in symptoms of psychological distress relating to the patient's deformity highlights the importance of early intervention in this vulnerable patient population. This is consistent with other questionnaire based research which showed a significant improvement in self-esteem in paediatric patients undergoing dynamic bracing [13]. The results also compare favourably with previous research which found that there was a statistically significant deterioration in body confidence and perceived health in the general population between the ages of 11 to 15 years[14]. In our data, there was a positive trend towards a reduction in body dissatisfaction and perceived poor health as the patients aged.

The limitations of this study include the homogenous population group which is consistent with the increased incidence of pectus deformities in young male patients. Additionally, a significant proportion (35%) are still undergoing treatment. This is consistent with other studies of a similar size (**Table 4**) and reflects the length of time for treatment. From our data of patients completing treatment, however, we feel that we can already draw significant conclusions with early evidence of high success rates and high patient tolerability with low attrition rates. Despite this, over the five years of follow up since our first case there have been no reports of significant complication.

Conclusion

Introduction of a manipulation technique to the flexible pectus carinatum as an adjunct to a non-tightening compressive bracing delivered an early and significant improvement to the PC, and together with a prescribed bracing schedule were associated with high patient concordance, high patient satisfaction, reduced psychological morbidity and low levels of complications when compared to other bracing programmes. It is the authors belief that high compliance and completing the prescribed bracing program is the key to a successful and permanent correction of the pectus carinatum deformity.

References

- [1] Coelho Mde S, Guimaraes Pde S. Pectus carinatum. *J Bras Pneumol* 2007;33:463-474.
- [2] Steinmann C, Krille S, Mueller A, Weber P, Reingruber B, Martin A. Pectus excavatum and pectus carinatum patients suffer from lower quality of life and impaired body image: a control group comparison of psychological characteristics prior to surgical correction. *Eur J Cardiothorac Surg* 2011;40:1138-1145.
- [3] Bostanci K, Ozalper MH, Eldem B et al. Quality of life of patients who have undergone the minimally invasive repair of pectus carinatum. *Eur J Cardiothorac Surg* 2013;43:122-126.
- [4] Del Frari B, Sigl S, Schwabegger AH. Complications Related to Pectus Carinatum Correction: Lessons Learned from 15 Years' Experience. Management and Literature Review. *Plast Reconstr Surg* 2016;138:317e-329e.
- [5] Vidal J, Perdriolle R, Brahini B, Connes H, Fischbach C. [Conservative treatment of deformities of the anterior chest wall]. *Rev Chir Orthop Reparatrice Appar Mot* 1977;63:595-608.
- [6] Haje SA, Bowen JR. Preliminary results of orthotic treatment of pectus deformities in children and adolescents. *J Pediatr Orthop* 1992;12:795-800.
- [7] American Pediatric Surgical Association. Pectus Carinatum Guideline. APSA Guideline 2012
https://www.eapsa.org/apsa/media/Documents/Pectus_Carinatum_Guideline_080812.pdf.
- [8] Banever GT, Konefal SH, Gettens K, Moriarty KP. Nonoperative correction of pectus carinatum with orthotic bracing. *J Laparoendosc Adv Surg Tech A* 2006;16:164-167.
- [9] de Beer SA, Gritter M, de Jong JR, van Heurn ELW. The Dynamic Compression Brace for Pectus Carinatum: Intermediate Results in 286 Patients. *Ann Thorac Surg* 2017;103:1742-1749.
- [10] Frey AS, Garcia VF, Brown RL et al. Nonoperative management of pectus carinatum. *J Pediatr Surg* 2006;41:40-45; discussion 40-45.
- [11] Jung J, Chung SH, Cho JK, Park SJ, Choi H, Lee S. Brace compression for treatment of pectus carinatum. *Korean J Thorac Cardiovasc Surg* 2012;45:396-400.
- [12] Harling L, Fraser S, Richards T, Hunt I. Clinical outcomes of non-compressive external bracing for pectus carinatum in a single UK centre. Society for Cardiothoracic Surgery. Glasgow, UK: SCTS, 2018.
- [13] Colozza S, Butter A. Bracing in pediatric patients with pectus carinatum is effective and improves quality of life. *J Pediatr Surg* 2013;48:1055-1059.
- [14] Meland E, Haugland S, Bredablik HJ. Body image and perceived health in adolescence. *Health Educ Res* 2007;22:342-350.
- [15] Poola AS, Pierce AL, Orrick BA et al. A Single-Center Experience with Dynamic Compression Bracing for Children with Pectus Carinatum. *Eur J Pediatr Surg* 2018;28:12-17.
- [16] Lee RT, Moorman S, Schneider M, Sigalet DL. Bracing is an effective therapy for pectus carinatum: interim results. *J Pediatr Surg* 2013;48:184-190.
- [17] Stephenson JT, Du Bois J. Compressive orthotic bracing in the treatment of pectus carinatum: the use of radiographic markers to predict success. *J Pediatr Surg* 2008;43:1776-1780.
- [18] Cohee AS, Lin JR, Frantz FW, Kelly RE, Jr. Staged management of pectus carinatum. *J Pediatr Surg* 2013;48:315-320.

- [19] Martinez-Ferro M, Fraire C, Bernard S. Dynamic compression system for the correction of pectus carinatum. *Semin Pediatr Surg* 2008;17:194-200.
- [20] Emil S, Sevigny M, Montpetit K et al. Success and duration of dynamic bracing for pectus carinatum: A four-year prospective study. *J Pediatr Surg* 2017;52:124-129.
- [21] Kravarusic D, Dicken BJ, Dewar R et al. The Calgary protocol for bracing of pectus carinatum: a preliminary report. *J Pediatr Surg* 2006;41:923-926.
- [22] Lopez M, Patoir A, Varlet F et al. Preliminary study of efficacy of dynamic compression system in the correction of typical pectus carinatum. *Eur J Cardiothorac Surg* 2013;44:e316-319.

Journal Pre-proof

Table 1: Demographic Data

	%	n
Gender (M)	93%	227
Family history	28%	68
	Mean	Range
Age (years)	14.9	8-30
Height (cm)	171.2	130-196
Weight (kg)	56.3	26-100
A/P chest (cm)	21.5	16-33
M/L chest (cm)	24.2	18-31
Pressure to correct (PSI)	9.6	2.4-15.5
Severity	Mild = 10	
	Moderate = 98	
	Severe = 136	

Table 2: Bracing duration by age

Age (years)	≤11	12	13	14	15	16	≥17
Number of patients	6	10	39	44	32	19	9
Active bracing*	31 (30-64)	31 (30-50)	32 (28-42)	32 (28-58)	32 (28-46)	30 (29-44)	40 (34-48)
Total bracing*	37 (34-64)	36 (36-66)	38 (32-60)	38 (28-64)	40 (33-60)	38 (33-58)	50 (42-56)

*Numbers expressed as median (range)

Table 3: Matched pairs Wilcoxon signed rank test of scores at post-operative follow up timepoints

	1st Follow-up (n= 217)	2nd Follow-up (n=161)	3rd Follow-up (n=47)
<i>Anxiety/Depression</i>			
Median difference	-3	-3	-4
p-value	<0.0001	<0.0001	<0.0001
<i>Appearance/Body Confidence</i>			
Median difference	+5	+5	+6
p-value	<0.0001	<0.0001	<0.0001
<i>General Health</i>			
Median difference	-1	0	0
p-value	0.0029	0.7527	0.8075

Table 4: Literature review and comparative attrition/success

Reference	Number of patients *	Patients ongoing bracing at publication	Attrition rate %	Success rate %
Poola et al 2018[15]	340			39% (133/340)
Lee et al 2013[16]	88	10		48% (42/88)
Banever et al 2006[8]	30	**	33% (10/30)	50% (15/30)
Stephenson et al 2008[17]	46	6	9% (4/46)	52% (24/46)
Cohee et al 2013[18]	70	67	7% (5/70)	53% (37/70)
Colozza et al 2013[13]	17	8	18% (3/17)	71% (12/17)
Martinez-Ferro 2008[19]	140	68	20% (28/140)	71% (99/140)
Jung et al 2012[11]	18			72% (13/18)
De Beer 2017[9]	105	181	26% (27/105)	74% (78/105)
Emil et al 2017[20]	81	33	**	79% (64/81)
Kravarusic et al 2006[21]	22	2	14 % (3/22)	86% (19/22)
Frey et al 2006[10]	29		10% (3/29)	90% (26/29)
Hunt et al 2019	175	85	6% (11/175)	91% (159/175)
Lopez et al 2013[22]	35	26		100% (35/35)

*Including patients that completed bracing, failed bracing or abandoned the programme

**Details not provided in publication

Figure Legends

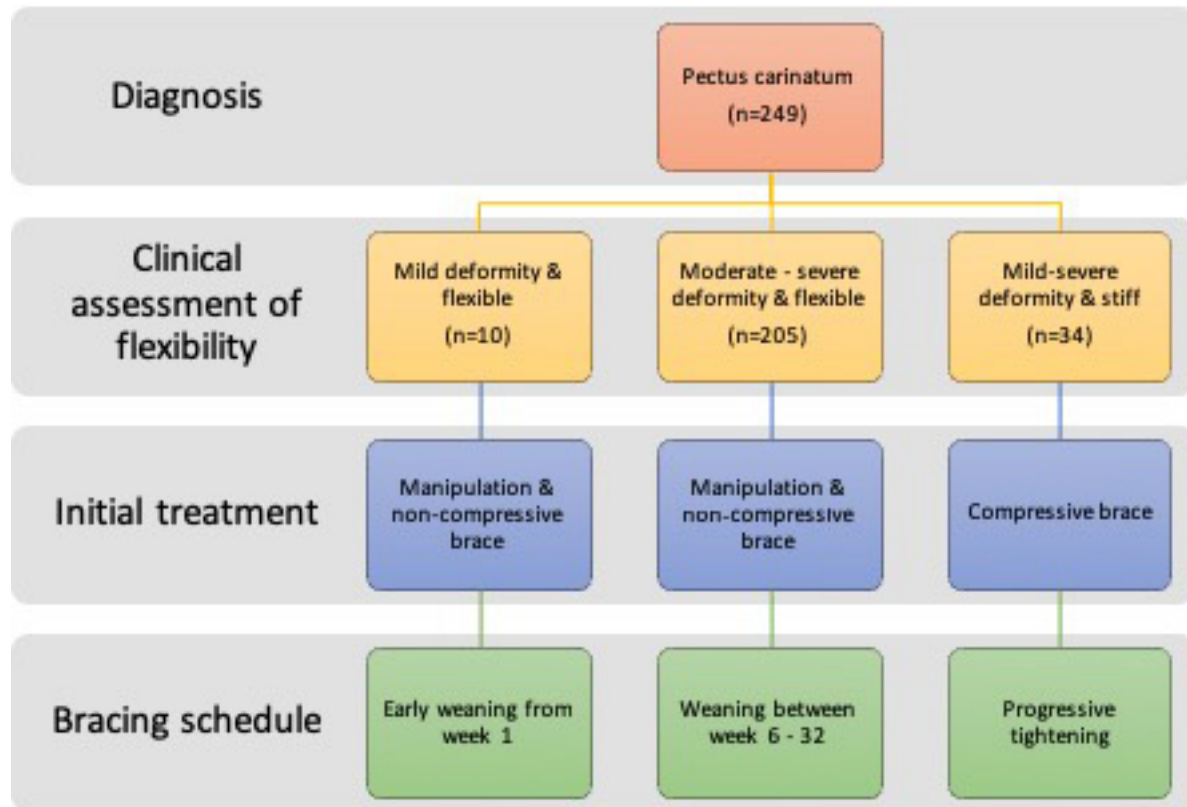
Figure 1: Therapeutic schedule for patients undergoing bracing (n=215).

Figure 2: Flow chart of patient inclusion.

Figure 3: Histogram demonstrating bracing duration for included patients.

Figure 4: Summary of changes in chest wall dimensions pre- and post- bracing.

Figure 5: Example cosmetic result after 6 weeks of bracing.



249 patients presented at first consultation and underwent manipulation with application of custom fitted brace



217 patients attended 1st follow up (mean 11.7 weeks)



161 patients attended 2nd follow up (mean 28.7 weeks)

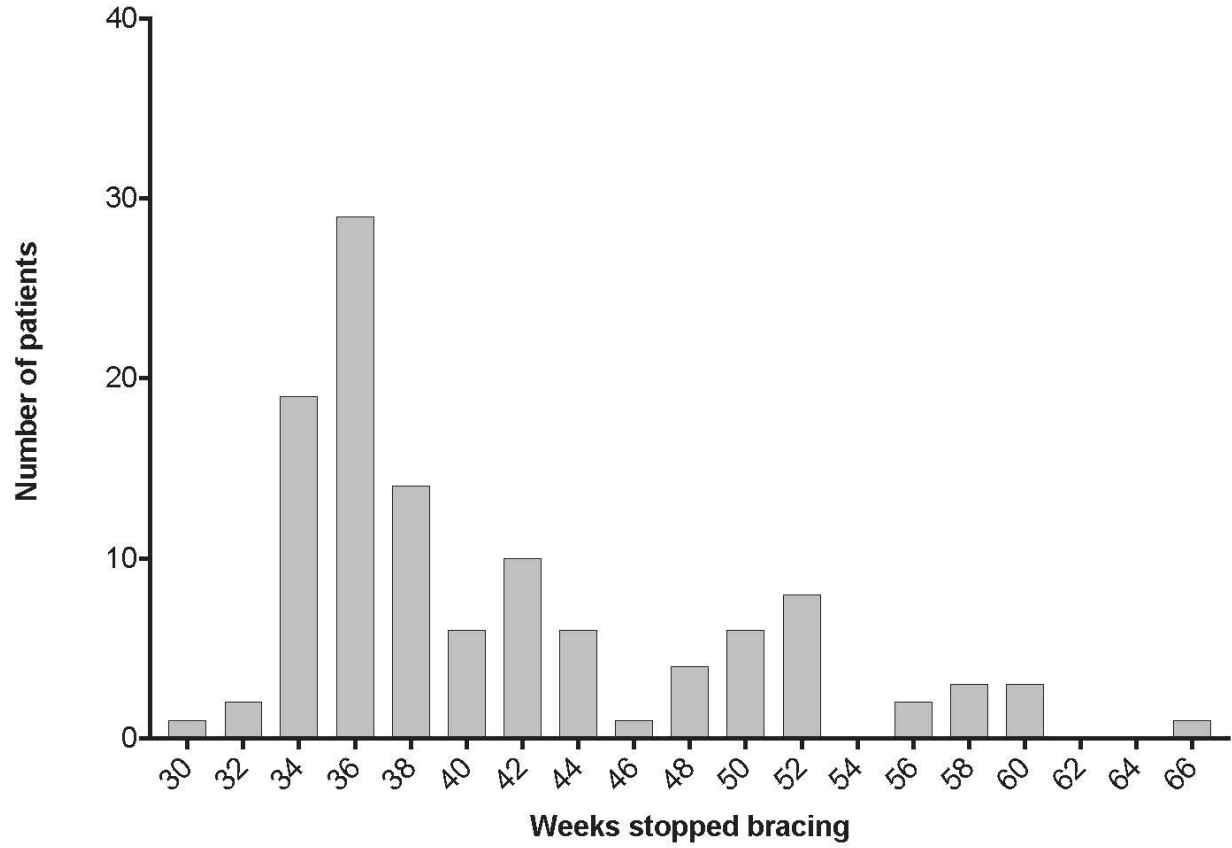


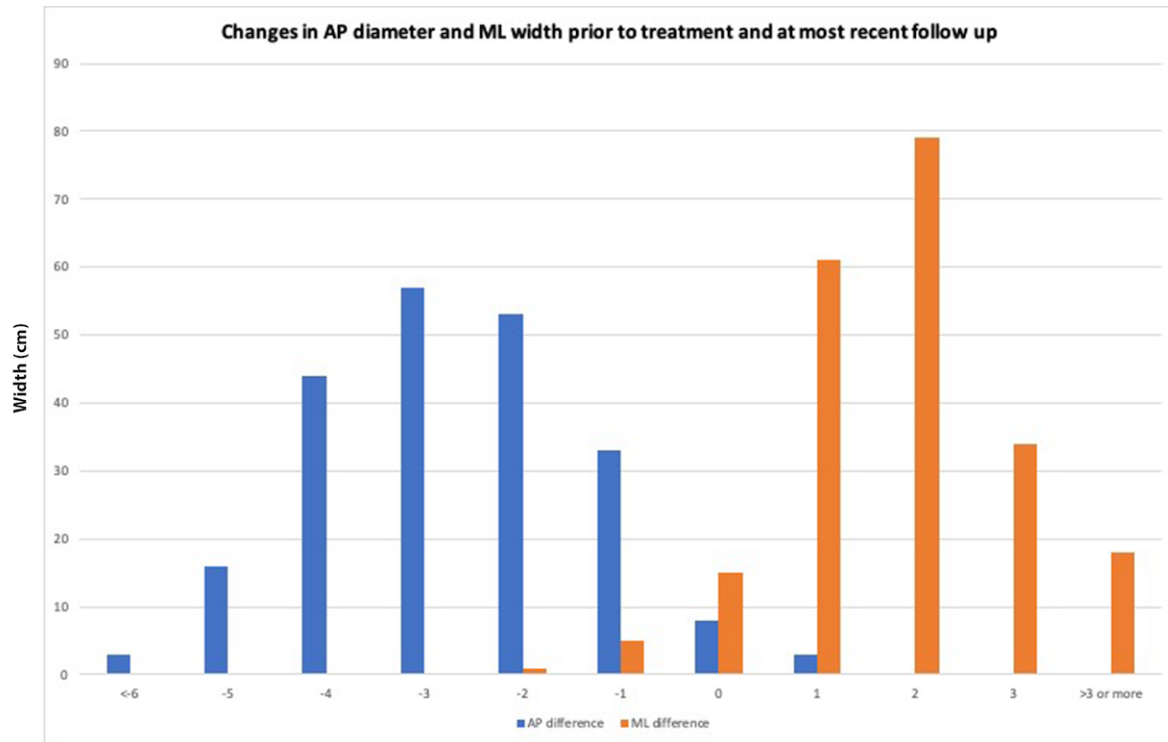
47 patients attended 3rd follow up (mean 41.2 weeks)

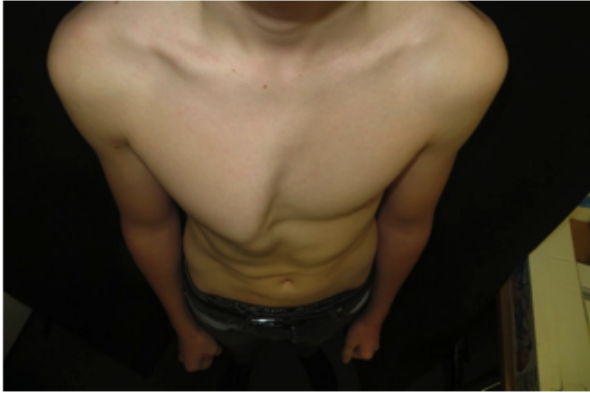

159 patients completed bracing
85 patients ongoing bracing treatment

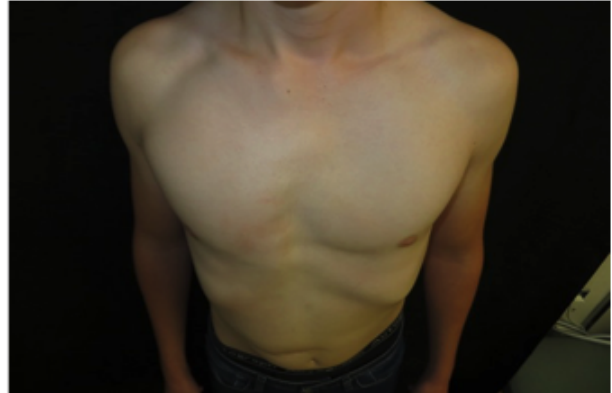Histogram of when Bracing Stopped







Pre-bracing



After 6-weeks of bracing treatment

Journal Pre-proof