


Accepted Manuscript

Fetal dysrhythmias

Julene S. Carvalho, MD PhD, FRCPCH, Professor



PII: S1521-6934(18)30262-1

DOI: <https://doi.org/10.1016/j.bpobgyn.2019.01.002>

Reference: YBEOG 1888

To appear in: *Best Practice & Research Clinical Obstetrics & Gynaecology*

Received Date: 3 December 2018

Revised Date: 31 December 2018

Accepted Date: 7 January 2019

Please cite this article as: Carvalho JS, Fetal dysrhythmias, *Best Practice & Research Clinical Obstetrics & Gynaecology*, <https://doi.org/10.1016/j.bpobgyn.2019.01.002>.

This is a PDF file of an unedited manuscript that has been accepted for publication. As a service to our customers we are providing this early version of the manuscript. The manuscript will undergo copyediting, typesetting, and review of the resulting proof before it is published in its final form. Please note that during the production process errors may be discovered which could affect the content, and all legal disclaimers that apply to the journal pertain.

Fetal dysrhythmias

Professor Julene S Carvalho, MD PhD, FRCPCH^{1 2 3}

Head of Brompton Centre for Fetal Cardiology
Consultant Fetal and Paediatric Cardiologist
Professor of Practice, Fetal Cardiology

¹ Royal Brompton and Harefield NHS Foundation Trust
Sydney Street, London SW3 6NP

² Fetal Medicine Unit, St George's University Hospital
Blackshaw Road, London SW17 0QT

³ Molecular and Clinical Sciences Research Institute
St George's, University of London
Cranmer Terrace, London, SW17 0RE

Correspondence:

Professor JS Carvalho
Royal Brompton Hospital
Sydney Street, London SW3 6NP
Tel.: 00 44 20 7351 8361
Fax: 00 44 20 7351 8544
Email: j.carvalho@rbht.nhs.uk

Abstract

Fetal dysrhythmias are common, usually manifesting as irregular rhythms. Whilst most irregularities are benign and caused by isolated atrial ectopics, in a few cases, rhythm irregularity may indicate partial atrioventricular block, which has different aetiological and prognostic implications. We provide a flowchart for initial management of irregular rhythm, to help select cases requiring urgent specialist referral. Tachycardias and bradycardias are less frequent, can lead to haemodynamic compromise and may require in-utero therapy. Pharmacological treatment of tachycardia depends on type (supraventricular tachycardia or atrial flutter) and presence of hydrops, with digoxin, flecainide and sotalol being commonly used. An ongoing randomized trial may best inform about their efficacy. Bradycardia due to blocked bigeminy normally resolves spontaneously, but if due to established complete heart block there is no effective treatment. Ongoing research suggests hydroxychloroquine may reduce the risk of auto-immune atrioventricular block. Sinus bradycardia (rate < 3rd centile) may be a prenatal marker for long QT syndrome.

Keywords:

Fetus, prenatal diagnosis; atrial ectopic beats; tachycardia; supraventricular, bradycardia; atrioventricular block

Word count: 6867 plus 5 figures

A- Introduction

Fetal dysrhythmias are abnormalities of fetal heart rate (FHR) and/or rhythm (regular or irregular), often detected on antenatal visits or during an ultrasound examination. Once recognized, further evaluation is needed.

Most dysrhythmias present as irregular rhythm ('skipped' or 'missed beats') in structurally normal hearts, have a benign nature and resolve spontaneously. In a small proportion, this requires closer follow up. A risk-stratification protocol helps identifying cases that require specialist assessment. Tachycardias and bradycardias require urgent evaluation and diagnosis can be challenging.

Assessment of fetal dysrhythmias is usually ultrasound-based, to determine fetal well-being, assess cardiac structures and define the nature of rhythm disturbance with confidence to decide if in-utero treatment is needed.

In this review, we aim to provide a logical approach to diagnosis of fetal dysrhythmias and an update on current management.

B- Assessing fetal cardiac rhythm

Treatment of fetal dysrhythmias relies on accurate diagnosis, thus basic understanding of normal rhythm is essential. Contraction and relaxation result from myocardial electrical stimulation, which starts in the natural pacemaker (sinus node). Normal sinus rate varies but is broadly between 120-160bpm. The impulse generated initiates atrial contraction, travels towards the atrioventricular (AV) node and subsequently through specialized tissue in the ventricles (bundle of His, right and left bundles and Purkinje fibers), thus activating ventricular myocardium. A slight physiological delay (AV delay) ensures that ventricular contraction follows atrial contraction leading to a 1:1 AV relationship.

To study cardiac rhythm, simultaneous recording of atrial and ventricular activities is needed. Ultrasound-based techniques are the main tools available prenatally. Other methods are not widely available. A brief appraisal of such techniques is presented below.

M-mode echocardiography is commonly used. It is based on placing a line of ultrasound beam (M-mode line) across cardiac structures to register mechanical results of electrical activation. Typically, M-mode is applied on the four-chamber view to record atrial and ventricular motion (Figure 1). Limitations are image resolution and fetal position. Pulsed wave Doppler (PWD) signal was traditionally used in the left ventricular inflow-outflow tract area (mitral-aortic) [1]. Alternative sites include ascending aorta-superior vena cava [2] and pulmonary artery- vein [3] (Figure 1). Colour and PW tissue Doppler imaging have also been described [4-6], but are not

widely used.

Fetal electrocardiography (f-ECG) and fetal magnetocardiography (f-MCG) allow measurements of cardiac time intervals especially QRS complex and QT interval. Both techniques rely on extracting fetal electrical activity from a combined fetomaternal signal. However, despite being available for many years, neither constitutes part of routine clinical practice. Signal processing has improved but f-ECG signal-to-noise ratio remains a limitation, especially around 27-36 weeks [7]. f-MCG is superior, but requires a shielded environment and has high maintenance costs [8].

C- Rhythm irregularities

Irregular fetal heart rhythms, often described as ‘missed’ or ‘skipped’ beats, constitute a large proportion of referrals due to dysrhythmias [9]. In the majority, the underlying diagnosis is isolated atrial ectopics occurring in structurally normal hearts (Figure 1). Ventricular ectopics and/or associated congenital heart disease (CHD) are less common. Most ectopics resolve spontaneously and may no longer be seen when a scan is performed [9, 10]. However, in a minority, rhythm irregularities may represent a significant dysrhythmia, including conduction abnormalities in ~2.5% [11]. There is a relatively small risk ($\leq 5\%$) of ectopics triggering episodes of tachycardia [12, 13] whilst persistent atrial bigeminy with blocked ectopics can lead to prolonged episodes of bradycardia.

Insert Figure 1

C-1 Management

Most irregular rhythms require no intervention and pregnant women can be reassured. However, risk stratification is important. A flowchart to help this is shown in Figure 2. It and relies on recording FHR and an obstetric scan focused on fetal well-being and cardiac screening views.

Insert Figure 2

If either is abnormal, women can be referred promptly. At specialist level, if isolated ectopics are confirmed and occur occasionally (i.e. rhythm is mostly regular), patient can be discharged. If ectopics are frequent (i.e., rhythm is mostly irregular/‘chaotic’) or occur as couplets/ triplets (two/ three together), ambulatory FHR

surveillance by Doppler at 1-2 week intervals is advisable. Further scans can be performed at local or tertiary level, to monitor for small risk of tachycardia. This possibility should be considered and fetal surveillance intensified, if there is cardiomegaly, AV valve regurgitation, small effusions or unexplained polyhydramnios, even if FHR is normal. Prolonged periods of blocked bigeminy reduces FHR to ~70-80bpm and needs differentiation from 2:1 AV block [14-16] (Figure 3) whereas conducted bigeminy or blocked trigeminy leads to an irregular pattern that can mimic variable 2nd degree AV block (Figure 4) [16]. Monitoring for development of tachycardia in these cases is advisable.

Insert Figures 3 and 4

A neonatal ECG can be performed if irregular rhythm persists after birth. If couplets, triplets and chaotic rhythms are identified prenatally, the risk of tachycardia seems to extend to the neonatal period,[17] thus a neonatal ECG and a 24h-ECG recording is advisable.

D- Tachycardias

Fetal tachycardias are defined as FHR >180bpm but persistent rates ~160-180bpm may also be abnormal. They are potentially life-threatening due to development of ventricular dysfunction and heart failure, although the fetus may tolerate intermittent tachycardia. The diagnosis may be straightforward but tachycardia - even if persistent, may remain undetected, and may only be recognized when the fetus is hydropic. The fetal heart structure is often normal, but CHD may be present.

The most common are supraventricular tachycardia (SVT, ~3/4 of cases) and atrial flutter (AF) [18, 19]. They can also originate from the sinus node, AV junction or ventricles. The diagnosis relies mainly on echocardiography with careful analysis of atrial and ventricular contractions, their rates and temporal relationship. FHR and rate variability may aid, but are not diagnostic.

D.1- Supraventricular tachycardia and atrial flutter

AV reentry tachycardia (AVRT) accounts for 90% of fetal and neonatal forms of SVT [18], which is associated with an accessory pathway between atria and ventricles that creates an extra circuit for the electrical impulse. Atrial ectopics often trigger the tachycardia. Following antegrade conduction through the AV node towards the ventricles, the impulse travels faster and retrogradely from ventricle to atrium through the accessory pathway.

This antegrade-retrograde conduction perpetuates the circuit. AVRT rate is 220–240bpm but can reach ~280bpm. Rate relates to the accessory pathway properties and is relatively fixed with no variability[20]. Typically, AVRT has a short ventriculo-atrial (VA) interval, representing a short VA tachycardia (VA:AV ratio <1) (Figure 5).

Atrial flutter (AF) often occurs later in pregnancy [18]. It results from intra-atrial circuits, often initiated and terminated by premature atrial contractions [8]. Atrial rates are faster (300–500bpm) than ventricular rates due to a physiological block at AV node [12]. Typically, the pattern is 2:1 (atrial rate ~ 440-450bpm; ventricular rate ~220-225bpm), but AV node blockage can vary. At slower atrial rates, 1:1 AV conduction may occur, leading to much faster ventricular rates. AF can also alternate with periods of AVRT in the same fetus [8].

D.2- Other tachycardias

Atrial ectopic tachycardia (AET) and permanent junctional reciprocating tachycardia (PJRT) are less common. AET may have 1:1 or variable AV conduction whereas PJRT shows 1:1 conduction. Typically, these are long VA tachycardias (VA:AV ratio > 1) with FHR usually ~180–220bpm [18, 20]. AET relates to increased atrial automaticity [12]; there may be higher heart rate variability and a warm-up phenomenon. JPRT is mediated by a slow conducting pathway near the coronary sinus, allowing VA conduction [21]. PJRT is usually incessant, may be difficult to treat, and may lead to tachycardia-related cardiomyopathy [12].

Sinus tachycardia is common. If persistent, maternal fever or beta-stimulation, stress, and infection need to be considered as underlying disease. Rates may be mildly elevated (160-180bpm) or as high 200bpm. Heart rate variability is usually preserved [12]. AV conduction is 1:1 and VA interval is long. Treatment is targeted at the cause, if identified. Ventricular tachycardia (VT) is rare. It starts in the ventricles and typically has no retrograde conduction, causing AV dissociation, with ventricular rate (180-300bpm) faster than sinus rate. Long QT syndrome is an important cause of VT, often alternating with bradycardia due to 2:1 AV block. Other associations are cardiac tumors (e.g. rhabdomyomas) and cardiomyopathy. Rarely there is VA conduction, simulating AVRT. Junctional ectopic tachycardia (JET) is one of the rarest fetal tachycardias [22], often incessant, with little FHR variability and not well tolerated despite rates rarely exceeding 200bpm. It results from increased AV node automaticity, which depolarizes the ventricles only, causing AV dissociation and simulating VT. Intermittently however, atrial and ventricular activation may happen almost simultaneously, leading to 1:1 AV relationship with very short VA interval, which helps differentiating from VT [22, 23]. JET has also been

associated with maternal auto-antibodies; in these cases it is intermittent and alternate with AV block [23, 24].

D-3 Management

Fetal tachycardia is an emergency requiring urgent cardiac and obstetric assessment. Depending on mechanism, hemodynamic consequences, fetal well-being and the woman's choice, management options are: no intervention, drug therapy or delivery.

Not all tachycardias require treatment. If intermittent (< 50% of the time) and with no haemodynamic compromise (e.g. no hydrops, no cardiomegaly, no AV valve regurgitation), treatment may be unnecessary. However, close FHR monitoring is needed, to establish frequency and duration of tachycardia. Multiple observations as in-patient over 24-48h may help. Out-patient monitoring may involve checks 1–3 times a week and intermittent scans.

If the tachycardia is incessant (>50% of the time) or haemodynamic compromise is evident, treatment should not be delayed. Choices are pharmacological therapy or delivery, depending mainly on gestational age. If there is significant polyhydramnios, spontaneous labor and delivery may be inevitable.

Risks and benefits of treatment and life-threatening nature of tachycardia should be discussed. In-patient treatment is preferable. Baseline maternal ECG, serum electrolyte levels, liver and renal function should be obtained. If serum levels are available, doses can be adjusted accordingly.

Pharmacological therapy

Digoxin, flecainide, sotalol and amiodarone are relatively safe but side effects including arrhythmogenic ones are reported. Transplacental transfer is preferred but adequate fetal concentration is influenced by presence of hydrops. Digoxin has poor transfer in hydropic fetuses, limiting its use as monotherapy. Direct fetal treatment (cordocentesis, intramuscular, intraperitoneal or intra-amniotic) is an option for severely hydropic or refractory cases, usually combined with oral medication. Digoxin and amiodarone are the preferred drugs. Dose is based on fetal weight, but a 25% increase is recommended to account for placental circulation [25].

Most supraventricular tachyarrhythmias are treated successfully. Survival rates are ~80-90% [18, 19, 26, 27], hydrops being the most important determinant of outcome. Fetal response also relates to tachycardia type and medication used. In the largest retrospective series treated with digoxin, flecainide or sotalol (n= 111, 1998-

2008), SVT was better controlled than AF. Conversion rates were slower for incessant tachycardia and hydrops [18]. Overall mortality was 5% (hydrops= 17%; non-hydrops= 0%). Hydrops was associated with faster ventricular rates, so if rapid conversion cannot be achieved, rate reduction is also important. Compared to sotalol, termination rates for SVT after 5 days were better with flecainide (59%) and digoxin (57%) than sotalol (38%). Similarly, time to convert half of SVT cases was shorter for digoxin (3 days) and flecainide (4 days) than sotalol (12 days). Conversely, in AF cases, sotalol was better, converting 50% of cases in 12 days and achieving sinus rhythm in 29% by day 5, but flecainide had better rate reduction if tachycardia persisted.

These three drugs remain as 1st choice in more recent studies, with variable efficacy reflecting variability in protocols and patient population. Sotalol (\pm digoxin, 2004-2008) had an overall response of 85% among 21 cases of SVT or AF, with 52% conversion and 33% rate control [26]. Many converted in <5 days but hydrops-related mortality was ~38%. In another study, sotalol monotherapy converted 70% and 50% of non-hydrops and hydrops fetuses respectively [28]. Over many years (1987-2012), comparison of two centres showed flecainide to be superior to intravenous digoxin, with clear mortality difference in hydrops cases (flecainide= 0%, digoxin= 47%). Flecainide also converted 96% of short VA SVT compared to digoxin (69%) with shorter median response time (3 versus 8 days) [27]. Two other studies also report good response to flecainide as 1st choice monotherapy, with and without hydrops [29, 30]. In one, high doses (400mg/day) converted 72% of hydrops fetuses with SVT with median time of 3 days [29] whilst in the other, conversion or rate reduction was achieved in 87% using conventional doses [30]. A more aggressive approach using dual therapy (flecainide and digoxin) for all tachyarrhythmias is reported [19]. Of 27 treated fetuses (2001-2009), 81% converted and rate control was achieved in 15%, but perinatal mortality was still ~13%, despite dual therapy.

These reports suggest a trend to use flecainide, in line with a recent systematic review indicating flecainide to be superior in AVRT treatment [31]. However, all studies are retrospective. Depending on multiple variables, it still remains unclear if sotalol and digoxin also have a place as 1st line therapy, in isolation or combined with other medication. Hydrops fetuses remain a high-risk group. Interpretation of drug efficacy in such cases is hindered as treatment failure and mortality is often linked to 'severe hydrops' but systematic information on degree of hydrops is often lacking in successfully treated cases. A randomized controlled trial is ongoing and may provide some answers (www.fasttherapytrial.com). Drug availability also impacts on choice of medication. Digoxin is available worldwide but flecainide and sotalol are not.

Amiodarone is considered as 2nd-line option in drug-refractory tachycardia with hydrops. It was successfully injected to the umbilical vein nearly three decades ago [32] and is still considered safe [25]. Intramuscular fetal

injection of digoxin is also an alternative [33]. Transplacental amiodarone is also used successfully, often combined with digoxin [34, 35].

Standard oral dose for Flecainide is 100mg, 8hourly. It has good placental transfer even in hydrops. Therapeutic trough levels often reach normal range (200-1000µg/L) in 3 days. Maintenance doses are 200–300mg/day (maximum 400–450mg/day). In one study, levels did not correspond to response, medium ~450 µg/L in responders and non-responders [36]. Digoxin, given orally or intravenously, requires a loading dose, but regimes vary. The following is used in the ongoing RCT: loading dose= 2mg (0.5mg 12hourly, or 0.5mg 8hourly in hydrops), followed by maintenance, adjusted according to serum levels taken 12h after 3rd or 4th dose. Levels are aimed at 1.0-2.0 ng/ml, but higher in hydrops (1.5-2.0ng/ml). Digoxin as direct intramuscular fetal injection, was effective at 88µg/ estimated fetal weight, repeated at 12-24h interval, maximal 3 doses [33]. Sotalol has quick placental transfer, reaching good levels even in hydropic fetuses. Side effects are dose related. It prolongs QT interval so maternal ECG should be monitored. Initial recommended dose is 240mg/day, 8 or 12hourly, but higher in hydrops (320mg/day, 12hourly). After a few days, dosage is titrated according to response, maximal of 480mg/day [18]. Amiodarone has poor placental transfer (10–40%), worse in hydrops, but it accumulates in fetal compartments due to long half-life. Loading and maintenance doses vary [20, 34, 35], A suggested regime includes loading with 1200mg/day for 5–7 days (orally or 24-h intravenous infusion) followed by maintenance of 600–800mg/day (200mg 6 or 8hourly) [20]. Recommended doses for direct fetal therapy are 2.5–5mg/kg estimated fetal weight [20].

Information on treatment of VT and JET is limited. Magnesium sulfate (intravenous loading dose of 2–4g, followed by 1–2g/h), lidocaine (intravenous loading dose of 1–1.5mg/kg followed by 1–3mg/min) and oral propranolol (40–80mg 8hourly) have been used for VT. Amiodarone, sotalol, and flecainide may also be effective [17]. If associated with long QT, beta-blockers are preferable and drugs that prolong QT interval (e.g. sotalol) should be avoided. Treatment for fetal JET has included sotalol, digoxin and flecainide [23].

E- Bradycardias

Bradycardia is often associated with fetal distress but its incidental finding requires further assessment. Transient episodes during scanning are common, due to vagal stimulation by cord compression and resolve rapidly with less pressure to maternal abdomen. However, persistent bradycardia, even if intermittent, requires diagnostic workup, so that management is appropriate.

The obstetric definition of bradycardia by the American College of Obstetrics and Gynecology is FHR

<110bpm. However, gestational age-specific nomograms indicate variability [37] with the 3rd centile corresponding to rates of ~135 and 130bpm at 25 and 35 weeks respectively. This helps prediction of familial long QT syndrome [38]. Setting a higher threshold of ~115bpm for irregular rhythms also helps identification of some forms of AV block [16] (Figure 2).

Bradycardia of 70-80bpm has different management implications, depending on the underlying electrophysiological mechanism. Thus, accurate diagnosis is paramount and based on detailed evaluation of regularity pattern of atrial and ventricular contractions and their temporal relationship.

E.1- Bradycardia with 1:1 AV conduction

Persistent bradycardia with 1:1 AV conduction, not associated with fetal distress, is rare. This is almost invariably sinus bradycardia but may occasionally indicate low atrial rhythm, which is characteristic of left atrial isomerism. Sinus bradycardia may be a manifestation of sinus node dysfunction, congenital long QT syndrome, or circulating maternal auto-antibodies. Baseline FHR <3rd percentile is a potential marker for long QT syndrome albeit with low sensitivity [37].

Management

Parental 12-lead ECG, family history and maternal auto-antibody status should be obtained. History of important arrhythmias, sudden death or recurrent fetal loss may indicate an underlying genetic cause. Sinus bradycardia is well tolerated prenatally and does not require treatment. Monitoring fetal well-being at 4-6 weeks is advisable. Perinatal outcome depends on etiology. Neonates need a 12-lead ECG. Further family/genetic tests can be performed depending on history.

A positive family history or evidence of intermittent 2:1 AV block/ VT are strong indicators of fetal long QT syndrome. The QT interval can be measured by f-MCG, if available. The value of steroids to treat autoimmune sinus bradycardia is unknown. In these cases, we have observed progressive decrease in baseline FHR as pregnancy advanced. Low atrial rhythm can be transient or progress to heart block, which in itself carries a guarded outlook, especially if associated with major CHD.

E.2- Bradycardia related to atrial ectopics

When atrial ectopics occur regularly generating bigeminy (one normal beat, one ectopic) or trigeminy (two normal beats, one ectopic), overall ventricular rate may fall. Blocked atrial bigeminy leads to regular

bradycardia, FHR ~70–80bpm. It cannot be distinguished from 2:1AV block based on FHR alone and accounted for nearly half of bradycardia with rates <110bpm[14]. Timing of atrial (A) contractions is essential in the differential diagnosis (Figure 3), which is often straightforward but at times, may simulate 2:1 AV block. Careful measurements are needed and f-MCG can help [15]. When atrial bigeminy is conducted or if there is blocked atrial trigeminy, the rhythm is irregular, FHR ~ 100–115bpm and ought to be distinguished from partial forms of AV block [16] (Figure 4).

Management

Following a positive diagnosis of atrial ectopics causing bradycardia, the pregnant woman can be reassured. Treatment is not required, but FHR monitoring is needed due to small risk of tachycardia (Figure 2). In one study, all cases of blocked bigeminy resolved spontaneously [10] whereas others report tachycardia in 14% of cases [14].

Due to potential risk that emergency Caesarian section is performed unnecessarily, especially if FHR is <100bpm, it is important that the pregnant woman and all professionals looking after her understand its benign nature. Maternal awareness of normal fetal movements is important and other means of assessing fetal well-being need to be in place.

E.3- Heart block

Heart block refers to prolongation or blockage of AV conduction of a normal sinus beat through the AV node. Severity varies, with first degree block (I-AVB) simply reflecting delayed conduction. FHR reflects the pacemaker rate and the AV interval must be measured. In second degree block (II-AVB), AV blockage occurs intermittently. There are two types: in type I (Mobitz I or Wenckebach phenomenon) there is progressive lengthening of the AV interval until a blockage occurs. The rhythm is irregular but FHR is usually normal. In type II (or Mobitz II), some beats are conducted, some are blocked. A 2:1 AV conduction is common, causing regular bradycardia, ventricular rate ~60-80bpm. However, the ratio of AV conduction may vary (e.g. 3:2) with rate and rhythm pattern varying accordingly. Both types of II-AVB need differentiation from atrial ectopics (Figures 3 and 4). In complete or third degree block (III-AVB), there is no AV conduction at all so that atria and ventricles beat independently (Figure 5). Congenital AV block occurs in 1 in 15,000 to 1 in 20,000 live births. Aetiology may be auto-immune, linked to CHD or unknown.

AV block associated with CHD accounts for many cases, most occurring with left isomerism and less with AV

discordance. The prognosis is generally poor [39, 40] with high fetal and neonatal mortality [40]. In one series (n= 59), 60% were liveborns, neonatal mortality approached 80% (left isomerism= 90%; AV discordance= 25% [39].

In isolated non-immune AV block, prognosis seems better. Of 26 congenital cases, 16 had III-AVB. In 10 with partial block, mean progression time to III-AVB was 2.8years. No deaths or cardiomyopathy were observed (mean follow up ~11years) [41]. Regression of non-immune II-AVB has also been reported [39, 42], although some may represent spontaneous resolution of ectopic-related bradycardia [43].

Auto-immune AV block is due to transplacental transfer of maternal auto-antibodies: anti-Ro (SS-A) and/or anti-La (SS-B), that target the fetal ribonucleoproteins 'Ro' and 'La' located in the conduction system, causing inflammation, fibrosis and irreversible damage. The process can also target myocardial cells. AV block typically develops after 16-18 weeks of gestation, peaks at 20–24 and most (82%) occur before 30 weeks [44]. The prognosis is better compared to CHD cases, but fetal demise is still ~6-10% [42, 45]. Presentation <20 weeks, hydrops, impaired function and FHR <50bpm are recognized risk factors. Risk of fetal block in affected women is relatively low (2–3%) [46], but recurrence risk is considerably higher (16–19%) [44] and may be related to antibody levels [47]

Management of auto-immune AV block

Treatment aims to reduce or prevent myocardial and conduction abnormalities, reduce levels of maternal antibodies, or augment FHR. Options include maternal steroids, beta-sympathomimetic agents, intravenous gammaglobulin (IVIG), and plasmapheresis [48, 49]. Established auto-immune III-AVB is irreversible [44].

In-utero pacing has limitations. Dedicated pacing wires developed over a decade ago had limited clinical use and no survivors. Developments in minimally invasive micro-pacemakers [50] and ex-utero intrapartum treatment [51] may have future role. More exciting is the possibility of prevention. Studies suggest that sustained fetal exposure to hydroxychloroquine reduces AV block recurrence to 7.5% [52]. Results of a prospective open label clinical trial (PATCH: Preventive Approach to Congenital Heart Block with Hydroxychloroquine) are awaited.

Fluorinated steroids aim to reduce inflammation. The most used is dexamethasone (4 to 8mg daily, tapered to 2mg towards end of pregnancy) despite its unproven efficacy regarding AV block, cardiomyopathy or survival [53-55]. However, recent small series observations suggest beneficial effect if treatment (dexamethasone and/or IVIG) is started within 24h [56]. As randomized trials are lacking and fetal/ maternal side-effects occur [48], treatment may be considered only in compromised fetuses or recently developed AV block.

Beta-agonists (salbutamol and terbutaline) are used to increase FHR if <50 – 55 bpm. Increase of 5 – 10 bpm with salbutamol (10mg 8hourly; maximal= 40mg/day) or terbutaline (2.5–7.5mg 4–6hourly; maximal= 30mg/day) are reported [48]. Maternal tremor and palpitations are side effects that tend to settle, so doses can be titrated up.

Immunoglobulins and plasmapheresis have also been used. Repeated maternal injections of IVIG aim to reduce the effects of antibodies on the fetal heart. Two prospective multicenter trials used 400mg/Kg at 3-week intervals at 12- 24 weeks, in women with previously affected children, but failed to prevent recurrence [57, 58], which may have been dose-related. Higher doses (1g/Kg, plus steroids) may potentially improve outcome [59]. Plasmapheresis aims to reduce maternal levels of antibodies. A potential effect on II-AVB combined with IVIG and bethamethasone is reported in a small prospective study [60]. Larger controlled trials are needed.

Fetal surveillance of anti-Ro/anti-LA affected pregnancies

Intensive surveillance with weekly AV interval measurements aiming to treat partial block to prevent III-AVB has been suggested. However, the PRIDE study did not support this strategy [46]. Fetuses with I-AVB, treated or untreated, did not progress to III-AVB. Importantly, III-AVB occurred without previous partial block. In another prospective study, I-AVB reverted with dexamethasone, but no controls [61]. Conversely, of 150 fetuses followed up serially, 15 developed partial block, none were treated and AV interval normalized in all but one. [62]. Notably, altered myocardial contractility may also prolong the AV interval [63].

Although current studies do not support weekly monitoring of the AV interval for all pregnancies at risk, targeted surveillance, stratified by antibody levels >100 U/mL seems safe [64] but levels are not usually available. A small case series also suggest treatment benefits if block is recognized within 24h [56] suggesting a potential role for increasing FHR monitoring [65]. Until a consensus is achieved, surveillance (scans and FHR monitoring) from 16 weeks is tailored to individual cases and intensified if there is a previously affected child.

Summary

Irregular rhythms due to atrial ectopics are the most common fetal dysrhythmia and usually resolve spontaneously. However, they can constitute a diagnostic challenge during routine obstetric care. In a few cases, ectopics can trigger tachycardia so risk stratification is important for appropriate fetal monitoring. Conversely, ectopics can cause regular bradycardia (<100 bpm) or irregular rhythms that require differentiation from second degree AV block. Accuracy in diagnosis is important as management implications differ. Less common dysrhythmias such as tachycardias and AV block can be life threatening. Tachycardias need urgent attention. If

sustained, they can lead to fetal hydrops. SVT and AF often respond to transplacental treatment. Flecainide, digoxin and sotalol are commonly used. An RCT to assess efficacy of these drugs is ongoing. Hydrops increases morbidity and mortality for tachycardias and bradycardias. Management of complete AV block may be challenging with few therapeutic options available. The results of an open-label trial of hydroxychloroquine to prevent recurrence of AV block are awaited. Ambulatory fetal heart monitoring may contribute to early detection of AV block.

ACCEPTED MANUSCRIPT

Figure legends

Figure 1: M-mode [A,B] and simultaneous pulsed wave Doppler signal [C,D] across pulmonary artery (PA) and vein (PV). Images [A,C] depict normal sinus rhythm and images [B,D] show a blocked atrial ectopic (B-AE). Note regular interval between atrial signals during sinus rhythm and an early signal (arrow) characteristic of atrial ectopic.

A/ V = atrial/ ventricular systole; LV= left ventricle; RA= right atrium;

Figure 2: Suggested flowchart for initial management of irregular rhythms.

FHR= fetal heart rate, bpm= beats per minute,

Figure 3: Different dysrhythmias causing regular bradycardia with similar rate and arterial Doppler [A,B], depicted on M-mode [C,D] and pulmonary vessels Doppler [E,F]. Images [A,C,E] show blocked atrial bigeminy: note irregular atrial activity, one is conducted but the early ectopic signal is blocked. Images [B,D,F] show 2:1 heart block: note that atrial signal is regular, one is conducted, one is not.

A/ V = atrial/ ventricular systole; (B-AE)= blocked atrial ectopics; FHR= fetal heart rate, bpm= beats per minute

Figure 4: Different dysrhythmias causing irregular bradycardia with similar rate and arterial Doppler [A,B], depicted on M-mode [C,D] and pulmonary vessels Doppler [E,F]. Images [A,C,E] show blocked atrial trigeminy: note irregular atrial activity, two beats are conducted but the early ectopic signal is blocked. Images [B, D, F] show 3:2 heart block: note that atrial activity is regular, two are conducted, one is not.

A/ V = atrial/ ventricular systole; (B-AE)= blocked atrial ectopics; FHR= fetal heart rate, bpm= beats per minute

Figure 5: Examples of supraventricular tachycardia with 1:1 conduction and short VA interval, where the arrows shows flow reversal during atrial contraction [A,D]; atrial flutter with typical 2:1 conduction [B,E] and complete AV block with diagnostic AV dissociation [C,F], depicted on M-mode [A,B,C] and Doppler in pulmonary vessels [D,E,F].

A/ V= atrial/ ventricular contraction

Acknowledgements: None

Conflict of interest: None

Practice Points

What we know

- Fetal dysrhythmias, mainly atrial ectopics, are common, often benign but can cause bradycardia and trigger tachycardia
- Tachycardias require urgent assessment as can lead to haemodynamic compromise, hydrops and death.
- SVT with 1:1 AV conduction and AF are the most common tachycardias. Transplacental treatment is successful in the majority.
- Bradycardia due to ectopic beats are well tolerated
- Bradycardia due to heart block is often associated with maternal auto-antibodies.
- There is no proven effective in-utero treatment for heart block

What we don't know

- Best drug to treat all fetal tachycardias
- Best practice to survey pregnancies affected by anti-Ro/ anti-La antibodies
- How to treat/ manage partial AV block
- How to pace the fetal heart

Research Agenda

- Randomized trial to treat fetal tachycardia (www.fasttherapytrial)
- Risk-stratification of fetuses at risk of long QT syndrome
- Early recognition and treatment of emerging heart block (www.heartsoundsathome)

In-utero pacing for established complete heart block

References

1. Glickstein JS, Buyon J, Friedman D. Pulsed Doppler echocardiographic assessment of the fetal PR interval. *Am J Cardiol* 2000; 86(2): 236-9;
2. Fouron JC, Fournier A, Proulx F, Lamarche J, Bigras JL, Boutin C, et al. Management of fetal tachyarrhythmia based on superior vena cava/aorta Doppler flow recordings. *Heart* 2003; 89(10): 1211-6;
3. *** Carvalho JS, Prefumo F, Ciardelli V, Sairam S, Bhide A, Shinebourne EA. Evaluation of fetal arrhythmias from simultaneous pulsed wave Doppler in pulmonary artery and vein. *Heart* 2007; 93(11): 1448-53; 10.1136/hrt.2006.101659
4. Rein AJ, O'Donnell C, Geva T, Nir A, Perles Z, Hashimoto I, et al. Use of tissue velocity imaging in the diagnosis of fetal cardiac arrhythmias. *Circulation* 2002; 106(14): 1827-33;
5. Nii M, Hamilton RM, Fenwick L, Kingdom JC, Roman KS, Jaeggi ET. Assessment of fetal atrioventricular time intervals by tissue Doppler and pulse Doppler echocardiography: normal values and correlation with fetal electrocardiography. *Heart* 2006; 92(12): 1831-7;
6. Tutschek B, Schmidt KG. Pulsed-wave tissue Doppler echocardiography for the analysis of fetal cardiac arrhythmias. *Ultrasound Obstet Gynecol* 2011; 38(4): 406-12; 10.1002/uog.9070
7. Wacker-Gussmann A, Plankl C, Sewald M, Schneider KM, Oberhoffer R, Lobmaier SM. Fetal cardiac time intervals in healthy pregnancies - an observational study by fetal ECG (Monica Healthcare System). *J Perinat Med* 2017; 46 (6): 587-92; 10.1515/jpm-2017-0003
8. Wacker-Gussmann A, Strasburger JF, Srinivasan S, Cuneo BF, Lutter W, Wakai RT. Fetal Atrial Flutter: Electrophysiology and Associations With Rhythms Involving an Accessory Pathway. *J Am Heart Assoc* 2016; 5(6); 10.1161/JAHA.116.003673

9. Rasiah SV, Ewer AK, Miller P, Kilby MD. Prenatal diagnosis, management and outcome of fetal dysrhythmia: a tertiary fetal medicine centre experience over an eight-year period. *Fetal Diagn Ther* 2011; 30(2): 122-7; 10.1159/000325464
10. Fouron JC. Fetal arrhythmias: the Saint-Justine hospital experience. *Prenatal Diagnosis* 2004; 24(13): 1068-80;
11. Cuneo BF, Strasburger JF, Wakai RT, Ovadia M. Conduction system disease in fetuses evaluated for irregular cardiac rhythm. *Fetal Diagn Ther* 2006; 21(3): 307-13;
12. *** Srinivasan S, Strasburger J. Overview of fetal arrhythmias. *Curr Opin Pediatr* 2008; 20(5): 522-31;
13. Simpson JL, Yates RW, Sharland GK. Irregular heart rate in the fetus: not always benign. *Cardiol Young* 1996; 6: 28-31;
14. *** Eliasson H, Wahren-Herlenius M, Sonesson SE. Mechanisms in fetal bradyarrhythmia: 65 cases in a single center analyzed by Doppler flow echocardiographic techniques. *Ultrasound Obstet Gynecol* 2011; 37(2): 172-8; 10.1002/uog.8866
15. Wiggins DL, Strasburger JF, Gotteiner NL, Cuneo B, Wakai RT. Magnetophysiologic and echocardiographic comparison of blocked atrial bigeminy and 2:1 atrioventricular block in the fetus. *Heart Rhythm* 2013; 10(8): 1192-8; 10.1016/j.hrthm.2013.04.020
- 16.*** Carvalho JS. Primary bradycardia: keys and pitfalls in diagnosis. *Ultrasound Obstet Gynecol* 2014; 44(2): 125-30; 10.1002/uog.13451
17. Strasburger JF, Wakai RT. Fetal cardiac arrhythmia detection and in utero therapy. *Nat Rev Cardiol* 2010; 7(5): 277-90;

18. *** Jaeggi ET, Carvalho JS, De Groot E, Api O, Clur SA, Rammeloo L, et al. Comparison of transplacental treatment of fetal supraventricular tachyarrhythmias with digoxin, flecainide, and sotalol: results of a nonrandomized multicenter study. *Circulation* 2011; 124(16): 1747-54; 10.1161/CIRCULATIONAHA.111.026120
19. Uzun O, Babaoglu K, Sinha A, Massias S, Beattie B. Rapid control of foetal supraventricular tachycardia with digoxin and flecainide combination treatment. *Cardiol Young* 2012; 22(4): 372-80; 10.1017/S1047951111001272
20. Gembruch U. Fetal Tachyarrhythmia. In: Yagel S, Silverman NH, Gembruch U, editors. *Fetal Cardiology. Maternal-Fetal Medicine*. 2nd. New York: Informa Healthcare; 2009. p. 461-81.
21. Oudijk MA, Stoutenbeek P, Sreeram N, Visser GH, Meijboom EJ. Persistent junctional reciprocating tachycardia in the fetus. *J Matern Fetal Neonatal Med* 2003; 13(3): 191-6;
22. Villazon E, Fouron JC, Fournier A, Proulx F. Prenatal diagnosis of junctional ectopic tachycardia. *Pediatr Cardiol* 2001; 22(2): 160-2;
23. Zaidi SJ, Siddiqui S, Cuneo BF, Strasburger JF, McDuffie R, Wakai RT. Prenatal diagnosis and management of junctional ectopic tachycardia. *Heart Rhythm Case Rep* 2017; 3(11): 503-8; 10.1016/j.hrcr.2017.07.022
24. Dubin AM, Cuneo BF, Strasburger JF, Wakai RT, Van Hare GF, Rosenthal DN. Congenital junctional ectopic tachycardia and congenital complete atrioventricular block: a shared etiology? *Heart Rhythm* 2005; 2(3): 313-5; 10.1016/j.hrthm.2004.11.016
25. Kang SL, Howe D, Coleman M, Roman K, Gnanapragasam J. Foetal supraventricular tachycardia with hydrops fetalis: a role for direct intraperitoneal amiodarone. *Cardiol Young* 2015; 25(3): 447-53; 10.1017/S104795111400002X

26. Shah A, Moon-Grady A, Bhogal N, Collins KK, Tacy T, Brook M, et al. Effectiveness of sotalol as first-line therapy for fetal supraventricular tachyarrhythmias. *Am J Cardiol* 2012; 109(11): 1614-8; 10.1016/j.amjcard.2012.01.388
27. *** Sridharan S, Sullivan I, Tomek V, Wolfenden J, Skovranek J, Yates R, et al. Flecainide versus digoxin for fetal supraventricular tachycardia: Comparison of two drug treatment protocols. *Heart Rhythm* 2016; 13(9): 1913-9; 10.1016/j.hrthm.2016.03.023
28. Ekman-Joelsson BM, Mellander M, Lagnefeldt L, Sonesson SE. Foetal tachyarrhythmia treatment remains challenging even if the vast majority of cases have a favourable outcome. *Acta Paediatr* 2015; 104(11): 1090-7; 10.1111/apa.13111
29. Strizek B, Berg C, Gottschalk I, Herberg U, Geipel A, Gembruch U. High-dose flecainide is the most effective treatment of fetal supraventricular tachycardia. *Heart Rhythm* 2016; 13(6): 1283-8; 10.1016/j.hrthm.2016.01.029
30. Ekiz A, Kaya B, Bornaun H, Acar DK, Avci ME, Bestel A, et al. Flecainide as first-line treatment for fetal supraventricular tachycardia. *J Matern Fetal Neonatal Med* 2018; 31(4): 407-12; 10.1080/14767058.2017.1286317
31. Hill GD, Kovach JR, Saudek DE, Singh AK, Wehrheim K, Frommelt MA. Transplacental treatment of fetal tachycardia: A systematic review and meta-analysis. *Prenat Diagn* 2017; 37(11): 1076-83; 10.1002/pd.5144
32. Gembruch U, Manz M, Bald R, Ruddel H, Redel DA, Schlebusch H, et al. Repeated intravascular treatment with amiodarone in a fetus with refractory supraventricular tachycardia and hydrops fetalis. *Am Heart J* 1989; 118(6): 1335-8;
33. Parilla BV, Strasburger JF, Socol ML. Fetal supraventricular tachycardia complicated by hydrops fetalis: a role for direct fetal intramuscular therapy. *Am J Perinatol* 1996; 13(8): 483-6; 10.1055/s-2007-994432

34. Strasburger JF, Cuneo BF, Michon MM, Gotteiner NL, Deal BJ, McGregor SN, et al. Amiodarone therapy for drug-refractory fetal tachycardia. *Circulation* 2004; 109(3): 375-9;
35. Jouannic JM, Delahaye S, Fermont L, Le Bidois J, Villain E, Dumez Y, et al. Fetal supraventricular tachycardia: a role for amiodarone as second-line therapy? *Prenatal Diagnosis* 2003; 23(2): 152-6;
36. Vigneswaran TV, Callaghan N, Andrews RE, Miller O, Rosenthal E, Sharland GK, et al. Correlation of maternal flecainide concentrations and therapeutic effect in fetal supraventricular tachycardia. *Heart Rhythm* 2014; 11(11): 2047-53; 10.1016/j.hrthm.2014.07.031
37. Cuneo BF, Strasburger JF. We only find what we look for: fetal heart rate and the diagnosis of long-QT syndrome. *Circ Arrhythm Electrophysiol* 2015; 8(4): 760-2; 10.1161/CIRCEP.115.003196
38. *** Mitchell JL, Cuneo BF, Etheridge SP, Horigome H, Weng HY, Benson DW. Fetal heart rate predictors of long QT syndrome. *Circulation* 2012; 126(23): 2688-95; 10.1161/CIRCULATIONAHA.112.114132
39. Lopes LM, Tavares GM, Damiano AP, Lopes MA, Aiello VD, Schultz R, et al. Perinatal outcome of fetal atrioventricular block: one-hundred-sixteen cases from a single institution. *Circulation* 2008; 118(12): 1268-75;
40. Glatz AC, Gaynor JW, Rhodes LA, Rychik J, Tanel RE, Vetter VL, et al. Outcome of high-risk neonates with congenital complete heart block paced in the first 24 hours after birth. *JThoracCardiovascSurg* 2008; 136(3): 767-73;
41. Baruteau AE, Fouchard S, Behaghel A, Mabo P, Villain E, Thambo JB, et al. Characteristics and long-term outcome of non-immune isolated atrioventricular block diagnosed in utero or early childhood: a multicentre study. *Eur Heart J* 2012; 33(5): 622-9; 10.1093/eurheartj/ehr347

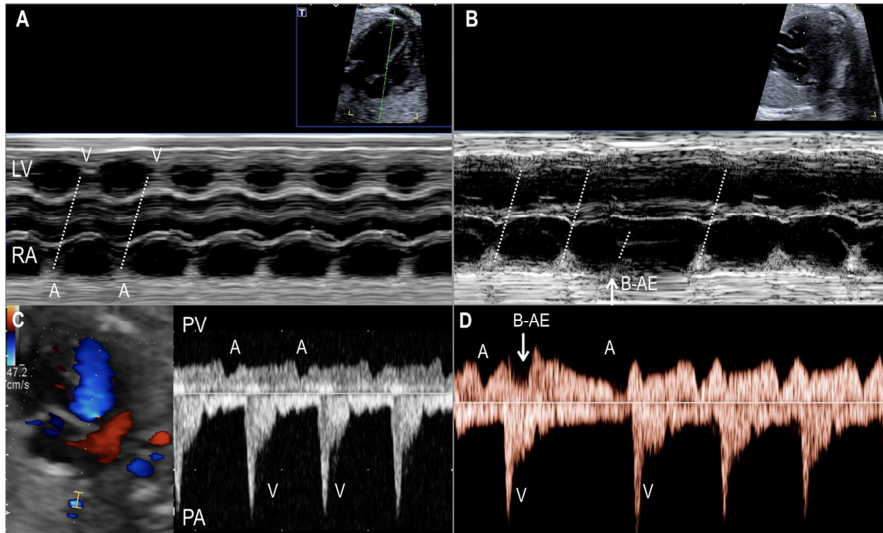
42. *** Eliasson H, Sonesson SE, Sharland G, Granath F, Simpson JM, Carvalho JS, et al. Isolated atrioventricular block in the fetus: a retrospective multinational, multicentre study of 175 patients. *Circulation* 2011; 124(18): 1919-26; 10.1161/CIRCULATIONAHA.111.041970
43. Van Hare GF. Magnetocardiography in the diagnosis of fetal arrhythmias. *Heart Rhythm* 2013; 10(8): 1199-200; 10.1016/j.hrthm.2013.06.005
44. Buyon JP, Hiebert R, Copel J, Craft J, Friedman D, Katholi M, et al. Autoimmune-associated congenital heart block: demographics, mortality, morbidity and recurrence rates obtained from a national neonatal lupus registry. *J Am Coll Cardiol* 1998; 31(7): 1658-66;
45. Levesque K, Morel N, Maltret A, Baron G, Masseur A, Orquevaux P, et al. Description of 214 cases of autoimmune congenital heart block: Results of the French neonatal lupus syndrome. *Autoimmun Rev* 2015; 14(12): 1154-60; 10.1016/j.autrev.2015.08.005
46. *** Friedman DM, Kim MY, Copel JA, Davis C, Phoon CKL, Glickstein JS, et al. Utility of Cardiac Monitoring in Fetuses at Risk for Congenital Heart Block. The PR Interval and Dexamethasone Evaluation (PRIDE) Prospective Study. *Circulation* 2008; 117: 485-93;
47. Jaeggi E, Laskin C, Hamilton R, Kingdom J, Silverman E. The importance of the level of maternal anti-Ro/SSA antibodies as a prognostic marker of the development of cardiac neonatal lupus erythematosus a prospective study of 186 antibody-exposed fetuses and infants. *J Am Coll Cardiol* 2010; 55(24): 2778-84;
48. Hutter D, Silverman ED, Jaeggi ET. The benefits of transplacental treatment of isolated congenital complete heart block associated with maternal anti-Ro/SSA antibodies: a review. *Scand J Immunol* 2010; 72(3): 235-41;
49. Saxena A, Izmirlly PM, Mendez B, Buyon JP, Friedman DM. Prevention and treatment in utero of autoimmune-associated congenital heart block. *Cardiol Rev* 2014; 22(6): 263-7; 10.1097/CRD.000000000000026

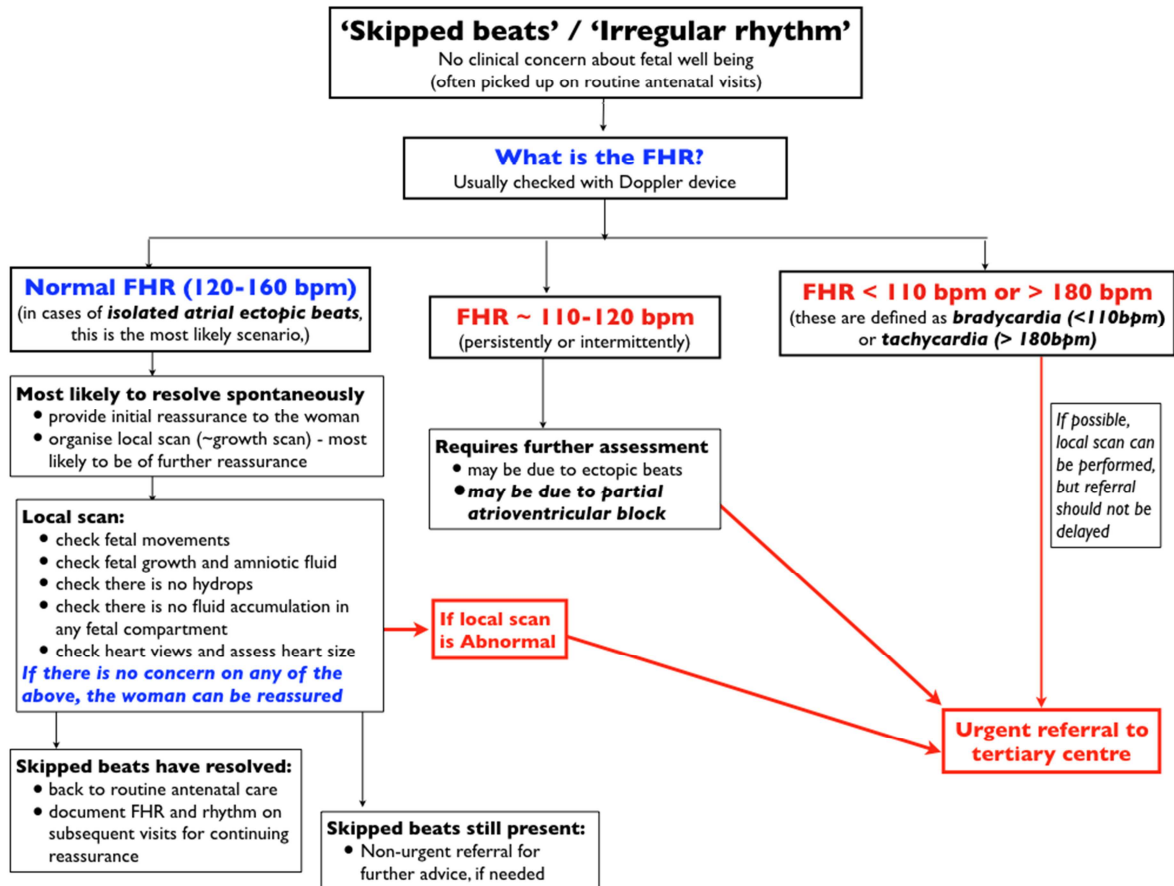
50. Vest AN, Zhou L, Huang X, Norekyan V, Bar-Cohen Y, Chmait RH, et al. Design and Testing of a Transcutaneous RF Recharging System for a Fetal Micropacemaker. *IEEE Trans Biomed Circuits Syst* 2017; 11(2): 336-46; 10.1109/TBCAS.2016.2620805
51. Cuneo BF, Mitchell MB, Marwan AI, Green M, von Alvensleben JC, Reynolds R, et al. Ex utero Intrapartum Treatment to Ventricular Pacing: A Novel Delivery Strategy for Complete Atrioventricular Block with Severe Bradycardia. *Fetal Diagn Ther* 2017; 42(4): 311-4; 10.1159/000475815
52. *** Izmirly PM, Costedoat-Chalumeau N, Pisoni C, Khamashta MA, Kim MY, Saxena A, et al. Maternal Use of Hydroxychloroquine is Associated with a Reduced Risk of Recurrent Anti-SSA/Ro Associated Cardiac Manifestations of Neonatal Lupus. *Circulation* 2012; 126(1): 76-82;
53. Ciardulli A, D'Antonio F, Magro-Malosso ER, Manzoli L, Anisman P, Saccone G, et al. Maternal steroid therapy for fetuses with second-degree immune-mediated congenital atrioventricular block: a systematic review and meta-analysis. *Acta Obstet Gynecol Scand* 2018; 10.1111/aogs.13338
54. Van den Berg NW, Slieker MG, van Beynum IM, Bilardo CM, de Bruijn D, Clur SA, et al. Fluorinated steroids do not improve outcome of isolated atrioventricular block. *Int J Cardiol* 2016; 225: 167-71; 10.1016/j.ijcard.2016.09.119
55. Izmirly PM, Saxena A, Sahl SK, Shah U, Friedman DM, Kim MY, et al. Assessment of fluorinated steroids to avert progression and mortality in anti-SSA/Ro-associated cardiac injury limited to the fetal conduction system. *Ann Rheum Dis* 2016; 75(6): 1161-5; 10.1136/annrheumdis-2015-208311
56. Cuneo BF, Ambrose SE, Tworetzky W. Detection and successful treatment of emergent anti-SSA-mediated fetal atrioventricular block. *Am J Obstet Gynecol* 2016; 215(4): 527-8; 10.1016/j.ajog.2016.07.002
57. Friedman DM, Llanos C, Izmirly PM, Brock B, Byron J, Copel J, et al. Evaluation of fetuses in a study of intravenous immunoglobulin as preventive therapy for congenital heart block: Results of a multicenter, prospective, open-label clinical trial. *Arthritis Rheum* 2010; 62(4): 1138-46;

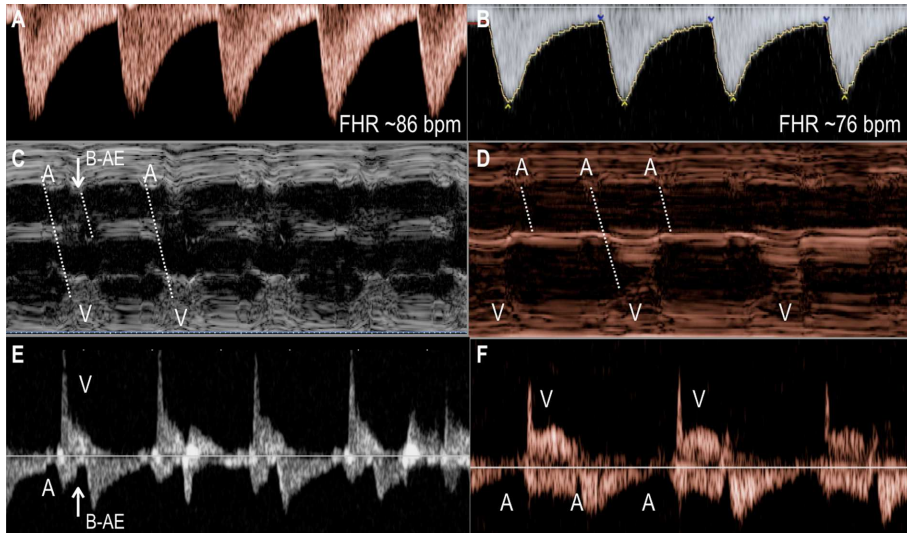
58. Pisoni CN, Brucato A, Ruffatti A, Espinosa G, Cervera R, Belmonte-Serrano M, et al. Failure of intravenous immunoglobulin to prevent congenital heart block: Findings of a multicenter, prospective, observational study. *Arthritis Rheum* 2010; 62(4): 1147-52;
59. Trucco SM, Jaeggi E, Cuneo B, Moon-Grady AJ, Silverman E, Silverman N, et al. Use of intravenous gamma globulin and corticosteroids in the treatment of maternal autoantibody-mediated cardiomyopathy. *J Am Coll Cardiol* 2011; 57(6): 715-23; 10.1016/j.jacc.2010.09.044
60. Ruffatti A, Cerutti A, Favaro M, Del Ross T, Calligaro A, Hoxha A, et al. Plasmapheresis, intravenous immunoglobulins and bethametasone - a combined protocol to treat autoimmune congenital heart block: a prospective cohort study. *Clin Exp Rheumatol* 2016; 34(4): 706-13;
61. Rein AJ, Mevorach D, Perles Z, Gavri S, Nadjari M, Nir A, et al. Early Diagnosis and Treatment of Atrioventricular Block in the Fetus Exposed to Maternal Anti-SSA/Ro-SSB/La Antibodies. A Prospective, Observational, Fetal Kinetocardiogram-Based Study. *Circulation* 2009; 119: 1867-72;
62. Jaeggi ET, Silverman ED, Laskin C, Kingdom J, Golding F, Weber R. Prolongation of the atrioventricular conduction in fetuses exposed to maternal anti-Ro/SSA and anti-La/SSB antibodies did not predict progressive heart block. A prospective observational study on the effects of maternal antibodies on 165 fetuses. *J Am Coll Cardiol* 2011; 57(13): 1487-92;
63. Bergman G, Eliasson H, Bremme K, Wahren-Herlenius M, Sonesson SE. Anti-Ro52/SSA antibody-exposed fetuses with prolonged atrioventricular time intervals show signs of decreased cardiac performance. *Ultrasound Obstet Gynecol* 2009; 34(5): 543-9; 10.1002/uog.7343
64. Kan N, Silverman ED, Kingdom J, Dutil N, Laskin C, Jaeggi E. Serial echocardiography for immune-mediated heart disease in the fetus: results of a risk-based prospective surveillance strategy. *Prenat Diagn* 2017; 37(4): 375-82; 10.1002/pd.5021

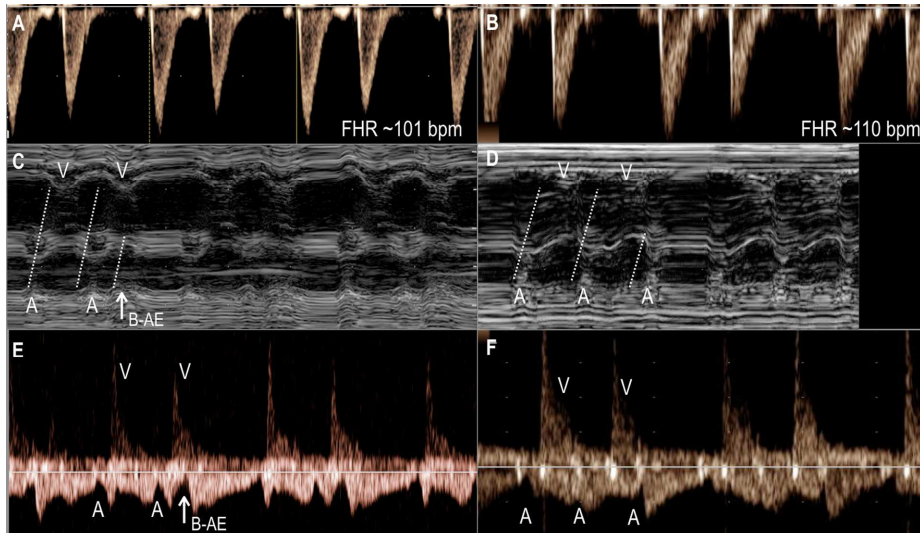
65. Cuneo BF, Moon-Grady AJ, Sonesson SE, Levasseur S, Hornberger L, Donofrio MT, et al. Heart sounds at home: feasibility of an ambulatory fetal heart rhythm surveillance program for anti-SSA-positive pregnancies. *J Perinatol* 2017; 37(3): 226-30; 10.1038/jp.2016.220

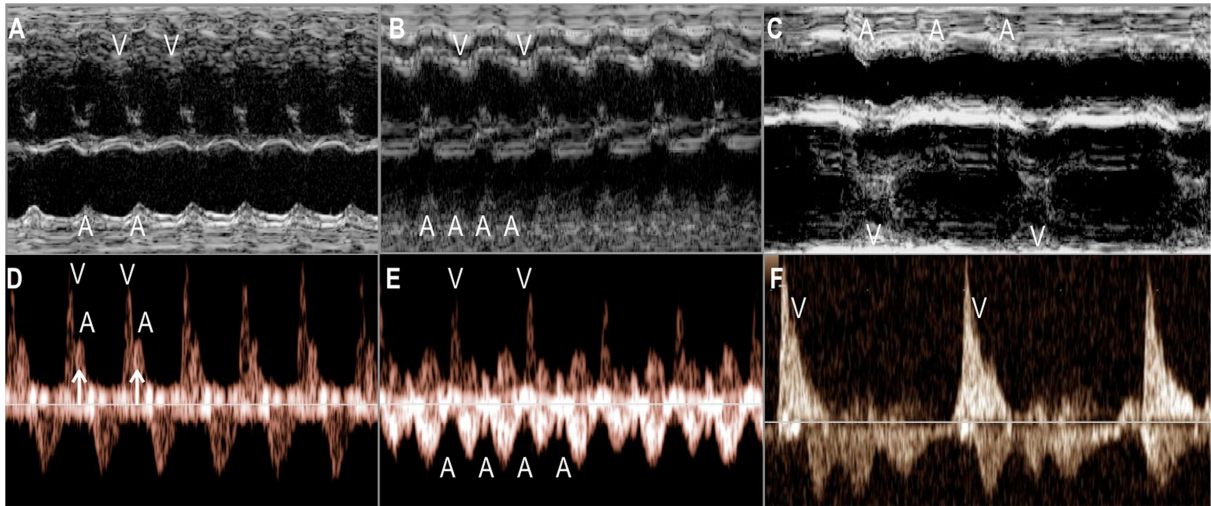
ACCEPTED MANUSCRIPT











ACCEPTED MANUSCRIPT

Fetal dysrhythmias

Practice Points

What we know

- Fetal dysrhythmias, mainly atrial ectopics, are common, often benign but can cause bradycardia and trigger tachycardia
- Tachycardias require urgent assessment as can lead to haemodynamic compromise, hydrops and death.
- SVT with 1:1 AV conduction and AF are the most common tachycardias. Transplacental treatment is successful in the majority.
- Bradycardia due to ectopic beats are well tolerated
- Bradycardia due to heart block is often associated with maternal auto-antibodies.
- There is no proven effective in-utero treatment for heart block

What we don't know

- Best drug to treat all fetal tachycardias
- Best practice to survey pregnancies affected by anti-Ro/ anti-La antibodies
- How to treat/ manage partial AV block
- How to pace the fetal heart

Research Agenda

- Randomized trial to treat fetal tachycardia (www.fasttherapytrial)
- Risk-stratification of fetuses at risk of long QT syndrome
- Early recognition and treatment of emerging heart block (www.heartsoundsathome)
- In-utero pacing for established complete heart block