

Cardiac sarcoma presenting with abdominal pain and mimicking myxoma on echocardiogram

Mohammad S Diab¹, Jeremy Smelt¹, Nick Fletcher² and Mazin Sarsam¹

¹Department of Cardiothoracic Surgery, St. George's Hospital, London SW17 0QT, UK

²Department of Anaesthesia, St. George's Hospital, London SW17 0QT, UK

Corresponding author: Mohammad S Diab. Email: diab.mohammed@gmail.com

Lesson

Cardiac sarcoma's are highly aggressive tumours. Clear resection margins ± autotransplant, followed by chemotherapy, offers the best survival chance. Therefore, frozen section should be performed when there is ambiguity in diagnosis.

Keywords

Cardiovascular medicine, surgery, oncology

Introduction

We present an unusual case of an AMI due to superior mesenteric artery (SMA) embolus originating from a left atrial sarcomatoid neoplasm mimicking a myxoma on echocardiogram. Acute mesenteric ischaemia (AMI) is associated with high mortality and the usual culprits are emboli due to atrial fibrillation or following low cardiac output state.

The patient underwent emergency embolectomy and bowel resection followed by cardiac surgery. Frozen section confirmed an undifferentiated sarcoma. Frozen section is necessary to identify malignant cardiac tumours and perform extensive tumour resection to obtain clear margin which dictates survival.

Case presentation

A previously fit and well 45-year-old man attended his local hospital with abdominal pain. He had raised inflammatory markers and serum lactate. Abdominal CT angiogram revealed a superior mesenteric artery embolus and evidence of infarcted bowel.

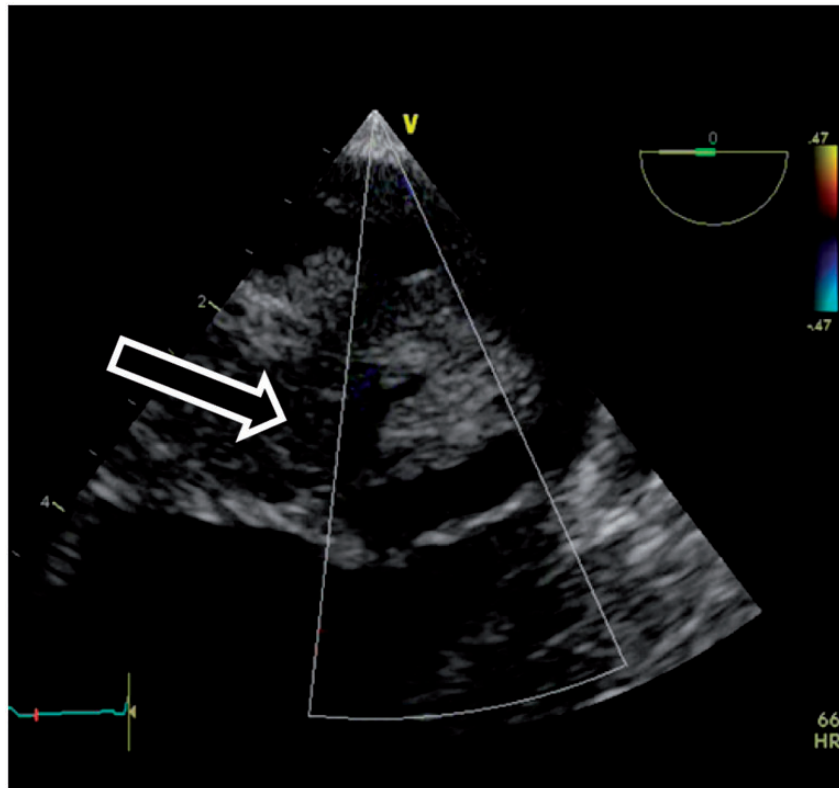
The patient underwent a laparotomy, superior mesenteric artery embolectomy and 30 cm of ischaemic jejunum was resected and a primary anastomosis was formed. The histology showed ischaemic bowel only. Transthoracic echocardiogram showed the presence of a large left atrial mobile mass attached via a pedicle, prolapsing through the mitral valve from the left atrium at 3.4 cm in length (Figure 1.)

It was unclear whether this was a myxoma or a thrombus. The patient's ventricular function was normal and a coronary angiogram was reported as normal. He was transferred to a cardiac centre and underwent median sternotomy and aortobicaval cannulation 17 days after his laparotomy. The heart was arrested with antegrade and retrograde cardioplegia. The mass was found to be densely adherent to the left atrial free wall through to the right pulmonary veins and the superior vena cava, which was then detached from the right atrium for access. Ambiguity about the tumour's nature made us send a frozen section specimen which revealed sarcomatoid appearances. The mass was peeled off the anterior mitral valve leaflet and excised with the invaded structures. The sinoatrial node had to be sacrificed. Bovine pericardium was used to reconstruct the left and right atrium and right pulmonary veins (Figure 2). On coming off, bypass mitral regurgitation was observed via the transesophageal echo and so the neo left atrium was reopened and a 32 mm Cosgrove-Edwards ring implanted. The patient had an uncomplicated and short hospital stay. Histology was consistent with mildly pleomorphic spindle shape sarcoma supported by positive immunohistochemistry for SMA and the presence of MDM2 gene amplification. Despite the extensive tumour resection and chambers reconstruction, there was tumour margin involvement. The patient remains well five months later and is under the care of a sarcoma oncology team.

Discussion

Primary cardiac tumours are rare (<0.04%), but fatal.¹ Malignant tumours constitute 25% of all primary cardiac tumours, of which sarcomas comprise >75%.¹ Surgery achieves the optimal results for treatment of localised sarcomas. Prognosis is dependent on radical tumour resection.² There is still no clear defined treatment guidelines for malignant

Figure 1. Transesophageal echocardiogram demonstrating a wide base left atrial mass (arrow).



cardiac tumours. There is no gender preference noted, and presentation is usually in the fourth decade of life.³ Three large series (reviewing 34, 21 and 95 cases respectively) showed that overall median survival was 12–20 months.^{3–5} Moreover, they also showed that survival was 6–10 months in R1 resection while that improved to 12–24 months in R0 resection. Surgical mortality was reported to be high (8.3%), albeit acceptable.⁴

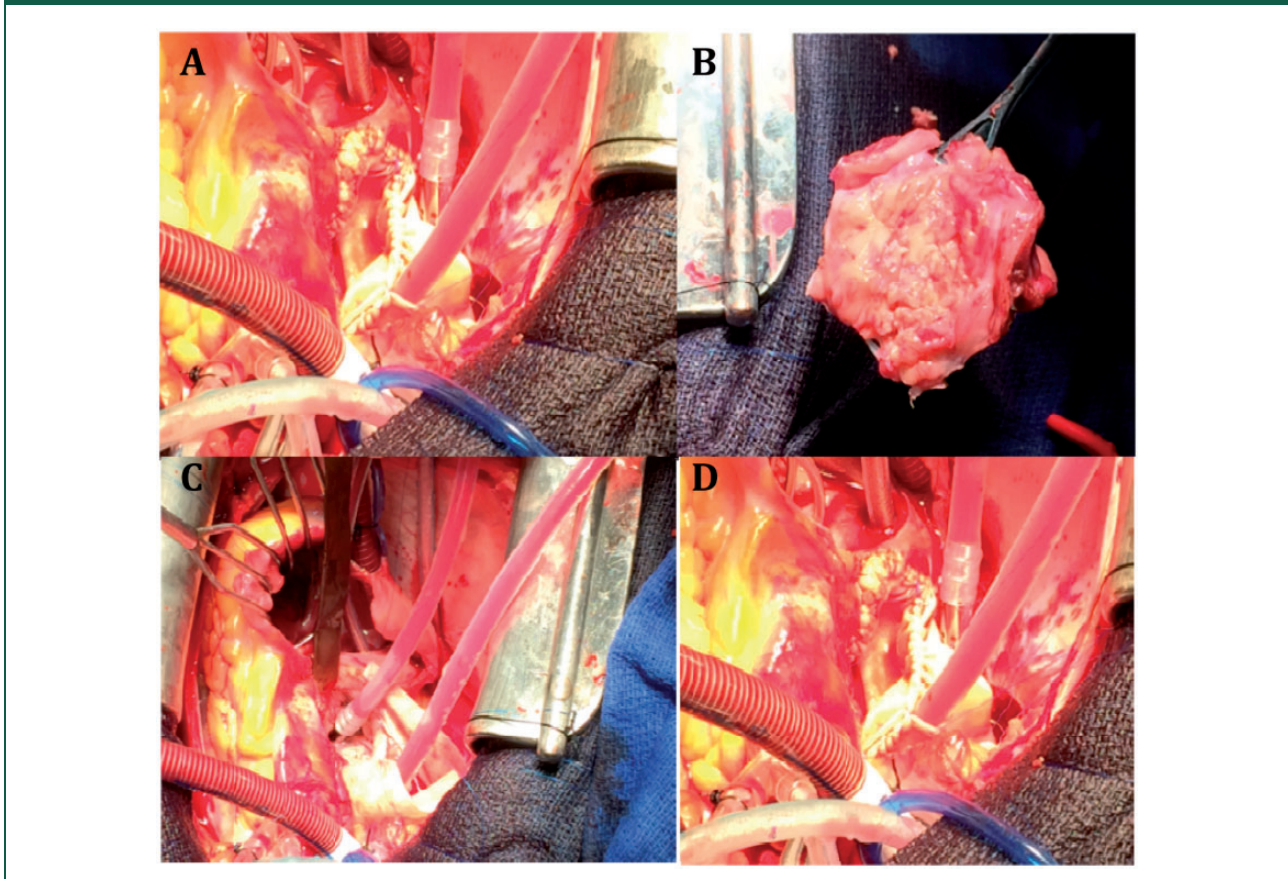
Due to the paucity of cases of this tumour, definite pathological or radiological diagnostic characteristic is challenging. Echocardiography detects cardiac tumours with high sensitivity and specificity,² but only endocardial biopsy gives the definitive diagnosis.² Usually, the rapidly progressive clinical course, multiple tumour growths and non-septal attachment of the tumour all suggest a malignant profile of the primary cardiac tumours. In our case, the tumour was attached to the septum and at the same time extending into the pulmonary veins. There was uncertainty in diagnosis and a frozen section confirmed the diagnosis and immediate reconstructive surgery to clear the tumour was performed.

As with any malignant tumour, we put the emphasis on clear resection margin to provide the best disease-

free survival. In two isolated case reports of left atrial sarcomas, the patients survived for 7 and 11 years.^{6,7} In both reports, the patients underwent a re-operation for local recurrence. Unsurprisingly, case series have shown that R0 resection can be achieved in only 38–42% of cases.^{3–5} Furthermore, emergency surgery was performed for palliation or to prevent further embolism that can lead to partial tumour resection. Thus, local recurrence is certain. Therefore, chemotherapy should be almost always administered. There has been controversy about offering heart transplant, and in many studies that showed no surgical advantage over surgical resection \pm chemotherapy.^{1,2} Also, there have been ethical issues about offering heart transplant to patients with malignant cardiac tumours. There is no specific guidance on chemotherapy regimens, but it seems that multiple chemotherapies are better and guidance should be aided by C-Kit sensitives.

To conclude, endocardial frozen section is necessary when there is echocardiographic ambiguity about the tumour nature. We recommend close follow-up and chemotherapy in all cardiac sarcomas. Primary (intimal) spindle shape sarcoma is very aggressive and R0 resection is difficult to achieve and heart transplantation may be indicated when

Figure 2. Intraoperative view. (a) Note that the tumour extends into and through the wall of the superior vena cava and the left atrial dome; (b) Complete tumour removal by en bloc resection, including the right atrial anterior and lateral wall, left atrial dome, and a large segment of the superior vena cava; (c) Repair of the left atrial dome; (d) Reconstruction of the right atrium and superior vena cava with bovine pericardium.



metastatic workup is negative. A cardiac sarcoma registry is required to obtain more solid management guidelines.

Declarations

Competing interests: None declared

Funding: None declared

Ethical approval: Written informed consent to publication was obtained from the patient's next of kin.

Guarantor: MSD

Contributorship: MSD did the literature search and wrote the manuscript. JS provided the images and revised the manuscript. NF and MS proof read and approved the final manuscript.

Acknowledgements: None

Provenance: Not commissioned; peer-reviewed by Chung Lim.

References

1. Jimenez MJM, Fuentes Manso R, Segovia Cubero J, et al. [Is heart transplantation for primary cardiac sarcoma a useful therapeutic option?]. *Rev Esp Cardiol* 2003; 56: 408–411.
2. Uberfuhr P, Meiser B, Fuchs A, et al. Heart transplantation: an approach to treating primary cardiac sarcoma? *J Heart Lung Transplant* 2002; 21: 1135–1139.
3. Ramlawi B, Leja MJ, Abu Saleh WK, et al. Surgical treatment of primary cardiac sarcomas: review of a single-institution experience. *Ann Thorac Surg* 2016; 101: 698–702.
4. Putnam JB Jr., Sweeney MS, Colon R, et al. Primary cardiac sarcomas. *Ann Thorac Surg* 1991; 51: 906–910.
5. Simpson L, Kumar SK, Okuno SH, et al. Malignant primary cardiac tumors: review of a single institution experience. *Cancer* 2008; 112: 2440–2446.
6. Clores MJ, Monzur F and Rajapakse R. Acute mesenteric ischemia caused by rare cardiac tumor embolus. *ACG Case Rep J* 2014; 2: 27–29.
7. Modi A, Lipnevicius A, Moorjani N and Haw M. Prolonged survival with left atrial spindle cell sarcoma. *Interact Cardiovasc Thorac Surg* 2009; 8: 703–704.