

Accepted Manuscript

A homozygous loss-of-function mutation in PTPN14 causes a syndrome of bilateral choanal atresia and early infantile-onset lymphedema

Arash Bordbar, Reza Maroofian, Pia Ostergaard, Mandana Kashaki, Sara Nikpour, Kristiana Gordon, Andrew Crosby, Pedram Khosravi, Azadeh Shojaei



PII: S2214-5400(17)30054-3
DOI: doi: [10.1016/j.mgene.2017.07.006](https://doi.org/10.1016/j.mgene.2017.07.006)
Reference: MGENE 342
To appear in: *Meta Gene*
Received date: 3 April 2017
Revised date: 19 July 2017
Accepted date: 22 July 2017

Please cite this article as: Arash Bordbar, Reza Maroofian, Pia Ostergaard, Mandana Kashaki, Sara Nikpour, Kristiana Gordon, Andrew Crosby, Pedram Khosravi, Azadeh Shojaei , A homozygous loss-of-function mutation in PTPN14 causes a syndrome of bilateral choanal atresia and early infantile-onset lymphedema, *Meta Gene* (2017), doi: [10.1016/j.mgene.2017.07.006](https://doi.org/10.1016/j.mgene.2017.07.006)

This is a PDF file of an unedited manuscript that has been accepted for publication. As a service to our customers we are providing this early version of the manuscript. The manuscript will undergo copyediting, typesetting, and review of the resulting proof before it is published in its final form. Please note that during the production process errors may be discovered which could affect the content, and all legal disclaimers that apply to the journal pertain.

A homozygous loss-of-function mutation in *PTPN14* causes a syndrome of bilateral choanal atresia and early infantile-onset lymphedema

***PTPN14* mutation in lymphedema-choanal atresia**

Arash Bordbar ^{a†}, Reza Maroofian ^{b,c†}, Pia Ostergaard ^c, Mandana Kashaki ^a, Sara Nikpour ^d, Kristiana Gordon ^c, Andrew Crosby ^b, Pedram Khosravi ^e, Azadeh Shojaei ^{f*}

- a) Department of neonatology, Shahid Akbarabadi hospital; Iran university of Medical Sciences, Tehran, Iran.
- b) Medical Research, RILD Wellcome Wolfson Centre (Level 4), Royal Devon and Exeter NHS Foundation Trust, Exeter, Devon, EX2 5DW, UK.
- c) Molecular & Clinical Sciences Research Institute, St. George's University of London, Cranmer Terrace, London SW17 0RE, UK.
- d) Paediatric department of Guilan University of medical sciences, Rasht, Iran.
- e) Laboratory of diagnosis medical genetic, Shahid Akbarabadi hospital; Iran university of Medical Sciences, Tehran, Iran.
- f) Department of Medical Genetics and Molecular Biology, Faculty of Medicine, Iran University of Medical Sciences, Tehran, Iran.

† These authors contributed equally to this work

* **Corresponding author:** Azadeh Shojaei

Department of Medical Genetics and Molecular Biology, Faculty of Medicine, University of Medical Sciences, Tehran, Iran.

E-mail: a_shojaei2007@yahoo.com

Telephone: +98-912-4836744

Fax: +98-21-88602217

Abstract

A homozygous truncating mutation in nonreceptor tyrosine phosphatase 14 (*PTPN14*) has recently been associated with an extremely rare autosomal recessive syndrome of congenital posterior choanal atresia and childhood-onset lymphedema. *PTPN14* has been shown to interact directly with the vascular endothelial growth factor receptor 3 (*VEGFR3*), a receptor tyrosine kinase essential for lymphangiogenesis. Here we present an Iranian family with a single child affected by high-arched palate, congenital hypothyroidism, dysmorphic face, bilateral choanal atresia and infantile-onset lymphedema. Screening of the *PTPN14* revealed a novel homozygous frameshift mutation in exon 4 predicted to result in premature truncation of the polypeptide product, which segregated with the disease phenotype. To our knowledge, this is the second family with "choanal atresia and lymphedema syndrome" to be reported worldwide. In contrast to the first reported family that showed lymphedema in late childhood, the patient described here displays lymphedema in her lower limbs at early infancy associated with growth delay, mild facial swelling, congenital hypothyroidism and some minor developmental abnormalities. This report confirms the causality of *PTPN14* loss-of-function mutations and further expands the clinical phenotype of this rare genetic syndrome.

Key words: *PTPN14*, Lymphedema, choanal atresia, mutation,

Abbreviations list

PTPN14: protein tyrosine phosphatase, non-receptor type 14

VEGFR3: vascular endothelial growth factor receptor 3

FOXC2: forkhead box C2

CCBE1: collagen and calcium binding EGF domains 1

SOX18: SRY-box 18

KIF11: kinesin family member 11

IKBKG: inhibitor of nuclear factor kappa B kinase subunit gamma

PTPN11: protein tyrosine phosphatase, non-receptor type 11

GATA2: GATA binding protein 2

FAT4: FAT atypical cadherin 4

NICU: neonatal intensive care unit

CT-scan: computed tomography scan

dbSNP: The Database of SNP

GME: The Greater Middle East

SNP: Single nucleotide polymorphic

IUGR: Intrauterine growth restriction

1. Introduction

An extremely rare autosomal recessive syndromic form of choanal atresia with childhood-onset lymphedema, high-arched palate and variable developmental abnormalities (OMIM#613611) in a consanguineous Yemenite kindred was first described in 1986 (SHEIKH et al., 1986). Recently this condition was shown to be associated with a homozygous mutation in *PTPN14* in nine affected members of this family (Au et al., 2010). *PTPN14* encodes nonreceptor tyrosine phosphatase protein which has been suggested to be required for lymphangiogenesis (Au et al., 2010). The mutation defined was an intragenic homozygous 2,016-bp deletion encompassing intron 6 to intron 7 of the *PTPN14* resulting in the loss of exon 7, frameshift (p.Ser194Argfs*19), and premature truncation (Au et al., 2010). All nine patients in the kindred displayed choanal atresia and by the age of 4 -6 years, six out of the nine had developed hard, non-pitting, lower limbs lymphedema (Har-El et al., 1991; Au et al., 2010). Around half of the patients presented a high-arched palate as well as other abnormalities including small nipples, pericardial effusions and pectus excavatum (Qazi et al., 1982; Har-El et al., 1991). To our knowledge, this is the only family reported worldwide with this clinical phenotype. Patients with choanal atresia typically present with other congenital anomalies, the most common being coloboma, cardiac disease, mental and physical development and growth delay, genital hypoplasia and craniofacial abnormalities (e.g. CHARGE syndrome) (Burrow et al., 2009). Besides *PTPN14*, mutations in several other genes, including *FOXC2*, *CCBE1*, *SOX18*, *KIF11*, *IKBKKG*, *PTPN11*, *GATA2* and *FAT4* have been identified to cause syndromes with lymphoedema as an associate feature (Fang et al., 2000; Zonana et al., 2000; Tartaglia et al., 2001; Irrthum et al., 2003; Alders et al., 2009; Ostergaard et al., 2011; Ostergaard et al., 2012; Alders et al., 2014). The majority of their encoded proteins cluster within the signalling pathway of *VEGFR3* (Mendola et al., 2013).

While a mouse model of *PTPN14* deficiency did not display choanal atresia, around 14 percent of the mutant animals showed forelimb and/or hindlimb swelling of the limb extremities or periorbital edema which started after 5 months of age (Au et al., 2010). These mice also displayed hyperplasia of lymphatic capillaries of the ears (Au et al., 2010). Mutations in *PTPN14* have also been shown to be involved in tumorigenesis and have been associated with colorectal cancer, basal cell carcinoma and neuroblastoma (Laczmanska and Sasiadek, 2011; Schramm et al., 2015; Wang et al., 2015; Bonilla et al., 2016). Furthermore, it is proposed that *PTPN14* may regulate angiogenesis and/or arteriovenous specification implicated as abnormal in pathology of hereditary haemorrhagic telangiectasia (Benzinou et al., 2012; Letteboer et al., 2015). Although suggestions have been made regarding the biological role of *PTPN14* in the regulation of the lymphatic system in mouse, the physiologic relevance of the protein to choanal development as one of the two main features of this syndrome, as well as high-arched palate in humans, is still poorly understood.

2. Material and Methods

2.1. Patients Phenotype analysis

This study, including clinical data collection and genomic analysis, was approved by the local institutional ethics committee of the Iran University of Medical Sciences, and all participants provided their written informed consent. The medical records of the patient were reviewed and the patient was examined by the clinical team of the Shahid Akbar-Abadi Hospital. Detailed patient family history was collected and pedigree was drawn accordingly (Fig. 1). Blood samples from the proband and her parents were collected for genetic testing.

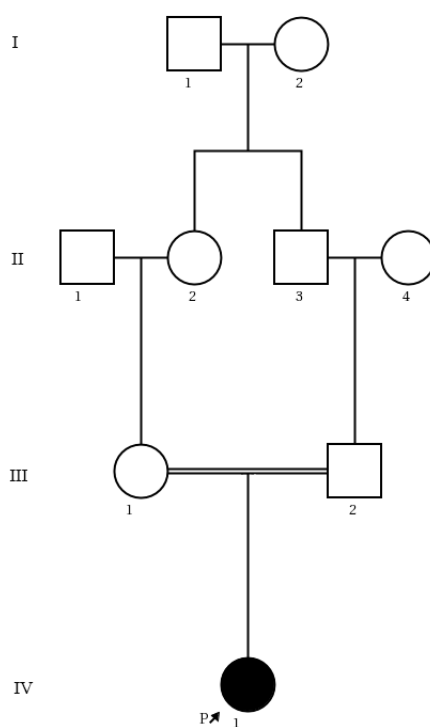


Fig. 1: Pedigree of the proband IV:1 born to a first cousin parents III:1 and III:2.

2.2. Genetic study genotype analysis

Genomic DNA was extracted from each participant's blood sample using the Qiagen Genra Puregene DNA isolation kit (Valencia, CA). Mutation analysis was performed by PCR amplifying all exons and exon-intron boundaries of the *PTPN14*, using twenty-two pairs of primers. Primer sequences and screening conditions are available upon request. All the

resulting amplicons underwent bidirectional dideoxy sequencing using an Applied Biosystems 3730XL DNA Analyzer, and sequencing data was analysed using Geospiza's FinchTV Software.

ACCEPTED MANUSCRIPT

3. Results

3.1. Clinical report

Herein, we report on a two year old Iranian girl born at full-term with a history of intrauterine growth restriction (IUGR), weighing 1850 g, and measuring 39.5 cm in length and with a head circumference of 32 cm under 10th centile. No history of medication (e.g. carbimazole), infectious diseases and drug/alcohol abuse was reported by mother during pregnancy. She was born by normal vaginal delivery to healthy first-cousin parents. She was admitted to the neonatal intensive care unit (NICU) of Shahid Akbar-Abadi Hospital (Tehran). She suffered from severe respiratory distress at birth and was immediately intubated, placed on mechanical ventilation and surfactant was administered. She was diagnosed with bilateral choanal atresia soon after birth and had seven corrective surgeries in the first five months after birth. She was dysmorphic with a “lymphedematous facial appearance” with hypertelorism, broad forehead, smooth philtrum, unilateral low set ear, high-arched palate and small nipples (Fig. 2).

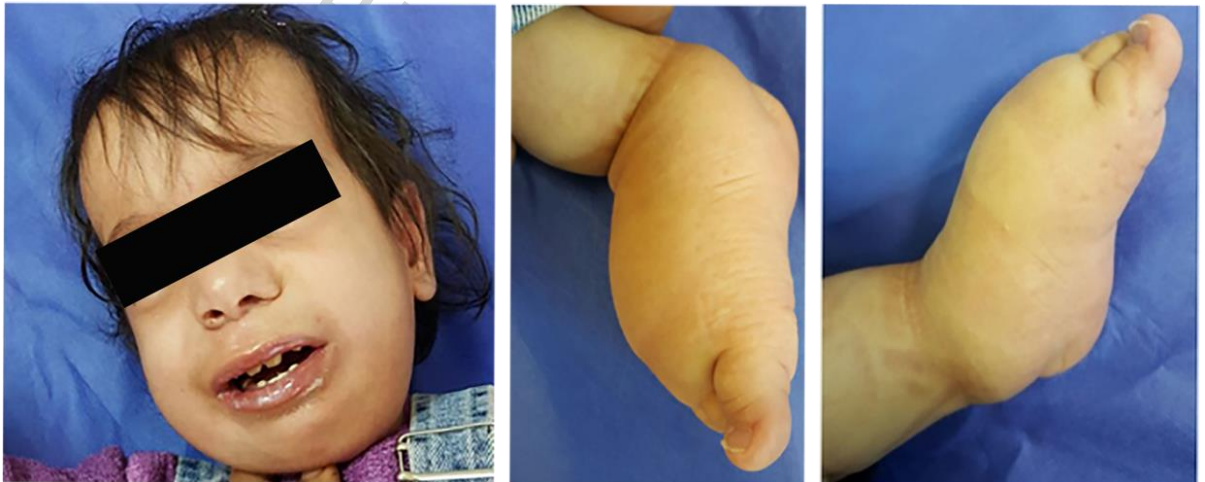

Fig. 2: Clinical photographs show mildly dysmorphic “Lymphedematous-looking face” of the patient and edema in her feet.

Subtle infraorbital swelling was observed below the right eye soon after birth. She displayed transient congenital hypothyroidism during the first year of her life, but at the age of one year this had resolved. On ultra-sound scan (at 18 month) the thyroid gland was in its normal location and its size appeared to be normal for her age. Systolic murmur (grade 3/6) was noted at the lower left sternal border and following cardiac assessment, a diagnosis of a small muscular ventricular septal defect with a good ejection fraction was made. At the age of two months she developed swelling of both feet up to her ankles.

On examination at 22 months, the edema was firm, fibrotic and with pitting. This was unchanged at the latest follow-up (Fig. 2). The diagnosis of lymphedema was confirmed by lymphoscintigraphy. The radiotracer was injected in dorsal aspect of the feet. Neither the lymphatic vessels, nor the lymph nodes were seen, which means these vessels are not developed in the proband (aplasia or complete obstruction) (Fig. 3).

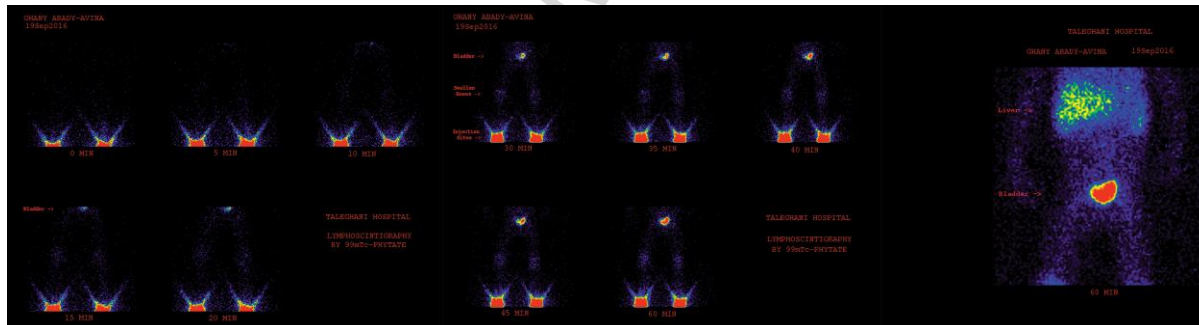


Fig. 3: Picture of lymphoscintigraphy.

The main lymphatic tracts of the lower limbs cannot be clearly visualised and there is no inguinal lymph node uptake at 60 minutes, representing a functional aplasia of the lower limb lymphatic system. There was no evidence of lymphedema in the other parts of her body. The parents did not have any history or signs of lymphedema.

At follow-up at 24 months the growth parameters were as follow: weight: 8.5 kg, height: 77c.m (below the 3rd centile) and the head circumference was 46 cm (10th centile).

The parent's height was also below the 3rd centile (The father's height: 155 cm; his weight: 60 kg and mother's height: 145 cm; her weight: 52 kg).

She had mild psychomotor developmental delay, which may be the result of the multiple surgeries, hospitalisation and prolonged NICU stay as she is currently catching-up with her developmental milestones. On CT-scan brain size and shape were normal. Her vision and hearing was normal. Furthermore, no other cutaneous abnormalities were detected. Although high-arched-palate and short stature were also present in the parents, there was no history of a similar condition in the family. All routine laboratory results were within normal range. Cytogenetic analysis showed a normal 46, XX female karyotype.

3.2. Genetics analysis

Direct sequencing of the 19 coding exons of *PTPN14* identified a novel 2bp insertion mutation Chr1 (GRCh37): g.214588012_214588013insAA; NM_005401.4: c.401_402insTT; p.(Leu135Tyrfs*5) present in the homozygote state in the fourth exon of the gene (Fig. 4, 5) (blasted in NCBI).

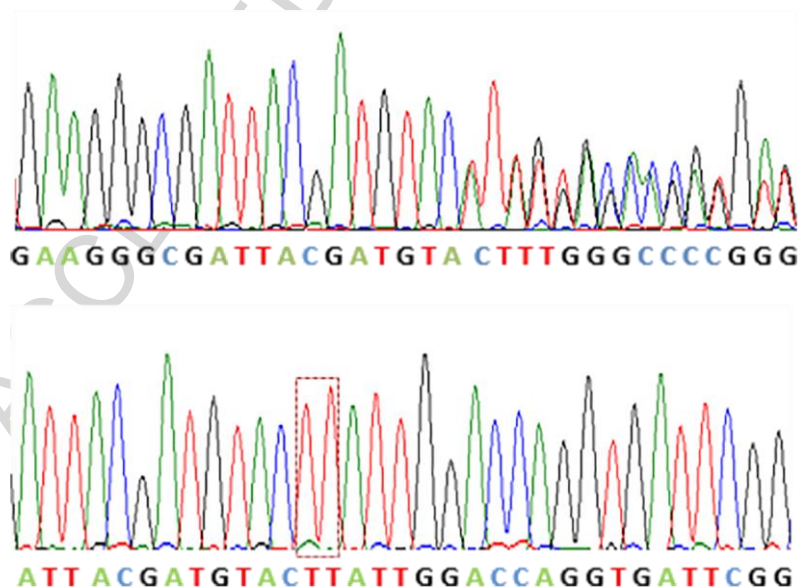


Fig. 4: The chromatograms show sequence of a section of exon 4. The top chromatogram revealed heterozygous insertion in parents and the bottom chromatogram is from sequencing of patient's DNA with homozygous insertion mutation (indicated by dashed box).

Wildtype sequence	ATTACGATGTACTTATTGGACCAGGTGATTCG
Mutant sequence	ATTACGATGTAC--ATTGGACCAGGTGATTCG

Fig. 5: Fragment of wildtype sequence (top) of exon 4 aligned to mutant sequence (bottom).

The mutation results in a frameshift which is predicted to cause polypeptide truncation and premature termination. Both parents were found to be heterozygous carriers of the variant, and the variant was not found in dbSNP, EVS/ESP, 1000Genome, ExAC, The Greater Middle East (GME) Variome Project as well as our in-house Exome sequencing database. Apart from this likely deleterious variant six rare single nucleotide polymorphic (SNP) variants, all homozygous, were identified in other exons of the gene (Fig. 6).

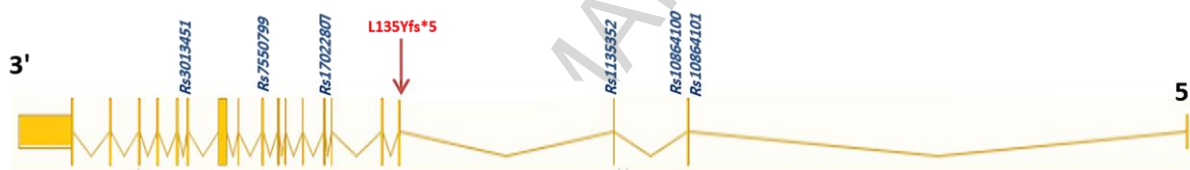

Fig. 6: Genomic organization of the PTPN14 and position of the mutation in exon 4 (red arrow) and other rare homozygous SNPs across the gene.

4. Discussion

Previously a report established that a null mutation in *PTPN14* is likely to be responsible for the main clinical features of the choanal atresia and lymphedema syndrome (Au et al., 2010). These overlapping clinical features led to *PTPN14* being considered as a candidate gene for the patient described here. Although exposure to some teratogenic factors such as carbimazole has been shown to be associated with occurrence of choanal atresia and other developmental abnormalities, no history of hyperthyroidism, thyrotoxicosis and use of carbimazole before and/or during pregnancy was noted in the mother of the patient (Greenberg et al., 1987; Papadimitriou et al., 2009). As with the previously described family,

the patient in this study presented with congenital choanal atresia and lower extremity lymphedema as the two cardinal clinical features (Table 1).

ACCEPTED MANUSCRIPT

Table 1: Comparison of clinical features of current patient with patients from Yemenite family with mutation in *PTPN14*.

Clinical features	Current Case	Pt1	Pt2	Pt3	Pt4	Pt5	Pt6	Pt7	pt8
gender	Female	male	female	female	male	male	female	female	male
Year & Age at examination (AAE)	24 months	1976 12 years	1977 11 years	Stillbirth	1983 6 years	1989	Died at 5 months	1979 9 years	1985 4 years
Choanal atresia	+/+	+/+	+/+	+/+	+/+	+/-	+/+	+/+	+/+
Lymphedema (AOO)	Bi Lower Extremities up to ankles 2 Months	Bi Lower extremities 5 years	Bi Lower extremities 5 years	NA	Bi Lower extremities Up to ankles 6 years	Bi Lower extremities 5 years	NA	Bi Lower extremities And thighs 4 years	Un Left Lower extremities 4 years
Highly-arched Palate	+	+	+	NA	+	-	NS	+	-
DD/ID	+/NA	+/-	-/-	NA	-/-	-/-	NA	-/-	-/-
Growth parameters	At 24 months W: 8.5 kg <3 rd centile H: 77 cm <3 rd centile HC: 46 cm 10 th centile	At 11 months W: <3 rd centile H: 3 rd centile HC: 48 cm (75 th centile)	At 8 months W: 8 Kg H: NS HC: 46.5 (95 th centile)	NA	NA	NA	NA	NA	NA
Small Nipples	+	+	-	-	-	-	-	-	-
Dysmorphic features	broad forehead, Hypertelorism, Lymphedematous-looking face, low nasal bridge, uni low-set ear, smooth philtrum, Slight Micrognathia	large head and ventricular dilation, slight hypertelorism, severe open-bite deformity, slight pectus excavatum	Slight Micrognathia	NA	Open-bite deformity	NS	NS	NS	NS
Other abnormalities	IUGR, CH, VSD, Abnormal ABR, RDS	Pericardial effusion	Pericardial effusion RDS and cyanosis	NS	NS	paraplegic Spina bifida	Death due to Complications of measles	Diffuse spotty discoloration of lower extremities Mild RDS, cyanosis	NS

+, present; -, absent; AAE, Age at examination; AOO, Age of onset; ABR, auditory brainstem response; Bi, bilateral; CH, Congenital hypothyroidism; DD/ID, Developmental delay/intellectual disability; H: Height; ; HC: Head Circumference; IUGR, Intrauterine growth restriction; NA, not applicable; NS, not stated; RDS, respiratory distress syndrome; Pt, patient; Uni, unilateral; VSD, ventricular septal defect; W: Weight.

*The Pt9 was an infant at the time of evaluation and he only had choanal atresia.

While the age of onset for lymphedema in the proband is much earlier than all reported patients, the location of edema was only limited to her feet like patient 4 (Table 1). Additionally, the patient demonstrated other anomalies not previously described in this syndrome including congenital hypothyroidism, IUGR, delayed growth and a dysmorphic swollen-looking face. Other clinical features in the patient which overlap with the Yemenite kindred include high-arched palate, cardiac condition, small nipples and mild developmental delay. Comparable to the patient 1 from previous report who had only developmental delay not leading to intellectual disability later in childhood (12 years old), the patient in this study had mild neurodevelopmental delay but she is catching up with her milestones and has grown out of it.

The patient was born small for gestational age and her growth was delayed. previous animal model study also showed a significant growth delay in mutant *PTPN14* mice in comparison with wild type controls (Au et al., 2010). Nevertheless, growth was reported normal in most of Yemenite patients [Qazi et al., 1982, Har-El et al., 1991] Given the fact that both parents of the proband are also short, growth delay in the patient might be due to familial short stature and/or constitutional delay of growth.

In the Yemenite kindred, the lymphedema was reported as juvenile onset, was limited to the lower limbs, and was not progressive since its onset (Table 1). *PTPN14* deficient mice displayed swelling of the limbs or/and periorbital edema (Au et al., 2010). None of the Yemenite family members have been reported to display periorbital edema. Proband was born with a “puffy” appearance in face and mild right infraorbital swelling was noticed at birth. The lymphedematous looking face of proband can be secondary symptoms to her congenital hypothyroidism or perhaps related to periorbital lymphedema as reported in the mouse model. A pattern of congenital generalised edema / non-immune hydrops has been reported in association with congenital hypothyroidism, however the swelling disappear upon

resolution of the hypothyroid problem (Mizell et al., 2010). As the onset of the lower limb lymphedema in proband is after the hypothyroidism, we speculate it is less likely to be related to the patient's transient hypothyroidism. In addition, according to the lymphoscintigraphy results there was no evidence of lymphatic drainage (Fig. 3) in proband suggesting lower limb lymphatic vessel obstruction. The lymphedema in proband has not progressed as far as in some of the Yemenite family members, but then she is still young. Therefore, we do not know if she has fully demonstrated the phenotype or if her lymphedema will become more severe or develop in other parts of the body as she becomes older.

Due to extreme rarity of this syndrome and very few reported patients, the phenotypic spectrum of this syndrome is not fully appreciated and we cannot confidently say that the additional features manifesting in the current patients and previous cases are part of the syndrome. However, additional features shared between our patient and some of the previous cases are most likely associated with this syndrome (Table 1). Genetic and clinical characterisation of more patients with this syndrome would greatly increase our knowledge about this rare genetic disease.

This report confirms truncating mutation of *PTPN14* as likely responsible for choanal atresia and primary lymphedema and expands the mutational and clinical spectrum of gene mutation.

Web source

1000 Genomes, <http://browser.1000genomes.org/index.html>

Ensembl Genome Browser, <http://www.ensembl.org/index.html>

ExAC Browser (Beta) Exome aggregation consortium,

<http://exac.broadinstitute.org/>

NHLBI Exome Sequencing Project (ESP) Exome Variant Server,

<http://evs.gs.washington.edu/EVS/>

The Greater Middle East (GME) Variome Project, <http://igm.ucsd.edu/gme/>

PROVEAN, http://provean.jcvi.org/seq_submit.php

MutationTaster, <http://www.mutationtaster.org/>

Acknowledge

We are grateful to the family for participating in this research.

ACCEPTED MANUSCRIPT

References

- Alders, M., Al-Gazali, L., Cordeiro, I., Dallapiccola, B., Garavelli, L., Tuysuz, B., Salehi, F., Haagmans, M.A., Mook, O.R., Majoie, C.B., Mannens, M.M. and Hennekam, R.C., 2014. Hennekam syndrome can be caused by FAT4 mutations and be allelic to Van Maldergem syndrome. *Hum Genet* 133, 1161-7.
- Alders, M., Hogan, B.M., Gjini, E., Salehi, F., Al-Gazali, L., Hennekam, E.A., Holmberg, E.E., Mannens, M.M., Mulder, M.F., Offerhaus, G.J., Prescott, T.E., Schroor, E.J., Verheij, J.B., Witte, M., Zwijnenburg, P.J., Vikkula, M., Schulte-Merker, S. and Hennekam, R.C., 2009. Mutations in CCBE1 cause generalized lymph vessel dysplasia in humans. *Nat Genet* 41, 1272-4.
- Au, A.C., Hernandez, P.A., Lieber, E., Nadroo, A.M., Shen, Y.M., Kelley, K.A., Gelb, B.D. and Diaz, G.A., 2010. Protein tyrosine phosphatase PTPN14 is a regulator of lymphatic function and choanal development in humans. *Am J Hum Genet* 87, 436-44.
- Benzinou, M., Clermont, F.F., Letteboer, T.G., Kim, J.H., Espejel, S., Harradine, K.A., Arbelaez, J., Luu, M.T., Roy, R., Quigley, D., Higgins, M.N., Zaid, M., Aouizerat, B.E., van Amstel, J.K., Giraud, S., Dupuis-Girod, S., Lesca, G., Plauchu, H., Hughes, C.C., Westermann, C.J. and Akhurst, R.J., 2012. Mouse and human strategies identify PTPN14 as a modifier of angiogenesis and hereditary haemorrhagic telangiectasia. *Nat Commun* 3, 616.
- Bonilla, X., Parmentier, L., King, B., Bezrukov, F., Kaya, G., Zoete, V., Seplyarskiy, V.B., Sharpe, H.J., McKee, T., Letourneau, A., Ribaux, P.G., Popadin, K., Basset-Seguin, N., Chaabene, R.B., Santoni, F.A., Andrianova, M.A., Guipponi, M., Garieri, M., Verdant, C., Grosdemange, K., Sumara, O., Eilers, M., Aifantis, I., Michielin, O., de Sauvage, F.J., Antonarakis, S.E. and Nikolaev, S.I., 2016. Genomic analysis identifies new drivers and progression pathways in skin basal cell carcinoma. *Nat Genet* 48, 398-406.
- Burrow, T.A., Saal, H.M., de Alarcon, A., Martin, L.J., Cotton, R.T. and Hopkin, R.J., 2009. Characterization of congenital anomalies in individuals with choanal atresia. *Arch Otolaryngol Head Neck Surg* 135, 543-7.
- Fang, J., Dagenais, S.L., Erickson, R.P., Arlt, M.F., Glynn, M.W., Gorski, J.L., Seaver, L.H. and Glover, T.W., 2000. Mutations in FOXC2 (MFH-1), a forkhead family transcription

- factor, are responsible for the hereditary lymphedema-distichiasis syndrome. *Am J Hum Genet* 67, 1382-8.
- Greenberg, F., Opitz, J.M. and Reynolds, J.F., 1987. Choanal atresia and athelia: methimazole teratogenicity or a new syndrome? *American journal of medical genetics* 28, 931-934.
- Har-El, G., Borderon, M.L. and Weiss, M.H., 1991. Choanal atresia and lymphedema. *Ann Otol Rhinol Laryngol* 100, 661-4.
- Irrthum, A., Devriendt, K., Chitayat, D., Matthijs, G., Glade, C., Steijlen, P.M., Fryns, J.P., Van Steensel, M.A. and Vikkula, M., 2003. Mutations in the transcription factor gene SOX18 underlie recessive and dominant forms of hypotrichosis-lymphedema-telangiectasia. *Am J Hum Genet* 72, 1470-8.
- Laczmanska, I. and Sasiadek, M.M., 2011. Tyrosine phosphatases as a superfamily of tumor suppressors in colorectal cancer. *Acta Biochim Pol* 58, 467-70.
- Letteboer, T.G., Benzinou, M., Merrick, C.B., Quigley, D.A., Zhau, K., Kim, I.J., To, M.D., Jablons, D.M., van Amstel, J.K., Westermann, C.J., Giraud, S., Dupuis-Girod, S., Lesca, G., Berg, J.H., Balmain, A. and Akhurst, R.J., 2015. Genetic variation in the functional ENG allele inherited from the non-affected parent associates with presence of pulmonary arteriovenous malformation in hereditary hemorrhagic telangiectasia 1 (HHT1) and may influence expression of PTPN14. *Front Genet* 6, 67.
- Mendola, A., Schlogel, M.J., Ghalamkarpour, A., Irrthum, A., Nguyen, H.L., Fastre, E., Bygum, A., van der Vleuten, C., Fagerberg, C., Baselga, E., Quere, I., Mulliken, J.B., Boon, L.M., Brouillard, P., Vikkula, M. and Lymphedema Research, G., 2013. Mutations in the VEGFR3 signaling pathway explain 36% of familial lymphedema. *Mol Syndromol* 4, 257-66.
- Mizell, J., Bhowmick, S.K. and Vidal, R.A., 2010. A baby with generalized edema. *Clin Pediatr (Phila)* 49, 1157-9.
- Ostergaard, P., Simpson, M.A., Connell, F.C., Steward, C.G., Brice, G., Woollard, W.J., Dafou, D., Kilo, T., Smithson, S., Lunt, P., Murday, V.A., Hodgson, S., Keenan, R., Pilz, D.T., Martinez-Corral, I., Makinen, T., Mortimer, P.S., Jeffery, S., Trembath, R.C. and Mansour, S., 2011. Mutations in GATA2 cause primary lymphedema associated with a predisposition to acute myeloid leukemia (Emberger syndrome). *Nat Genet* 43, 929-31.

- Ostergaard, P., Simpson, M.A., Mendola, A., Vasudevan, P., Connell, F.C., van Impel, A., Moore, A.T., Loeyes, B.L., Ghalamkarpour, A., Onoufriadis, A., Martinez-Corral, I., Devery, S., Leroy, J.G., van Laer, L., Singer, A., Bialer, M.G., McEntagart, M., Quarrell, O., Brice, G., Trembath, R.C., Schulte-Merker, S., Makinen, T., Vikkula, M., Mortimer, P.S., Mansour, S. and Jeffery, S., 2012. Mutations in KIF11 cause autosomal-dominant microcephaly variably associated with congenital lymphedema and chorioretinopathy. *Am J Hum Genet* 90, 356-62.
- Papadimitriou, A., Karapanou, O., Papadopoulou, A., Nicolaidou, P. and Fretzayas, A., 2009. Congenital bilateral amazia associated with bilateral choanal atresia. *Am J Med Genet A* 149A, 1529-31.
- Qazi, Q.H., Kanchanapoomi, R., Beller, E. and Collins, R., 1982. Inheritance of posterior choanal atresia. *Am J Med Genet* 13, 413-6.
- Schramm, A., Koster, J., Assenov, Y., Althoff, K., Peifer, M., Mahlow, E., Odersky, A., Beisser, D., Ernst, C., Henssen, A.G., Stephan, H., Schroder, C., Heukamp, L., Engesser, A., Kahlert, Y., Theissen, J., Hero, B., Roels, F., Altmuller, J., Nurnberg, P., Astrahantseff, K., Gloeckner, C., De Preter, K., Plass, C., Lee, S., Lode, H.N., Henrich, K.O., Gartlgruber, M., Speleman, F., Schmezer, P., Westermann, F., Rahmann, S., Fischer, M., Eggert, A. and Schulte, J.H., 2015. Mutational dynamics between primary and relapse neuroblastomas. *Nat Genet* 47, 872-7.
- SHEIKH, T., QAZI, Q. and BELLER, E., 1986. POSTERIOR CHOANAL ATRESIA-LYMPHEDEMA ASSOCIATION IN A KINDRED, PEDIATRIC RESEARCH. WILLIAMS & WILKINS 351 WEST CAMDEN ST, BALTIMORE, MD 21201-2436, pp. A272-A272.
- Tartaglia, M., Mehler, E.L., Goldberg, R., Zampino, G., Brunner, H.G., Kremer, H., van der Burgt, I., Crosby, A.H., Ion, A., Jeffery, S., Kalidas, K., Patton, M.A., Kucherlapati, R.S. and Gelb, B.D., 2001. Mutations in PTPN11, encoding the protein tyrosine phosphatase SHP-2, cause Noonan syndrome. *Nat Genet* 29, 465-8.
- Wang, L., Xi, W., Zheng, G., Zhou, C., Jin, G., He, C., Cai, M. and Zhu, Q., 2015. [Expression and clinical significance of PTPN14 in cholangiocarcinoma]. *Xi Bao Yu Fen Zi Mian Yi Xue Za Zhi* 31, 1251-4.
- Zonana, J., Elder, M.E., Schneider, L.C., Orlow, S.J., Moss, C., Golabi, M., Shapira, S.K., Farndon, P.A., Wara, D.W., Emmal, S.A. and Ferguson, B.M., 2000. A novel X-linked disorder of immune deficiency and hypohidrotic ectodermal dysplasia is allelic to

incontinentia pigmenti and due to mutations in IKK-gamma (NEMO). Am J Hum Genet 67, 1555-62.

ACCEPTED MANUSCRIPT

Legends

Title and legends to Figures

Fig. 1:

Pedigree of the proband IV:1 born to a first cousin parents III:1 and III:2.

Fig. 2:

Clinical photographs show mildly dysmorphic “Lymphedematous-looking face” of the patient and edema in her feet.

Fig. 3:

Picture of lymphoscintigraphy

Fig. 4:

The chromatograms show sequence of a section of exon 4. The top chromatogram revealed heterozygous insertion in parents and the bottom chromatogram is from sequencing of patient’s DNA with homozygous insertion mutation (indicated by dashed box).

Fig. 5:

Fragment of wildtype sequence (top) of exon 4 aligned to mutant sequence (bottom).

Fig. 6:

Genomic organization of the PTPN14 and position of the mutation in exon 4 (red arrow) and other rare homozygous SNPs across the gene.

Table 1:

Comparison of clinical features of the current patient with patients from Yemenite family1 with a mutation in PTPN14.

Highlights

Short collection of bullet points that convey the core findings of this article

- The new homozygous *truncating* mutation in *PTPN14*
- This report confirms the causality of *PTPN14* mutations as pathogenic variant
- This is the 2nd case with "choanal atresia and lymphedema syndrome" worldwide
- This report expands the clinical phenotype of this rare genetic syndrome
- In contrast to the 1st reported family, the patient displays lymphedema at early age

ACCEPTED MANUSCRIPT