



Effectiveness of contingent screening for placenta accreta spectrum disorders based on persistent low-lying placenta and previous uterine surgery

C. M. COUTINHO^{1,2#}, V. GIORGIONE^{3#}, L. NOEL², B. LIU², E. CHANDRAHARAN⁴, J. PRYCE⁵, A. P. FRICK², B. THILAGANATHAN^{2,3†} and A. BHIDE^{2†}

¹Department of Obstetrics and Gynecology, Ribeirão Preto Medical School, University of São Paulo, Ribeirão Preto, SP, Brazil; ²Fetal Medicine Unit, St George's University Hospitals NHS Foundation Trust, University of London, London, UK; ³Vascular Biology Research Centre, Molecular and Clinical Sciences Research Institute, St George's University of London, London, UK; ⁴Global Academy of Medical Education & Training, London, UK; ⁵Cellular Pathology, St George's University Hospitals NHS Foundation Trust, London, UK

KEYWORDS: abnormally invasive placenta; Cesarean delivery; diagnosis; low-lying placenta; placenta accreta; placenta previa; risk factors; screening

CONTRIBUTION

What are the novel findings of this work?

Routine contingent screening for placenta accreta spectrum (PAS) disorders based on the finding of placenta previa in the third trimester and previous uterine surgery is effective in a public healthcare setting.

What are the clinical implications of this work?

A contingent screening strategy for PAS disorders is feasible in an ultrasound service in which placental location is routinely assessed. When linked to a PAS diagnostic and surgical management service, adoption of such a screening strategy has the potential to significantly reduce the maternal morbidity and mortality associated with this condition.

ABSTRACT

Objectives Maternal mortality related to placenta accreta spectrum (PAS) disorders remains substantial when diagnosed unexpectedly at delivery. The aim of this study was to evaluate the effectiveness of a routine contingent ultrasound screening program for PAS.

Methods This was a retrospective study of data obtained between 2009 and 2019, involving two groups: a screening cohort of unselected women attending for routine mid-trimester ultrasound assessment and a diagnostic cohort consisting of women referred to the

PAS diagnostic service with a suspected diagnosis of PAS. In the screening cohort, women with a low-lying placenta at the mid-trimester assessment were followed up in the third trimester, and those with a persistent low-lying placenta (i.e. placenta previa) and previous uterine surgery were referred to the PAS diagnostic service. Ultrasound assessment by the PAS diagnostic service consisted of two-dimensional grayscale and color Doppler ultrasonography, and women with a diagnosis of PAS were usually managed with conservative myometrial resection. The final diagnosis of PAS was based on a combination of intraoperative clinical findings and histopathological examination of the surgical specimen.

Results In total, 57 179 women underwent routine mid-trimester fetal anatomy assessment, of whom 220 (0.4%) had a third-trimester diagnosis of placenta previa. Seventy-five of these women were referred to the PAS diagnostic service because of a history of uterine surgery, and 21 of 22 cases of PAS were diagnosed correctly (sensitivity, 95.45% (95% CI, 77.16–99.88%) and specificity, 100% (95% CI, 99.07–100%)). Univariate analysis demonstrated that parity ≥ 2 (odds ratio (OR), 35.50 (95% CI, 6.90–649.00)), two or more previous Cesarean sections (OR, 94.20 (95% CI, 22.00–656.00)) and placenta previa (OR, 20.50 (95% CI, 4.22–369.00)) were the strongest risk factors for PAS. In the diagnostic cohort, there were 173 referrals, with one false-positive and three false-negative diagnoses, resulting in a sensitivity

Correspondence to: Prof. B. Thilaganathan, Fetal Medicine Unit, Department of Obstetrics and Gynaecology, St George's University Hospitals NHS Foundation Trust, University of London, Blackshaw Road, London SW17 0QT, UK (e-mail: basky@pobox.com)

#C.M.C. and V.G. are joint first authors. †B.T. and A.B. are joint senior authors.

Accepted: 21 August 2020

of 96.63% (95% CI, 90.46–99.30%) and a specificity of 98.81% (95% CI, 93.54–99.97%).

Conclusions A contingent screening strategy for PAS is both feasible and effective in a routine healthcare setting. When linked to a PAS diagnostic and surgical management service, adoption of such a screening strategy has the potential to reduce the maternal morbidity and mortality associated with this condition. However, larger prospective studies are necessary before implementing this screening strategy into routine clinical practice. © 2020 The Authors. *Ultrasound in Obstetrics & Gynecology* published by John Wiley & Sons Ltd on behalf of International Society of Ultrasound in Obstetrics and Gynecology.

INTRODUCTION

Placenta accreta spectrum (PAS) disorders are a recognized cause of major maternal morbidity and mortality, with a reported prevalence of between 0.01% and 1.1% of pregnancies¹. The incidence of PAS is increasing worldwide, which is attributed to the rising rate of Cesarean section^{2–5}. Previous Cesarean birth is associated with an almost three-fold increase in the risk of PAS in the next pregnancy, as compared with previous vaginal delivery⁶. The main risk factor for PAS in the current pregnancy is a diagnosis of placenta previa, with more than 90% of PAS cases being associated with placenta previa combined with a history of uterine surgery^{7–10}. PAS is associated with a significant increase in maternal morbidity and mortality from massive peripartum hemorrhage^{11,12}. However, hemorrhagic morbidity can be reduced significantly if a diagnosis of PAS is made prior to admission at the time of delivery¹³. Systematic screening and diagnosis of PAS would permit referral of these high-risk women to tertiary hospitals with specialized multidisciplinary teams experienced in the management of pregnancies complicated by PAS^{14,15}.

The antenatal ultrasound diagnosis of PAS is possible, with close to 90% accuracy, in specialist referral centers with expertise in the diagnosis of PAS^{16,17}. However, the diagnostic accuracy of PAS screening in non-specialist referring hospitals is only 50%, as clinical suspicion for PAS and/or knowledge of risk factors is low^{18,19}. There is a clinical need for an effective and systematic screening program for PAS in referring hospitals, so that those cases with suspected PAS can be referred to a PAS diagnostic center and, if PAS is confirmed, women can be referred for specialist surgical management to prevent the maternal morbidity associated with undiagnosed PAS.

The aim of this study was to evaluate the effectiveness of a contingent screening program for the identification of pregnancies with PAS based on a persistent low-lying placenta in the third trimester in women with a history of previous uterine surgery or Cesarean section.

METHODS

This was a retrospective cohort study of data obtained between 2009 and 2019 in the Fetal Medicine Unit of St George's University Hospitals NHS Foundation Trust, London, UK. Two cohorts of patients were included in the study: a 'screening cohort' of unselected women attending for routine mid-trimester ultrasound assessment at 18–23 weeks' gestation and a 'diagnostic cohort' consisting of local and external referrals to the PAS diagnostic service for suspicion of PAS. In the screening cohort, women diagnosed with a low-lying placenta (leading edge of the placenta less than 2 cm from the internal cervical os) at the mid-trimester fetal anomaly assessment were scheduled for a 32–34-week placenta-location scan²⁰. At this assessment, placenta previa was confirmed if the leading edge of the placenta was still within 2 cm of the internal os^{20,21}. Patients with confirmed placenta previa and a history of previous uterine surgery or Cesarean section were referred to the PAS diagnostic service. Women with a low-lying placenta at the mid-trimester ultrasound examination who transferred to another center before assessment of placental location at 32–34 weeks were excluded from the analysis.

All women undergoing routine ultrasound screening in pregnancy were assessed by qualified sonographers, and any cases with fetal or maternal complications were managed by maternal–fetal medicine specialists. In particular, the PAS diagnostic service was run by two consultants (B.T., A.B.) with significant experience and expertise in the prenatal diagnosis of PAS. Ultrasound assessment by the PAS diagnostic service consisted of two-dimensional grayscale ultrasound and color Doppler ultrasonography, as described previously^{22–25}. The following markers were assessed: (1) the presence of multiple irregular lacunar spaces within the placenta with turbulent blood flow on Doppler ultrasonography (peak systolic velocity often > 10 cm/s); (2) loss of the 'clear zone' (i.e. the normal hypoechoic line between the placenta and the myometrium); (3) myometrial thinning of the retroplacental area; (4) increased placental thickness; and (5) bladder wall interruption, defined as loss or irregularity of the hyperechoic line between the uterine serosa and bladder. Color Doppler was used at the discretion of the examiner, mainly to differentiate lacunae from placental lakes^{22,23,26}. The presence of two or more of these ultrasound signs was considered diagnostic of PAS. Cases with one isolated sign were classified as equivocal, and the absence of any ultrasound signs was considered negative for a PAS diagnosis. Magnetic resonance imaging was performed only in cases in which ultrasound signs of extrauterine invasion of the placenta (focal exophytic mass, distortion of cervix or parametrial anatomy) were detected. Women with a diagnosis of PAS were referred to the PAS surgical team for further management, usually with a conservative surgical technique (Triple P procedure) that is recommended by the International Federation of Gynecology and Obstetrics as an alternative to peripartum hysterectomy^{15,27,28}.

Eligible pregnancies were identified by searching the electronic database (ViewPoint version 5.6.26.148; ViewPoint Bildverarbeitung GMBH, Wessling, Germany) and by review of surgical notes and histological records. Demographic, surgical and histological data and obstetric history were retrieved from the clinical records. The final diagnosis of PAS was based on intraoperative clinical findings and histopathological examination of the surgical specimen²⁹. A histological diagnosis of placenta accreta, increta or percreta was possible only when hysterectomy or partial-myometrial-resection specimens were accessible for examination. If a histological specimen was not available, the final PAS diagnosis was based on the surgical record of adherent placenta. Ethical approval and signed patient consent were not required, in line with the UK Regional Health Authority decision tool. The findings of this study were reported in agreement with the STROBE Statement³⁰.

Statistical analysis

Comparisons between continuous and categorical variables were performed using the Kruskal–Wallis test and the χ^2 square test or Fisher's exact test, respectively. Univariate binomial logistic regression analysis was carried out to determine which risk factors were associated with PAS in women with placenta previa in the screening cohort. Owing to the limited number of PAS cases, forward stepwise multivariable logistic regression analysis was performed to determine which factors identified on univariate analysis contributed to the prediction of PAS in women with placenta previa and previous Cesarean section. Analysis was carried out using RStudio statistical software version 1.0.136 (RStudio, Inc., Boston, MA, USA) and MedCalc for Windows, version 19.4.1 (MedCalc Software, Ostend, Belgium). Statistical significance was defined as $P < 0.05$.

RESULTS

Screening cohort

A total of 57 179 women underwent routine mid-trimester fetal anatomy assessment at 18–23 weeks' gestation between 2009 and 2019. Among the 4486 (7.8%) women with a repeat scan scheduled because of a low-lying placenta, 415 (9.3%) had a diagnosis of placenta previa at 32–34 weeks (Figure 1). Two hundred and twenty women had a final diagnosis of placenta previa at subsequent assessments, of whom 75 (34.1%) were referred to the PAS diagnostic service because of a history of uterine surgery. This final cohort contained 22 cases of PAS, of which 21 were identified correctly by the PAS diagnostic service and managed surgically (Table S1). Additionally, five women who subsequently underwent emergency delivery before 32 weeks were followed up serially from the first trimester for a diagnosis of scar implantation, and there was one case of focal PAS in the non-placenta previa cohort in a woman with a previous myomectomy. The overall performance of the contingent PAS screening program in which women

with a diagnosis of placenta previa and previous uterine surgery were referred to a specialist PAS diagnostic service was: sensitivity, 95.45% (95% CI, 77.16–99.88%); specificity, 100% (95% CI, 99.07–100%); negative predictive value, 99.75% (95% CI, 98.30–99.96%); and positive predictive value, 100% (95% CI not calculable).

The demographic characteristics and risk factors for PAS in women with placenta previa at 32–34 weeks who had confirmed PAS and those without evidence of abnormal placental invasion are shown in Table 1. Univariate analysis demonstrated that parity ≥ 2 (odds ratio (OR), 35.50 (95% CI, 6.90–649.00)), two or more previous Cesarean sections (OR, 94.20 (95% CI, 22.00–656.00)) and placenta previa at the final scan (OR, 20.50 (95% CI, 4.22–369.00)) were the strongest risk factors for PAS. Smoking (OR, 1.12 (95% CI, 0.06–5.92)), body mass index $> 24 \text{ kg/m}^2$ (OR, 1.04 (95% CI, 0.95–1.11)) and previous uterine surgery other than Cesarean section (OR, 3.49 (95% CI, 0.77–11.60)) were not associated with PAS in this cohort. Paired stepwise multivariable logistic regression analysis demonstrated that the strongest risk factors for PAS, when taking into account the number of previous Cesarean sections, were variables related to placental location and ethnicity (Table 2). Maternal age, Asian ethnicity and multiparity were no longer associated with an increased risk for PAS after controlling for previous Cesarean section.

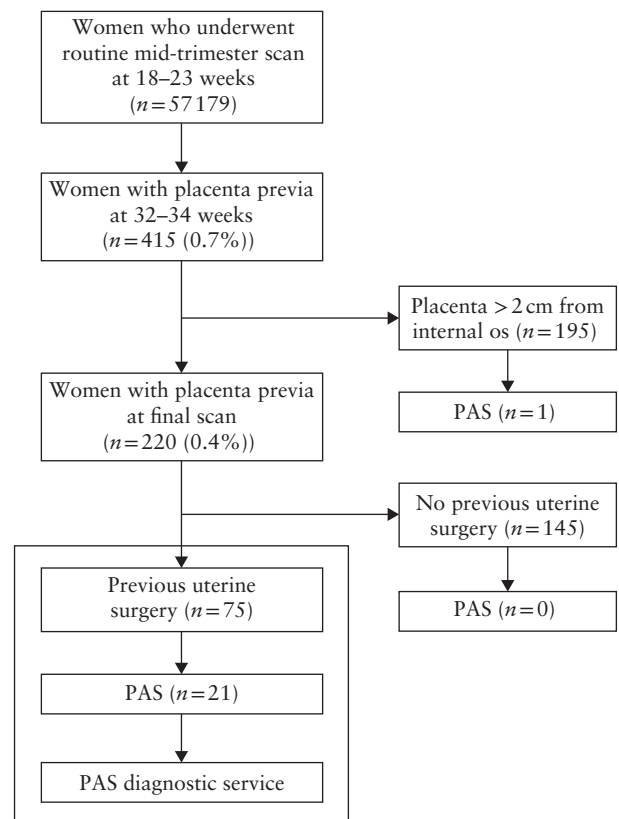


Figure 1 Flowchart of unselected women in routinely screened cohort, in which those with diagnosis of placenta previa and history of uterine surgery were referred to placenta accreta spectrum (PAS) diagnostic service for further management.

Table 1 Univariate analysis of risk factors for placenta accreta spectrum (PAS) disorders in 415 women with diagnosis of placenta previa at 32–34 weeks' gestation

Variable	No PAS (n = 393)	PAS (n = 22)	Odds ratio (95% CI)	P
Maternal age (years)	35.0 (32.0–38.0)	39.0 (35.0–40.7)	1.11 (1.02–1.21)†	0.018
Ethnicity*				
Caucasian	243 (61.8)	3 (13.6)	Reference	
Asian	94 (23.9)	6 (27.3)	5.17 (1.34–24.90)	0.022
Afro-Caribbean	46 (11.7)	11 (50.0)	19.40 (5.79–88.10)	< 0.001
Smoker	16 (4.1)	1 (4.5)	1.12 (0.06–5.92)	0.913
Assisted conception	62 (15.8)	0 (0.0)	—	—
Body mass index (kg/m ²)	24.2 (21.9–27.6)	25.9 (22.9–28.3)	1.04 (0.95–1.11)‡	0.368
Parity				
0	180 (45.8)	1 (4.5)	Reference	
1	142 (36.1)	7 (31.8)	8.87 (1.55–167.00)	0.042
≥ 2	71 (18.1)	14 (63.6)	35.50 (6.90–649.00)	< 0.001
Previous Cesarean section				
0	314 (79.9)	2 (9.1)	Reference	
1	64 (16.3)	11 (50.0)	27.00 (7.03–177.00)	< 0.001
≥ 2	15 (3.8)	9 (40.9)	94.20 (22.00–656.00)	< 0.001
Previous prelabor Cesarean section	35 (8.9)	8 (36.4)	8.89 (3.16–24.70)	< 0.001
Previous intrapartum Cesarean section	36 (9.2)	7 (31.8)	6.79 (2.34–18.80)	< 0.001
Previous other uterine surgery	17 (4.3)	3 (13.6)	3.49 (0.77–11.60)	0.061
Fibroids	21 (5.3)	3 (13.6)	2.80 (0.62–9.07)	0.119
Placenta covering internal cervical os at last scan	128 (32.6)	20 (90.9)	20.70 (5.92–231.00)	< 0.001
Placenta within 2 cm of internal cervical os at last scan	199 (50.6)	21 (95.5)	20.50 (4.22–369.00)	0.030
Anterior placenta at last scan	91 (23.2)	18 (81.8)	14.90 (5.41–52.70)	< 0.001

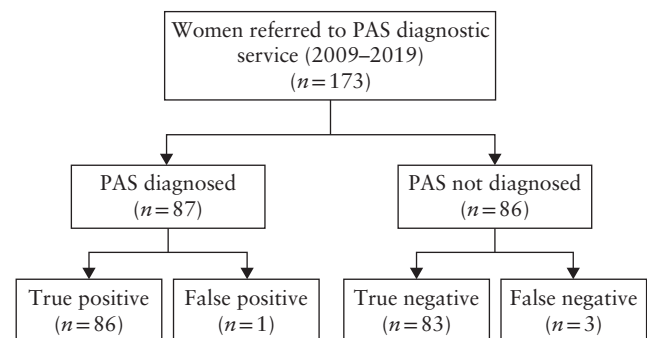
Data are given as median (interquartile range) or *n* (%) unless stated otherwise. *Data missing for ethnicity in 12 cases. †Reference: ≤ 35 years. ‡Reference: ≤ 24 kg/m².

Table 2 Paired stepwise multivariable logistic regression analysis of risk factors for placenta accreta spectrum disorders in women with diagnosis of placenta previa at 32–34 weeks' gestation

Variable	Odds ratio (95% CI)	P
Previous Cesarean section		
1	23.88 (6.16–157.49)	< 0.001
≥ 2	90.33 (20.93–631.93)	< 0.001
Previous Cesarean section plus:		
Maternal age > 35 years	1.08 (0.98–1.20)	0.11
Asian ethnicity	4.16 (0.98–21.39)	0.06
Afro-Caribbean ethnicity	17.37 (4.54–87.93)	< 0.001
Parity 1	0.70 (0.02–19.31)	0.809
Parity ≥ 2	2.56 (0.10–66.77)	0.513
Placenta covering internal cervical os at last scan	20.32 (5.19–139.06)	< 0.001
Placenta within 2 cm of internal cervical os at last scan	17.59 (3.35–236.74)	0.007
Anterior placenta at last scan	12.35 (4.04–47.65)	< 0.001

Diagnostic cohort

One hundred and seventy-three (99 local and 74 external) suspected cases of PAS were referred to the diagnostic service between 2009 and 2019 (Figure 2). There were one false-positive and three false-negative diagnoses of PAS in this cohort. The overall performance of the PAS diagnostic service was: sensitivity, 96.63% (95% CI, 90.46–99.30%); specificity, 98.81% (95% CI, 93.54–99.97%); positive likelihood ratio, 81.17 (95% CI, 11.56–569.76); and negative likelihood ratio, 0.03 (95% CI, 0.01–0.10).

**Figure 2** Flowchart of women in cohort referred for suspicion of placenta accreta spectrum (PAS) disorder, showing accuracy of PAS diagnostic service.

DISCUSSION

Routine contingent screening for PAS based on the finding of placenta previa in the third trimester and a history of Cesarean section is both feasible and effective. The capability of such a screening program to result in improved clinical outcome is contingent on access to a multidisciplinary PAS diagnostic and surgical service.

Comparison with other studies

The prevalences of placenta previa (0.4%) and PAS (0.04%) in our screening cohort are in line with the prevalences of 0.56% and 0.07%, respectively, described previously in a meta-analysis of population-based studies³¹, consistent with the assertion that our study

was performed in a routine pregnancy population. The finding that the number of previous Cesarean sections and diagnosis of placenta previa were the most important risk factors for PAS is consistent with the findings of previous systematic reviews of PAS^{1,6,7}. Even one previous Cesarean section increased the odds for PAS by over 25-fold in a cohort of women with placenta previa, and the majority of PAS cases in our cohort had had only one previous Cesarean section. Other previous uterine surgeries were not associated with PAS in this cohort, which is in contrast to the findings of some previous studies^{32,33}. It is difficult to decide whether the lack of an association between previous uterine surgery other than Cesarean section and PAS is a consequence of the small number of cases included or a true finding of this study^{33,34}.

Afro-Caribbean ethnicity remained associated with PAS even after statistical correction for previous Cesarean section. This finding has not been reported previously and might be explained either by socioeconomic determinants of health in black and minority ethnic populations or, more likely, by residual confounding from the relatively low number of patients with PAS in the screening cohort and the increased likelihood of Cesarean birth in Afro-Caribbean women.

Despite general consensus among international guidelines that women with previous uterine surgery and a low-lying placenta are at increased risk for PAS, there has been no previous systematic evaluation of the effectiveness of such a contingent screening program^{9,22}. A first-trimester screening strategy for PAS based on the identification of a low-lying placenta in women with previous uterine surgery between 11 and 13 weeks has been described³⁵. Although the benefit of such early screening would be to provide women with the option to have a first-trimester termination of pregnancy, the drawbacks are the number of additional follow-up visits and low specificity, which would result in a large number of referrals to a PAS diagnostic service. The contingent screening described in the current study does not require additional routine scan visits, but still resulted in a high rate of detection of PAS. The St George's Hospital PAS diagnostic service correctly identified 86 out of 89 cases of PAS using ultrasound alone, resulting in a sensitivity and specificity greater than 95%, superior to those in retrospective studies (sensitivity, 88% (95% CI, 81.0–93.0%); specificity, 90% (95% CI, 88.0–93.0%)) and comparable with those in prospective diagnostic studies (sensitivity, 97% (95% CI, 93.0–99.0%); specificity, 97% (95% CI, 97.0–98.0%))⁹.

Clinical implications

Effective prenatal screening that correctly identifies pregnancies complicated by PAS would significantly improve maternal outcomes, because the women could have a scheduled birth in a center with tertiary level facilities specialized in PAS care¹³. The need for such screening is compounded by the continuing global trend for an increase in both Cesarean section rate and PAS

disorders³⁶. We have shown that contingent screening for PAS in women with previous Cesarean section and a current diagnosis of placenta previa is both feasible and effective. This screening and triage strategy is feasible in lower-resource medical settings with basic obstetric ultrasound facilities and does not require additional visits beyond those that are indicated routinely. The success of such a screening program depends on access to both a specialized PAS diagnostic service with experienced operators and a management service at a tertiary level hospital at which, if the diagnosis of PAS is confirmed, safe delivery can be arranged³⁷.

Strengths and limitations

The major strengths of the present study are related to the relevant sample size in both the screening and diagnostic cohorts. Additionally, significant expertise was combined with a robust surgical service with distinctive skills in the conservative management of PAS to allow linkage of antenatal ultrasound findings with surgical and histological records. The Triple P procedure used includes myometrial excision alongside preservation of the uterus and allows a full histological diagnosis in the majority of cases²⁹.

An obvious limitation is the retrospective nature of the study, and there is a need to validate these findings in prospective studies set in populations with variable Cesarean section rates in order to ensure validity in a wide range of settings. The absolute number of cases affected by PAS in the screening cohort was small and, as a consequence, it was not possible to undertake a detailed analysis of risk factors in the prediction of PAS. Finally, our screening protocol failed to detect a case of focal PAS following myomectomy because the placenta was more than 2 cm from the internal os.

Conclusions

A screening program for PAS based on the identification of women with a persistent low-lying placenta in the third trimester and a history of previous Cesarean section was both feasible and highly effective. This contingent strategy has the potential to improve the antenatal PAS detection rate and decrease maternal morbidity and mortality related to undiagnosed PAS.

ACKNOWLEDGMENTS


Conrado Milani Coutinho's postdoctoral fellowship at St George's University Hospital was supported by funds from Fundação de Amparo à Pesquisa do Estado de São Paulo (FAPESP), process number 2019/01280-3. Veronica Giorgione's PhD is part of the iPLACENTA project, which has received funding from the European Union's Horizon 2020 research and innovation program under the Marie Skłodowska-Curie grant agreement No 765274.

REFERENCES

- Jauniaux E, Bunce C, Grønbeck L, Langhoff-Roos J. Prevalence and main outcomes of placenta accreta spectrum: a systematic review and meta-analysis. *Am J Obstet Gynecol* 2019; 221: 208–218.
- Wu S, Kocherginsky M, Hibbard JU. Abnormal placentation: Twenty-year analysis. *Am J Obstet Gynecol* 2005; 192: 1458–1461.
- Morlando M, Sarno L, Napolitano R, Capone A, Tessitore G, Maruotti GM, Martinelli P. Placenta accreta: Incidence and risk factors in an area with a particularly high rate of cesarean section. *Acta Obstet Gynecol Scand* 2013; 92: 457–460.
- Higgins MF, Monteith C, Foley M, O'Herlihy C. Real increasing incidence of hysterectomy for placenta accreta following previous caesarean section. *Eur J Obstet Gynecol Reprod Biol* 2013; 171: 54–56.
- Cheng KKN, Lee MMH. Rising incidence of morbidly adherent placenta and its association with previous caesarean section: A 15-year analysis in a tertiary hospital in Hong Kong. *Hong Kong Med J* 2015; 21: 511–517.
- De Mucio B, Serruya S, Alemán A, Castellano G, Sosa CG. A systematic review and meta-analysis of cesarean delivery and other uterine surgery as risk factors for placenta accreta. *Int J Gynaecol Obstet* 2019; 147: 281–291.
- Iacovelli A, Liberati M, Khalil A, Timor-Tritsch I, Leombroni M, Buca D, Milani M, Flacco ME, Manzoli L, Fanfani F, Cali G, Familiari A, Scambia G, D'Antonio F. Risk factors for abnormally invasive placenta: a systematic review and meta-analysis. *J Matern Fetal Neonatal Med* 2020; 33: 471–481.
- Fitzpatrick KE, Sellers S, Spark P, Kurinczuk JJ, Brocklehurst P, Knight M. Incidence and Risk Factors for Placenta Accreta/Increta/Percreta in the UK: A National Case–Control Study. *PLoS One* 2012; 7: e52893.
- Jauniaux E, Bhide A. Prenatal ultrasound diagnosis and outcome of placenta previa accreta after cesarean delivery: a systematic review and meta-analysis. *Am J Obstet Gynecol* 2017; 217: 27–36.
- Tinari S, Buca D, Cali G, Timor-Tritsch I, Palacios-Jaraquemada J, Rizzo G, Lucidi A, Di Mascio D, Liberati M, D'Antonio F. Systematic review and meta-analysis of posterior placenta accreta spectrum disorders: risk factors, histopathology and diagnostic accuracy. *Ultrasound Obstet Gynecol* 2020. DOI: 10.1002/uog.22183.
- Green L, Knight M, Seney FM, Hopkinson C, Collins PW, Collis RE, Simpson N, Weeks A, Stanworth SS. The epidemiology and outcomes of women with postpartum haemorrhage requiring massive transfusion with eight or more units of red cells: a national cross-sectional study. *BJOG* 2016; 123: 2164–2170.
- O'Brien JM, Barton JR, Donaldson ES. The management of placenta percreta: Conservative and operative strategies. *Am J Obstet Gynecol* 1996; 175: 1632–1638.
- Buca D, Liberati M, Cali G, Forlani F, Caisutti C, Flacco ME, Manzoli L, Familiari A, Scambia G, D'Antonio F. Influence of prenatal diagnosis of abnormally invasive placenta on maternal outcome: systematic review and meta-analysis. *Ultrasound Obstet Gynecol* 2018; 52: 304–309.
- Shamshirsaz AA, Fox KA, Salமான B, Diaz-Arrastia CR, Lee W, Baker BW, Ballas J, Chen Q, Van Veen TR, Javadian P, Sangi-Haghighi H, Zacharias N, Welty S, Cassidy CI, Moaddab A, Popek EJ, Hui SKR, Teruya J, Bandi V, Coburn M, Cunningham T, Martin SR, Belfort MA. Maternal morbidity in patients with morbidly adherent placenta treated with and without a standardized multidisciplinary approach. *Am J Obstet Gynecol* 2015; 212: 218.e1–9.
- Pinas-Carrillo A, Bhide A, Moore J, Hartopp R, Belli AM, Arulkumaran S, Thilaganathan B, Chandraran E. Outcomes of the first 50 patients with abnormally invasive placenta managed using the “Triple P Procedure” conservative surgical approach. *Int J Gynaecol Obstet* 2020; 148: 65–71.
- Pagani G, Cali G, Acharya G, Tritsch IT, Palacios-Jaraquemada J, Familiari A, Buca D, Manzoli L, Flacco ME, Fanfani F, Liberati M, Scambia G, D'Antonio F. Diagnostic accuracy of ultrasound in detecting the severity of abnormally invasive placentation: a systematic review and meta-analysis. *Acta Obstet Gynecol Scand* 2018; 97: 25–37.
- Melcer Y, Jauniaux E, Maymon S, Tsviban A, Pekar-Zlotin M, Betsler M, Maymon R. Impact of targeted scanning protocols on perinatal outcomes in pregnancies at risk of placenta accreta spectrum or vasa previa. *Am J Obstet Gynecol* 2018; 218: 443.e1–443.e8.
- Fitzpatrick KE, Sellers S, Spark P, Kurinczuk JJ, Brocklehurst P, Knight M. The management and outcomes of placenta accreta, increta, and percreta in the UK: A population-based descriptive study. *BJOG* 2014; 121: 62–71.
- Bowman ZS, Eller AG, Kennedy AM, Richards DS, Winter TC 3rd, Woodward PJ, Silver RM. Accuracy of ultrasound for the prediction of placenta accreta. *Am J Obstet Gynecol* 2014; 211: 177.e1–7.
- Jauniaux ERM, Alfirevic Z, Bhide AG, Belfort MA, Burton GJ, Collins SL, Dornan S, Jurkovic D, Kayem G, Kingdom J, Silver R, Sentilhes L, Royal College of Obstetricians and Gynaecologists. Placenta Praevia and Placenta Accreta: Diagnosis and Management: Green-top Guideline No. 27a. *BJOG* 2019; 126: e1–e48.
- Bhide A, Prefumo F, Moore J, Hollis B, Thilaganathan B. Placental edge to internal os distance in the late third trimester and mode of delivery in placenta praevia. *BJOG* 2003; 110: 860–864.
- Jauniaux E, Bhide A, Kennedy A, Woodward P, Hubinont C, Collins S, Duncombe G, Klaritsch P, Chantraine F, Kingdom J, Grønbeck L, Rull K, Nigatu B, Tikkanen M, Sentilhes L, Asatiani T, Leung WC, Alhaidari T, Brennan D, Kondoh E, Yang JI, Seoud M, Jegasothy R, Espino y Sosa S, Jacod B, D'Antonio F, Shah N, Bombá-Opon D, Ayres-de-Campos D, Jeremic K, Kok TL, Soma-Pillay P, Tul Mandić N, Lindqvist P, Arnadottir TB, Hoesli I, Jaisamrarn U, Al Mulla A, Robson S, Cortez R. FIGO consensus guidelines on placenta accreta spectrum disorders: Prenatal diagnosis and screening. *Int J Gynaecol Obstet* 2018; 140: 274–280.
- Bhide A, Laoreti A, Kaelin Agten A, Papageorgiou A, Khalil A, Uprichard J, Thilaganathan B, Chandraran E. Lower uterine segment placental thickness in women with abnormally invasive placenta. *Acta Obstet Gynecol Scand* 2019; 98: 95–100.
- di Pasquo E, Ghi T, Cali G, D'Antonio F, Fratelli N, Forlani F, Prefumo F, Kaihura CT, Volpe N, Dall'Asta A, Frusca T. Intracervical lakes as sonographic marker of placenta accreta spectrum disorder in patients with placenta previa or low-lying placenta. *Ultrasound Obstet Gynecol* 2020; 55: 460–466.
- Cali G, Forlani F, Lees C, Timor-Tritsch I, Palacios-Jaraquemada J, Dall'Asta A, Bhide A, Flacco ME, Manzoli L, Labate F, Perino A, Scambia G, D'Antonio F. Prenatal ultrasound staging system for placenta accreta spectrum disorders. *Ultrasound Obstet Gynecol* 2019; 53: 752–760.
- Jauniaux E, Collins S, Burton GJ. Placenta accreta spectrum: pathophysiology and evidence-based anatomy for prenatal ultrasound imaging. *Am J Obstet Gynecol* 2018; 218: 75–87.
- Chandrarahan E, Rao S, Belli AM, Arulkumaran S. The Triple-P procedure as a conservative surgical alternative to peripartum hysterectomy for placenta percreta. *Int J Gynaecol Obstet* 2012; 117: 191–194.
- Sentilhes L, Kayem G, Chandrarahan E, Palacios-Jaraquemada J, Jauniaux E, Duncombe G, Klaritsch P, Chantraine F, Kingdom J, Grønbeck L, Rull K, Nigatu B, Tikkanen M, Sentilhes L, Asatiani T, Leung WC, Alhaidari T, Brennan D, Kondoh E, Yang JI, Seoud M, Jegasothy R, Espino y Sosa S, Jacod B, D'Antonio F, Shah N, Bombá-Opon D, Ayres-de-Campos D, Jeremic K, Kok TL, Soma-Pillay P, Tul Mandić N, Lindqvist P, Arnadottir TB, Hoesli I, Jaisamrarn U, Al Mulla A, Robson S, Cortez R. FIGO consensus guidelines on placenta accreta spectrum disorders: Conservative management. *Int J Gynaecol Obstet* 2018; 140: 291–298.
- Jauniaux E, Ayres-de-Campos D, Langhoff-Roos J, Fox KA, Collins S, Duncombe G, Klaritsch P, Chantraine F, Kingdom J, Grønbeck L, Rull K, Tikkanen M, Sentilhes L, Asatiani T, Leung WC, Alhaidari T, Brennan D, Seoud M, Hussein AM, Jegasothy R, Shah KN, Bombá-Opon D, Hubinont C, Soma-Pillay P, Mandić NT, Lindqvist P, Arnadottir B, Hoesli I, Cortez R. FIGO classification for the clinical diagnosis of placenta accreta spectrum disorders. *Int J Gynaecol Obstet* 2019; 146: 20–24.
- von Elm E, Altman DG, Egger M, Pocock SJ, Gøtzsche PC, Vandenbroucke JP. The Strengthening of Reporting of Observational Studies in Epidemiology (STROBE) statement: guidelines for reporting observational studies. *Lancet* 2007; 370: 1453–1457.
- Jauniaux E, Grønbeck L, Bunce C, Langhoff-Roos J, Collins SL. Epidemiology of placenta previa accreta: A systematic review and meta-analysis. *BMJ Open* 2019; 9: 1–9.
- Gyamfi-Bannerman C, Gilbert S, Landon MB, Spong CY, Rouse DJ, Varner MW, Caritis SN, Meis PJ, Wapner RJ, Sorokin Y, Carpenter M, Peaceman AM, O'Sullivan MJ, Sibai BM, Thorp JM, Ramin SM, Mercer BM. Risk of uterine rupture and placenta accreta with prior uterine surgery outside of the lower segment. *Obstet Gynecol* 2012; 120: 1332–1337.
- Baldwin HJ, Patterson JA, Nippita TA, Torvaldsen S, Ibiebele I, Simpson JM, Ford JB. Antecedents of abnormally invasive placenta in primiparous women: Risk associated with gynecological procedures. *Obstet Gynecol* 2018; 131: 227–233.
- Carusi DA. The placenta accreta spectrum: Epidemiology and risk factors. *Clin Obstet Gynecol* 2018; 61: 733–742.
- Panaiotova J, Tokunaka M, Krajewska K, Zosmer N, Nicolaidis KH. Screening for morbidly adherent placenta in early pregnancy. *Ultrasound Obstet Gynecol* 2019; 53: 101–106.
- Solheim KN, Esakoff TF, Little SE, Cheng YW, Sparks TN, Caughey AB. The effect of cesarean delivery rates on the future incidence of placenta previa, placenta accreta, and maternal mortality. *J Matern Neonatal Med* 2011; 24: 1341–1346.
- Chandrarahan E, Hartopp R, Thilaganathan B, Coutinho CM. How to set up a regional specialist referral service for Placenta Accreta Spectrum (PAS) disorders? *Best Pract Res Clin Obstet Gynaecol* 2020. DOI: 10.1016/j.bpobgyn.2020.07.007.

SUPPORTING INFORMATION ON THE INTERNET

The following supporting information may be found in the online version of this article:

 **Table S1** Description of findings in women with placenta accreta spectrum (PAS) disorder assessed in screening study



Eficacia de la detección contingente para los trastornos del espectro de la placenta acreta a partir de la placenta baja persistente y en la cirugía uterina previa

RESUMEN

Objetivo La mortalidad materna relacionada con los trastornos de la gama espectral de la placenta acreta (EPA) sigue siendo considerable cuando se diagnostica de forma inesperada en el momento del parto. El objetivo de este estudio fue evaluar la efectividad de un programa rutinario de detección contingente mediante ecografía para el EPA.

Métodos Este fue un estudio retrospectivo de datos obtenidos entre 2009 y 2019, en el que participaron dos grupos: una cohorte de detección de mujeres no seleccionadas que acudieron a la evaluación ecográfica rutinaria de mitad de trimestre y una cohorte de diagnóstico, integrada por mujeres remitidas al servicio de diagnóstico del EPA con un presunto diagnóstico del EPA. En la cohorte de detección, a las mujeres con una placenta baja en la evaluación de mitad de trimestre se les hizo un seguimiento en el tercer trimestre, y a aquellas con una placenta baja persistente (es decir, placenta previa) que habían tenido cirugía uterina previa se las remitió al servicio de diagnóstico del EPA. La evaluación ecográfica por el servicio de diagnóstico del EPA consistió en una ecografía Doppler bidimensional en escala de grises y en color, y a las mujeres con diagnóstico del EPA se las trató habitualmente con una resección conservadora del miometrio. El diagnóstico final del EPA se basó en una combinación de indicadores clínicos intraoperatorios y el examen histopatológico de la muestra quirúrgica.

Resultados En total, 57179 mujeres se sometieron a una evaluación rutinaria de la anatomía fetal a mitad del trimestre, de las cuales a 220 (0,4%) se les diagnosticó con placenta previa en el tercer trimestre. Setenta y cinco de estas mujeres fueron remitidas al servicio de diagnóstico del EPA, debido a su historial de cirugía uterina, y 21 de los 22 casos de EPA fueron diagnosticados correctamente (sensibilidad, 95,45% (IC 95%, 77,16–99,88%) y especificidad, 100% (IC 95%, 99,07–100%)). El análisis univariante demostró que la paridad ≥ 2 (razón de momios (RM), 35,50 (IC 95%, 6,90–649,00)), dos o más cesáreas previas (RM, 94,20 (IC 95%, 22,00–656,00)) y la placenta previa (RM, 20,50 (IC 95%, 4,22–369,00)) fueron los factores de riesgo más fuertes para el EPA. En la cohorte de diagnóstico, se remitió a 173 mujeres, entre las cuáles hubo un diagnóstico de falso-positivo y tres diagnósticos de falsos-negativos, lo que dio como resultado una sensibilidad del 96,63% (IC 95%, 90,46–99,30%) y una especificidad del 98,81% (IC 95%, 93,54–99,97%).

Conclusiones La adopción de una estrategia de detección contingente para el EPA es tanto factible como eficaz en un entorno de atención sanitaria rutinaria. Cuando se asocia a un servicio de diagnóstico y gestión quirúrgica del EPA, la adopción de esa estrategia de detección podría reducir la morbilidad y la mortalidad maternas asociadas a esta afección. Sin embargo, se necesitan estudios prospectivos más amplios antes de aplicar esta estrategia de detección en la práctica clínica habitual.

基于持续性低置胎盘和以前的子宫手术对胎盘植入性疾病 (PAS) 进行酌情筛查的有效性

摘要

目的 在分娩时出乎意料地诊断为胎盘植入性疾病 (PAS) 时, 与之相关的产妇死亡率仍然较高。本研究旨在为PAS评估一项常规超声酌情筛查计划的有效性。

方法 这是对2009年至2019年之间所获数据进行的一项回顾性研究, 涉及两组: 一组为筛检队列, 由未经选择的参加常规孕中期超声评估的孕妇组成; 另一组为诊断队列, 由因疑似PAS诊断而被转介至PAS诊断服务的孕妇组成。在筛检队列中, 孕中期评估时有低置胎盘的妇女得到了晚期妊娠随访, 而那些有持续性低置胎盘 (如前置胎盘) 和以前经历过子宫手术的妇女则被转介至PAS诊断服务。由PAS诊断服务进行的超声评估包括二维灰度图和彩色多普勒超声, 被诊断为PAS的妇女则通常采取保守的子宫肌层切除术来管理。PAS的最终诊断是根据术中临床发现和对手术标本进行组织病理学检查的结合而得出的。

结果 总计57179名妇女进行了常规孕中期胎儿解剖评价, 其中220名 (0.4%) 在晚期妊娠诊断为前置胎盘。在这些妇女中, 有75名因有子宫手术史而被转介到PAS诊断服务; 在22个病例中有21例得到正确诊断 (敏感度, 95.45% (95% CI, 77.16–99.88%); 特异性, 100% (95% CI, 99.07–100%))。经单因素分析表明, 胎次 ≥ 2 (比值比 (OR), 35.50 (95% CI, 6.90–649.00))、以前进行过二次或二次以上的剖腹产手术 (OR, 94.20 (95% CI, 22.00–656.00)) 和前置胎盘 (OR, 20.50 (95% CI, 4.22–369.00)) 都是PAS的最强风险因素。在诊断队列中, 有173个转介, 包括一个假阳性和三个假阴性诊断, 得到96.63%的敏感度 (95% CI, 90.46–99.30%) 和98.81%的特异性 (95% CI, 93.54–99.97%)。

结论 对PAS的酌情筛查策略在常规医疗保健环境中既可行又有效。当关联到PAS诊断和手术管理服务时, 采取此种筛检策略有减少产妇死亡率和与PAS相关发病率的可能性。然而, 在将这一筛检策略实施到常规临床实践中之前, 有必要进行更大规模的前瞻性研究。