

Supracondylar Fractures of the Humerus in Children- Review of Management and Controversies

John Dabis, Karen Daly and Yael Gelfer*

St Georges Hospital NHS Foundation Trust, SW17 0QT, London, United Kingdom

*Corresponding author: Yael Gelfer, St Georges Hospital NHS Foundation Trust, London, SW17 0QT, United Kingdom, Tel: 44-7979370857; E-mail: yaelgelfer@gmail.com

Received date: December 17, 2015, Accepted date: January 9, 2016, Published date: January 16, 2016

Copyright: © 2016 Dabis J, et al. This is an open-access article distributed under the terms of the Creative Commons Attribution License, which permits unrestricted use, distribution and reproduction in any medium, provided the original author and source are credited.

Abstract

Upper extremity fractures account for up to 90% of pediatric fractures. Among these fractures Supracondylar Humerus fractures are one of the commonest requiring surgical intervention and have a high prevalence of associated short term complications such as nerve injuries and long term complications such as cubitus varus. The epidemiology, classifications, clinical evaluation and complications of this fracture is hereby comprehensively reviewed along with controversies in management and available guidelines.

Keywords: Supracondylar fracture; Paediatric fracture; Upper limb fracture; Supracondylar fracture management

Introduction

Supracondylar fractures of the humerus are the most common fractures in children under 7 years old [1] and the most common paediatric fracture requiring surgery [2]. Supracondylar fractures may have significant complications including nerve injury, vascular injury, malunion and compartment syndrome [3].

This review article discusses key topics and controversies. The majority of these issues relate to the management of this fracture. We review the management of extension-type Gartland Type II fractures, k-wire configuration and the management of the pink pulseless hand. The review also brings to attention additional areas of contention including classification system, positioning during surgery, pin removal and how to manage the risk factor of obesity.

Epidemiology

Supracondylar fractures of the humerus represent a significant burden of injuries in children, accounting for 12-17% of all paediatric fractures [2]. Extension injuries account for 95% of supracondylar fractures. The metaphyseal flare of the distal humerus connects the diaphysis of the humeral shaft to the epiphysis. The metaphysis is thinned both anteriorly, coronoid fossa, and posteriorly, olecranon fossa, to accommodate the ulna during flexion and extension respectively. The most common mechanism of injury is when a patient falls onto an outstretched hand with the arm fully extended. The olecranon engages with the olecranon fossa and acts as a fulcrum [4]. Flexion injuries result from direct trauma to the posterior aspect of the distal humerus or falling onto a flexed elbow. These injuries are rare and occur in 2-5% of the cases. There is a unimodal distribution affecting males and females with a peak at 7 years of age. Following this peak, there is a decline in incidence in both sexes equally. These fractures by definition do not involve the physis.

Classification

Gartland classified supracondylar fractures in 1959 [5], with a classification system that differentiates extension supracondylar fractures according to the degree of displacement of the distal fracture fragment; Type I is undisplaced or minimally displaced (Figure 1), Type II is displaced but incomplete with an intact posterior cortex (Figure 2). There may also be coronal angulation and medial column disruption. In 1984, Wilkins [6] modified Gartlands' classification specifically with reference to type II and III fractures.

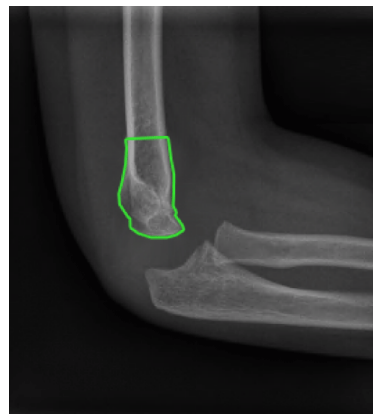


Figure 1: Supracondylar fracture Gartland 1.

Type II was subdivided into Type IIa - stable with posterior angulation and Type IIb - unstable posteriorly angulated and rotated; Type III fractures are displaced fractures with no cortical contact (Figure 3). This can be further subdivided into IIIa - posteromedial displacement and IIIb - posterolateral displacement. A further modification of the Gartland classification has been described; type IV fracture with multi-directional instability [7].

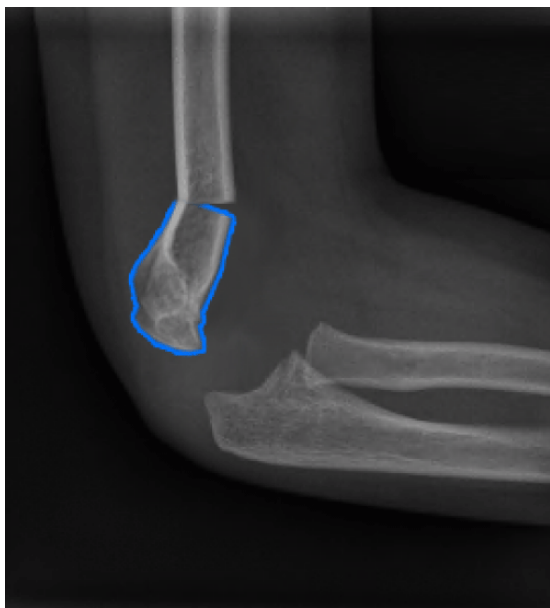

Figure 2: Supracondylar fracture Gartland 2.

Any useful classification system should have strong inter and intra-observer reliability [8], provide basic treatment guidelines, and help to predict outcome. It has been suggested that the Wilkins modification of the Gartland classification showed poor inter-observer reliability for type I fractures, fair to moderate reliability for type II fractures and very good reliability for type III fractures. An analysis by Flierl et al. [9] examined the relationship between coronal fracture displacement and rotational mal-alignment with adverse outcomes. This retrospective review analysed three morphological characteristics on preoperative radiographs from 373 patients. Rotation and coronal displacement patterns were found to be significantly associated with postoperative complications, residual stiffness and nerve injury. The analysis concluded that posterolateral displacement and fractures with rotational deformity were associated with a higher rate of postoperative complications, a greater need for physical or occupational therapy and nerve injury. These findings allow the treating surgeon to anticipate potential complications. Heal et al. [10] also established that treatment should be according to the degree of displacement.

As Flierl et al. [9] alluded to, there are other factors which should guide management and outcome. The reliable and most widely used Gartland classification does not help the operating surgeon decide if a fracture requires open or closed reduction. Lim et al. [11] presented a retrospective analysis evaluating the relationship between radiological parameters and the mode of reduction and length of operation. The medial corner angle was calculated and an angle of less than 45 degrees was classified as a medial spike.

The fracture tip – skin distance was also calculated. The medial spike group had a significantly shorter fracture tip-skin distance with significantly more complications than the control group. No difference in preoperative neurovascular status was found.

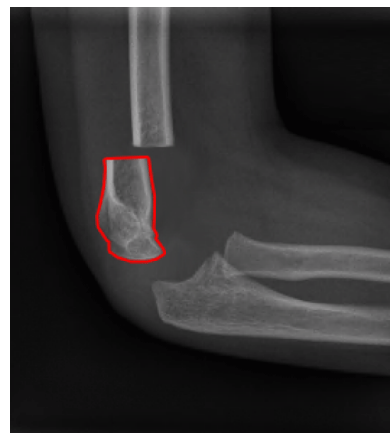

Figure 3: Supracondylar fracture Gartland 3.

There was a substantial increase in operating time in the medial spike group, however no difference in the mode of reduction and composite outcome between the two groups. The authors concluded that recognition of these radiological parameters should alert the surgeon of the potential difficulties in reduction and possibility of open reduction.

Assessment of Injury

The British Orthopaedic Association Standards for Trauma on supracondylar fractures of the humerus in children (see box 1) recommend an assessment of the limb to include the status of radial pulse, capillary refill time and the individual function of the radial, median (including anterior interosseous) and ulnar nerves. The guidelines further recommend post-operative radiographs should be obtained between 4 and 10 days to ensure maintenance of reduction [3].

Box 1: Boast 11: Supracondylar fractures of the humerus in children

- A documented assessment of the limb, performed on presentation, must include the status of radial pulse, digital capillary refill time and the individual function of the radial, median (including anterior interosseous) and ulnar nerves.
- These injuries require early surgical treatment, ideally on the day of admission. However, night-time operating is not necessary unless there are indications for urgent surgery.
- Indications for urgent surgical treatment include absent radial pulse, clinical signs of impaired perfusion of the hand and digits, and evidence of threatened skin viability.
- Surgical stabilisation should be with bicortical wire fixation. Crossed wires are associated with a lower risk of loss of fracture reduction, whereas divergent lateral wires reduce the risk of injury to the ulnar nerve.
- If a medial wire is used, techniques to avoid ulnar nerve injury should be employed and recorded on the operation note.
- 2 mm diameter wires should be used, where possible, to achieve stability.

- Cubitus varus should be avoided by achieving a carrying angle (or Baumann angle) similar to the contralateral arm.
- The majority of nerve injuries associated with supracondylar fractures or its surgical management are transient neurapraxias and can be managed expectantly. If there is concern over iatrogenic injury then a thorough assessment with consultant input is required for consideration of nerve exploration.
- The majority of vascular impairments associated with supracondylar fractures resolve with fracture reduction. A perfused limb does not require brachial artery exploration whether or not the radial pulse is present.
- In case of children presenting with an ischaemic limb, the case should be discussed with the on-call vascular team in the network prior to operative reduction.
- If the limb remains ischaemic after open or closed fracture reduction then exploration of the brachial artery is required with a surgeon competent to perform a small vessel vascular repair.
- Documented post-operative monitoring of neurovascular status should occur until the treating surgeon is confident there is no risk of vascular compromise or compartment syndrome.
- Suspicion of compartment syndrome or deterioration of perfusion should prompt immediate vascular re-assessment and intervention if required.
- Post-operative radiographs should be obtained between 4 and 10 days to ensure maintenance of reduction.
- Wire removal and mobilisation is typically recommended at 3 to 4 weeks.
- Routine long-term follow up is not usually required.

Evidence: Predominantly retrospective case series but with good expert reviews and an evolved professional consensus.

Clinical evaluation

It is important that the entire limb is evaluated in children sustaining supracondylar fractures. Ipsilateral forearm fractures can occur and increase the risk of compartment syndrome. Assessment of the soft tissue swelling and presence of any skin puckering is critical information to be sought. This results from the proximal fragment piercing the overlying brachialis muscle and resting on the dermis of the overlying skin. The vascular status needs to be interrogated and the radial pulse, temperature and colour of the hand needs to be recorded and compared to the contralateral side as does the capillary refill. Vascular examination findings must be clear as this will influence the rapidity of management. A white, cold, pulseless hand will ultimately have a different approach to a pink warm hand with a bounding pulse. The preoperative neurological status is imperative due to the high prevalence of neurological injury (10-15%) [12] and the possibility of an iatrogenic nerve injury.

The clinical examination of a very young child with supracondylar fracture could prove to be challenging but most children will be able to cooperate with a simple neurological examination. All peripheral nerves of the forearm can be assessed with the thumb alone. Enclosing the wrist gently with one hand allows the examiner to assess movement of the fingers without moving the fracture area and causing pain. Anterior interosseous nerve injury is the most prevalent nerve injury in extension type supracondylar fractures, however with posterolaterally displaced fractures the radial nerve injury is more prevalent. Ulnar nerve injuries are the most common nerve lesion in

flexion type fractures [13]. Open fractures should receive tetanus prophylaxis and intravenous antibiotics as per guidelines [14].

Obesity

Recent studies in this field have raised the concern that childhood obesity causes a more complex fracture pattern and increases the risk of associated injuries. Children are classified as obese if their Body Mass Index (BMI) equals or exceeds the age and sex-specific 95th percentile. Seeley et al. [15] found that obesity in children who have sustained a supracondylar fracture of the humerus are at a higher risk of a complex fractures, preoperative nerve injury, persistent postoperative nerve palsy, and postoperative complications. Complex fractures in their series were classified as type-3 according to Gartland, supracondylar humeral fractures with intercondylar extension and ipsilateral upper limb fractures. Chang et al. [16] evaluated the influence of obesity on surgical outcomes after control of fracture severity. Obese children were more likely to develop varus deformities and loss of reduction post operatively. There was also a higher incidence of pin-related complications in the obese group.

Compartment syndrome

Continued serial examinations should include evaluation of patient pain levels, agitation and response to medication and splinting. Pain out of proportion to the physical finding may be a result of ischaemia and ultimately, compartment syndrome. Missed compartment syndrome can lead to Volkmann ischaemic contracture of the forearm which affects deep volar compartment most profoundly. The classic symptoms of pallor, paralysis and parasthesia are late symptoms that typically represent irreversible damage to the neuromuscular tissue. Severe pain on passive finger extension and a tense compartment are reliable signs of compartment syndrome.

Radiographic evaluation

There are several features that should be sought on radiographs which should be correlated with the clinical examination findings. Dedicated AP and true lateral radiographs of the elbow, with the addition of oblique views should be used for evaluation. Oblique views may be used to assess the medial and lateral columns. Occasionally, contralateral elbow radiographs can help if there is any uncertainty in diagnosis. Assessment of the elbow radiograph should commence with the anterior humeral line, which is a line is drawn down from the anterior cortex of the humerus. This line should intersect with the middle third of the capitellum. Subtle angulations can be detected. Sometimes a fracture line cannot be identified and the only positive finding is a posterior +/- anterior fat pad sign, which is a result of the fracture haematoma displacing the olecranon fat pad. This is highly suggestive of a fracture. The Baumann angle is also important for assessment. The humeral-capitellar angle is the angle between the mid axis of the humeral shaft and the physeal line of the lateral condyle. This angle is normally between 9 and 26 degrees. A decrease would raise the suspicion of varus malposition [17].

Management

Initial management

The initial management should include splinting the limb in a comfortable position and analgesia. Usually 20 to 40 degrees of flexion is sufficient. One should avoid excessive flexion as this can reduce the

arterial flow to the limb and increase the risk of compartment syndrome [18,19].

Traction

This treatment modality has declined in popularity [20]. There have been many case series [21,22] reporting excellent outcomes with traction however there are concerns of cubitus varus, pin complications, compartment syndrome and a limited justification for prolonged admission [20,23]. Despite several series describing successful results with straight-line traction, others reported cubitus varus rates as high as 33%.

Several traction techniques have been described (overhead, lateral, skin or skeletal). It has been suggested for irreducible fractures to allow closed reduction and in a very swollen arm [24], although the best way to address swelling would be to reduce and stabilise the fracture. It may also be appropriate in children where there is a high risk associated with General Anaesthetic eg: Cardiac disease.

Closed reduction and percutaneous fixation

This is the most common modality of treatment for supracondylar fractures, and is the treatment of choice for most Gartland II and III fractures [25]. Under general anaesthetic, either over the image intensifier or a radiolucent table, reduction is attempted. The assistant grasps the proximal Humerus to allow traction with a steady force with the elbow in extension. Having corrected the rotational malalignment, the coronal plane deformity is addressed, followed by reducing the sagittal plane deformity by flexing the elbow, manipulating the olecranon anteriorly and controlling pronation and supination depending on fracture displacement. With the elbow hyperflexed the reduction can be assessed on both AP and lateral views.

The main aims of surgical fixation are restoration of the Baumann angle, having intact medial and lateral columns as per the oblique radiographs and the anterior humeral line passing through the anterior third of the capitellum on the radiograph. It is very important to reduce rotational malalignment as this will compromise fracture stability. K-wires are then inserted once reduction has been confirmed. Further discussion regarding number and configuration is reviewed below.

Open reduction

Absolute indications for open reduction are open fractures, ischaemic pale hand that doesn't revascularise with fracture reduction and failure of closed reduction [11]. If there is nerve injury in the presence of a vascular injury, exploration of both the artery and nerve is advocated [12]. Pucker sign is not an absolute indication of open reduction but should alert the surgeon to the potential need of open reduction.

Many surgical approaches have been reported, however the anterior and lateral approaches are most commonly used [26]. The anterior approach will enable the surgeon to visualise the median nerve and brachial artery and allow reduction of the fracture. It is also cosmetically more pleasing as it lies within Langer's lines.

Garland type I

There is little controversy with regards to management of these undisplaced and minimally displaced fractures. The only pitfalls in

management might happen due to a missed diagnosis of an infection or a pulled elbow in the absence of clear radiographic signs of supracondylar fracture. An above elbow synthetic cast is applied for three to four weeks. During plaster application, with the elbow at 90 degrees, the anterior cubital fossa neurovascular structures are at risk of injury secondary to pressure effect of the cast. Thomson et al. [27] present a two staged method of casting to prevent this complication from occurring. The first layer, scaffold, is applied in a figure of eight manor bridging the antecubital fossa. The second layer is then conventionally applied. It is important to recognise unstable fracture configurations such as transverse fractures as these will need follow up radiographs to ensure no loss of position.

Garland type II

There is some controversy in the treatment of type II fractures with mild posterior angulation. Most authors agree that closed reduction and percutaneous fixation is the treatment of choice [25]. Angulation or displacement on the AP radiograph should give an indication [28] for closed reduction and percutaneous fixation. All paediatric fractures have incredible potential for remodelling however the distal part of the humerus only provides 20% of growth, hence remodelling potential is less compared to other metaphyseal fractures. Hyperextension at the fracture site has been shown to correlate poorly with cast treatment. The greater the degree of fracture extension, based on the anterior humeral line, the higher the risk of failure of cast treatment. This was found to be of significance [29]. Other factors in the same study which were found to correlate with failure of treatment include increased width of soft tissue shadow of the upper arm. Other advantages of closed reduction and percutaneous fixation include avoiding the need for hyperflexion to achieve and maintain reduction of these fractures. Several studies have demonstrated that hyperflexion can reduce the blood flow within the brachial artery [18,19]. Another controversy in management is medial column comminution or type II B fracture that can result in cubitus varus even if minimally displaced [30].

Garland type III

Most of these fractures can still be managed by closed methods and percutaneous fixation. Scannell et al. [31] presents several series with minimal complications and good results following a reproducible reduction technique, which reduces the deformity in the coronal plane and then the sagittal plane. Open reduction is occasionally required and may be achieved via an anterior or lateral approach. Anterior approach can be made through the elbow flexion crease and can directly expose the neurovascular bundle and minimize contractures.

Positioning During Surgery

The supine position is the most common positioning during reduction and stabilisation of supracondylar fractures. Some authors have proposed that the prone position is preferable as gravity aids sagittal correction and less manipulation of the arm is required [32]. Venkatadass et al. [33] conducted a randomised controlled trial to attempt to establish if there were any advantages of prone positioning relative to supine positioning during reduction and fixation of supracondylar humeral fractures. Clinical and radiological outcome parameters were recorded in each group. 52 children with Gartland Type III fractures without vascular injuries were randomly allocated to either prone or supine position. There were no advantages amongst the prone positioned patients. Feldman et al. [32] concluded that prone positioning adds an anaesthetic risk and should be avoided.

Pin configuration

Closed reduction and pin fixation is indicated for a reducible but unstable fracture, and fractures which require more than 90 degrees of flexion to maintain a reduced position. At least two wires are used to prevent rotation yet the most appropriate pin configuration remains controversial. The most common wire configurations include a lateral-entry technique using two or three wires or a medial and lateral crossed wire technique [34,35]. Iatrogenic ulnar nerve injury with cross wire techniques has led researchers to investigate the efficacy of laterally placed wire fixation techniques. Previous biomechanical analyses suggested that lateral wire configurations were inferior to cross wire configurations however these studies were criticised as being flawed because the wire insertions were not divergent and not separate at the fracture site [36,37].

Zhao et al. [38] performed a meta-analysis of randomised controlled trials (RCT) to compare the risk of iatrogenic ulnar nerve injury caused by wire fixation, the quality of reduction and radiographic outcome and function. Seven RCTs involving 521 patients were included in the analysis. The crossed medial-lateral wire fixation technique was found to pose potentially more risk for iatrogenic ulnar nerve injury than the lateral based wire techniques.

Karim et al. [39] undertook a prospective randomised controlled trial in a level one trauma centre comparing the outcomes of the crossed and the lateral wire configurations in the management of supracondylar humeral fractures. This included Gartland Type II and III fractures in 60 children who were managed by junior trainees in the first three years of training. The cohort was split equally and followed up for six months. The primary outcome measures included postoperative stability, ulnar nerve injury, range of motions and pin tract infection.

There was a statistically significant difference in stability between the crossed and lateral pin group, with the latter proving less stable. Ulnar nerve neurapraxia occurred in one patient from the lateral group and no ulnar nerve injury occurred in the crossed configuration group. Two patients in the lateral group lost approximately 10 of elbow flexion. This article demonstrates fixation techniques need to be stable and should be checked under fluoroscopy after the wires are inserted. If stability is in question a supplementary wire should be used. If a medial wire is used the elbow should be placed in extension to avoid the nerve subluxing anteriorly when the elbow is flexed [40]. Jaeblo et al. [41] investigated the optimal pin configurations for fracture varieties, which have not been previously investigated such as low, sagittal oblique and high fractures. Three subgroups of 30 were used to stimulate one of three fracture variations. The groups included two lateral pins, three lateral pins and cross wires. Three forces were analysed including anteroposterior, medial-lateral and rotational stiffness. The authors conclude that lateral pin configurations provide adequate stiffness to maintain reduction of low transverse, sagittal oblique, and high transverse fractures without risk of injury to the ulnar nerve [41]. In one study there was an eight-fold increase in risk of iatrogenic nerve injury in the crossed wire group [42]. Cross wire fixations led to a higher incidence of overall complications with increased iatrogenic nerve injury.

The recommended pin configuration remains a controversy. As fracture configuration, stability and surgeons preference come into consideration it is important to remember to protect the ulnar nerve if cross wire technique is chosen, to use 2 mm width pins and to insist on divergent lateral wire configuration to improve stability.

Timing of surgery

Abbott et al. [42] performed a retrospective analysis investigating the impact of time to surgery on the incidence of complications and conversion to open reduction. There was no significant correlation between time to surgery and complications, operative time or the need for open reduction.

Removal of pins

Following closed reduction and percutaneous pinning with smooth kirschner wires for displaced and unstable supracondylar fractures in children, the pins are normally removed 3-4 weeks following surgery. Lim et al. [43] recognised that pin removal can be a source of anxiety for children and their guardians. Better patient education and play therapy was found to significantly reduce the pain experienced during pin removal in clinic compared to oral ibuprofen.

Management of the Supracondylar with Nerve Injury

Mangat et al. [12] found a strong correlation between anterior interosseous nerve injury and entrapment of both the nerve and the vessel at the fracture site. They recommended early exploration in patients with coexisting anterior interosseous nerve injury. More recently, Barrett et al. [44] carried out a multicentre retrospective study isolating thirty five of 4409 patients with supracondylar fractures and isolated anterior interosseous nerve palsies. They did not find any evidence that the associated nerve injury required urgent treatment. Time to theatre was not associated with improved recovery rates or a decrease in complication rate. Even a delay of up to 24 hours did not make a difference to the final outcome.

Management of the pink pulseless hand

Controversy still remains in the management of the viable pulseless hand with recommendations varying from observation through angiography to immediate surgical intervention. Vascular injury in a supracondylar fracture can occur in several ways. The brachial artery can be stretched or kinked over the displaced fragments. There may be a direct injury causing a contusion or an intimal tear. It may also be partially lacerated or completely transected. Neurological deficit in addition to a pulseless limb should raise the suspicion of an arterial injury.

Authors that advocate immediate surgery to restore the pulse argue that a viable extremity can still result in thrombus formation, cold intolerance, late compartment syndrome and growth discrepancy [45]. There is little evidence to support the use of Doppler ultrasound pre or post-operatively, even if the pulse can be detected. There is also limited evidence supporting pre and post operative angiography. Angiography may prolong ischaemia time and should not delay fracture reduction. Badkoobei et al. [46] presented a very simple and logical flowchart for the management of supracondylar fractures. In the situation of a poorly perfused and pulseless extremity, emergent reduction and stabilisation with percutaneous wires is performed. The perfusion is then re-assessed and in the case of persistent signs of impaired perfusion, open vascular exploration is performed. The reduction and stabilisation was reported to restore the pulse and blood supply in up to 72% of cases. A 5 cm anterior transverse incision over the antecubital fossa is advised, which will enable the artery and median nerve to be visualized.

In the case of a well perfused pulseless limb, the fracture should be reduced and stabilized on the first available trauma list with close monitoring of the limb until then. Closed reduction is attempted, proceeding to open reduction in cases where reduction cannot be achieved. The vascular status of the limb is reassessed following reduction. If the pulse returns and the limb is well perfused, observation for 12 hours is the optimal management. If the limb remains well perfused but pulseless, the limb should be monitored until the pulse returns or until the operating surgeon is satisfied. In the event the hand is poorly perfused and pulseless following reduction and stabilisation, open vascular exploration is required and compartment release should be considered [46]. There are several advocates of the watchful waiting approach with frequent neurovascular observations. Choi et al. [47] have published their experience with a more conservative approach. The importance of the hand being perfused rather than having a pulse is stressed. The rich collateral circulation of the elbow provides alternative circulation to the limb in these cases. Another large [48] series advocates the reduction and observation method with no cases requiring open exploration. It is important to note that only nine out of 403 cases presented without a pulse.

Scannell et al. [31] presented an intermediate-term review of a series of perfused, pulseless supracondylar fractures who were managed with closed reduction, percutaneous fixation and observation. All fractures were Gartland type-III. 25% of the cohort had a return of the pulse following fracture reduction and all limbs had a radial pulse at final follow up. In their retrospective analysis they did not find any correlation between occlusion of the brachial artery and a reduced wrist brachial index. Several comparisons with the unaffected side, including arm circumference, elbow range of movement and grip strength were not found to be significantly different. Despite a quarter of their cohort having occluded brachial arteries, function, range of movement and growth were comparable to the contralateral side. Weller et al. [49] presented their case series of 20 supracondylar Gartland III fractures with a pink pulseless hand. Following reduction they were monitored and a pulse was detectable on Doppler ultrasound. 19 of the 20 patients had a palpable pulse return with no clinical sequelae. Hence it is important, after management of these injuries, there is a period of observation for 24 to 48 hours with serial examinations.

The British Society for Children's Orthopaedic Surgery (BSCOS) report that 60% of surgeons favour continued observation if the forearm remains pulseless [50]. 24% of surgeons responded that they would call for an opinion from a vascular surgeon and 16% would immediately explore the artery. It is imperative to have clear guidelines of managing these situations in any setting, whether in a district general hospital or a major trauma centre. When observation is the management of choice before or after reduction, clear instruction regarding the frequency of vascular assessment and meticulous documentation is key.

Post-Operative Complications

The complication of supracondylar can be divided into early and late. Early complications include vascular injury, nerve injury and compartment syndrome. Late complications include malunion and stiffness.

Early Complications

Vascular injury is reported between 2-38 % in Gartland type III. The management of acute vascular injury is discussed in the previous section. Peripheral nerve injury occurs in 10-15% of supracondylar fractures. The most commonly affected nerve in extension type injuries is the anterior interosseous nerve although the median, ulnar and radial nerve can be injured as well [51].

Managing peripheral nerve palsy is often challenging due to the difficulty in obtaining a reliable clinical examination in the emergency setting. It is important to provide explanation and reassurance to the parents regarding the very high likelihood of recovery of the nerve. In the rare case of lack of clinical improvement after 8-12 weeks, nerve conduction studies should be considered to ensure the nerve is intact. Compartment syndrome. The incidence of compartment syndrome following supracondylar fracture has reduced over the years due to improved management of the fracture. The pathology and management of compartment syndrome are beyond the scope of this review. A careful monitoring and high index of suspicion is essential in these settings to try and prevent this complication.

Late Complications

Malunion; (Cubitus Varus or valgus) is a common complication with an incidence of up to 50%. It is assessed by measuring the carrying angle of the arm in the supinated forearm and comparing it to the contralateral side. It is secondary to inadequate reduction leading to malunion. Supracodylar fracture does not cause growth arrest. Cubitus varus and valgus can cause both functional limitations and cosmetic deformity. Angular deformity in the coronal plane at the distal humerus has limited ability to remodel and the best treatment of this complication is avoidance.

Or et al. [52] considered what the optimal treatment is for supracondylar fractures when malalignment is recognised early in the course of fracture treatment and follow up. Their study compares the outcome of early revision for loss of alignment with the previous published results of late corrective osteotomies. The authors concluded that early diagnosis and aggressive intervention to achieve alignment should be the adopted approach for improved range of movement and to reduce the rate of cubitus varus. Elbow stiffness is a rare complication. Following 6 weeks in a cast, it is rare to find a difference in range of motion greater than 15 degrees from the contralateral side. Most cases improve within a few short months.

Conclusion

In this review the evidence based guidelines for supracondylar fracture management along with the numerous controversies are discussed. Even though managing this fracture had improved over the years resulting in lower complication rate, it remains challenging and stressful to manage at times. Considered medical judgment and a patient's clinical circumstances and preferences should always guide patient care and treatment.

References:

1. Cheng JC, Ng BK, Ying SY, Lam PK (1999) A 10-year study of the changes in the pattern and treatment of 6,493 fractures. *J Pediatr Orthop* 19: 344-350.

2. Khoshbin A, Leroux T, Wasserstein D, Wolfstadt J, Law PW, et al. (2014) The epidemiology of paediatric supracondylar fracture fixation: a population-based study. *Injury* 45: 701-708.
3. British orthopaedic association standards for trauma (BOAST) BOAST 11: supracondylar fractures of the humerus in children.
4. Amis AA, Miller JH (1995) The mechanisms of elbow fractures: an investigation using impact tests in vitro. *Injury* 26: 163-168.
5. Gartland JJ (1959) Management Of Supracondylar Fractures Of The Humerus In Children. *Surg Gynecol Obstet* 109: 145-154.
6. Rockwood CA, Wilkins KE, King RE (Editors) (1984) Fractures in children. Philadelphia: JB Lippincott Co. Wilkins KE. Fractures and dislocations of the elbow region: 363-575.
7. Leitch KK, Kay RM, Femino JD, Tolo VT, Storer SK, et al. (2006) Treatment of multidirectionally unstable supracondylar humeral fractures in children. A modified Gartland type-IV fracture. *J Bone Joint Surg Am* 88: 980-985.
8. Barton KL, Kaminsky CK, Green DW, Shean CJ, Kautz SM, et al. (2001) Reliability of a modified Gartland classification of supracondylar humerus fractures. *J Pediatr Orthop* 21: 27-30.
9. Flierl MA, Carry PM, Scott F, Georgopoulos G, Hadley-Miller N (2015) Rotation and Displacement Predict Adverse Events in Pediatric Supracondylar Fractures. *Orthopedics* 38: 690-695.
10. Heal J, Bould M, Livingstone J, Blewitt N, Blom AW (2007) Reproducibility of the Gartland classification for supracondylar humeral fractures in children. *J Orthop Surg (Hong Kong)* 15: 12-14.
11. Lim KB, Lim CT, Tawng DK (2013) Supracondylar humeral fractures in children: beware the medial spike. *Bone Joint J* 95-95B: 1290-1294.
12. Mangat KS, Martin AG, Bache CE (2009) The 'pulseless pink' hand after supracondylar fracture of the humerus in children: the predictive value of nerve palsy. *J Bone Joint Surg Br* 91: 1521-1525.
13. Babal JC, Mehlman CT, Klein G (2010) Nerve injuries associated with pediatric supracondylar humeral fractures: a meta-analysis. *J Pediatr Orthop* 30: 253-263.
14. BOAST 4 guidelines (2009) The management of severe open lower limb fractures - British Orthopaedic Association And British Association of Plastic, Reconstructive and Aesthetic Surgeons Standard for Trauma.
15. Seeley MA, Gagnier JJ, Srinivasan RC, Hensinger RN, VanderHave KL, et al. (2014) Obesity and its effects on pediatric supracondylar humeral fractures. *J Bone Joint Surg Am* 96: e18.
16. Chang CH, Kao HK, Lee WC, Yang WE (2015) Influence of obesity on surgical outcomes in type III paediatric supracondylar humeral fractures. *Injury* 46: 2181-2184.
17. Rang M, Pring ME, Wenger DR (2005) Rang's children's fractures. Philadelphia: Lippincott Williams & Wilkins.
18. Battaglia TC, Armstrong DG, Schwend RM (2002) Factors affecting forearm compartment pressures in children with supracondylar fractures of the humerus. *J Pediatr Orthop* 22: 431-439.
19. Mapes RC, Hennrikus WL (1998) The effect of elbow position on the radial pulse measured by Doppler ultrasonography after surgical treatment of supracondylar elbow fractures in children. *J Pediatr Orthop* 18: 441-444.
20. Kosuge D, Barry M (2015) Changing trends in the management of children's fractures. *Bone Joint J* 97-97B: 442-8.
21. Gadgil A, Hayhurst C, Maffulli N, Dwyer JS (2005) Elevated, straight-arm traction for supracondylar fractures of the humerus in children. *J Bone Joint Surg Br* 87: 82-87.
22. Piggot J, Graham HK, McCoy GF (1986) Supracondylar fractures of the humerus in children. Treatment by straight lateral traction. *J Bone Joint Surg Br* 68: 577-583.
23. Prietto CA (1979) Supracondylar fractures of the humerus. A comparative study of Dunlop's traction versus percutaneous pinning. *J Bone Joint Surg Am* 61: 425-428.
24. Agus H, Kalenderer O, Kayali C, Eryanilmaz G (2002) Skeletal traction and delayed percutaneous fixation of complicated supracondylar humerus fractures due to delayed or unsuccessful reductions and extensive swelling in children. *J Pediatr Orthop B* 11: 150-154.
25. Skaggs DL, Sankar WN, Albrektson J, Vaishnav S, Choi PD, et al. (2008) How safe is the operative treatment of Gartland type 2 supracondylar humerus fractures in children? *J Pediatr Orthop* 28: 139-141.
26. Rasool MN, Naidoo KS (1999) Supracondylar fractures: posterolateral type with brachialis muscle penetration and neurovascular injury. *J Pediatr Orthop* 19: 518-522.
27. Thomson LE, Pagkalos J, Prem H (2015) Splintage following supracondylar fracture in paediatrics. *Ann R Coll Surg Engl* 97: 317-318.
28. Ariyawatkul T, Eamsobhana P, Kaewpornawan K (2015) The necessity of fixation in Gartland type 2 supracondylar fracture of the distal humerus in children (modified Gartland type 2A and 2B). *J Pediatr Orthop B* .
29. Fitzgibbons PG, Bruce B, Got C, Reinert S, Solga P, et al. (2011) Predictors of failure of nonoperative treatment for type-2 supracondylar humerus fractures. *J Pediatr Orthop* 31: 372-376.
30. Park MJ, Ho CA, Larson AN (2015) AAOS Appropriate Use Criteria: Management of Pediatric Supracondylar Humerus Fractures. *J Am Acad Orthop Surg* 23: e52-55.
31. Scannell BP, Jackson JB 3rd, Bray C, Roush TS, Brighton BK, et al. (2013) The perfused, pulseless supracondylar humeral fracture: intermediate-term follow-up of vascular status and function. *J Bone Joint Surg Am* 95: 1913-1919.
32. Feldman D (2015) Supine Position Is Ideal for Manipulation and Pinning of All Types of Supracondylar Fractures Compared with the Prone Position. *J Bone Joint Surg Am* 97: 1372.
33. Venkatadass K, Balachandar G, Rajasekaran S (2015) Is Prone Position Ideal for Manipulation and Pinning of Displaced Pediatric Extension-type Supracondylar Fractures of Humerus? A Randomized Control Trial. *J Pediatr Orthop* 35: 672-676.
34. Brauer CA, Lee BM, Bae DS, Waters PM, Kocher MS (2007) A systematic review of medial and lateral entry pinning versus lateral entry pinning for supracondylar fractures of the humerus. *J Pediatr Orthop* 27: 181-186.
35. Kocher MS, Kasser JR, Waters PM, Bae D, Snyder BD, et al. (2007) Lateral entry compared with medial and lateral entry pin fixation for completely displaced supracondylar humeral fractures in children. A randomized clinical trial. *J Bone Joint Surg Am* 89: 706-712.
36. Zions LE, McKellop HA, Hathaway R (1994) Torsional strength of pin configurations used to fix supracondylar fractures of the humerus in children. *J Bone Joint Surg Am* 76: 253-256.
37. Onwuanyi ON, Nwobi DG (1998) Evaluation of the stability of pin configuration in K-wire fixation of displaced supracondylar fractures in children. *Int Surg* 83: 271-274.
38. Zhao JG, Wang J, Zhang P (2013) Is lateral pin fixation for displaced supracondylar fractures of the humerus better than crossed pins in children? *Clin Orthop Relat Res* 471: 2942-2953.
39. Karim MA, Hosny A, Nasef Abdelatif NM, Hegazy MM, Awadallah WR, et al. (2015) Crossed Wires versus Two Lateral Wires in Management of Supracondylar Fracture of the Humerus in Children in the Hands of Junior Trainees. *J Orthop Trauma*.
40. Zaltz I, Waters PM, Kasser JR (1996) Ulnar nerve instability in children. *J Pediatr Orthop* 16: 567-569.
41. Jaeblohn T, Anthony S, Ogden A, Andary JJ (2015) Pediatric Supracondylar Fractures: Variation in Fracture Patterns and the Biomechanical Effects of Pin Configuration. *J Pediatr Orthop* .
42. Abbott MD, Buchler L, Loder RT, Caltoun CB (2014) Gartland type III supracondylar humerus fractures: outcome and complications as related to operative timing and pin configuration. *J Child Orthop* 8: 473-477.
43. Lim KB, Tan SS, Abdullah SN, Ong LL, Wong ML, et al. (2014) Percutaneous pin removal in the outpatient clinic--do children require analgesia?: a randomized controlled trial. *J Bone Joint Surg Am* 96: 597-602.
44. Barrett KK, Skaggs DL, Sawyer JR, Andras L, Moisan A, et al. (2014) Supracondylar humeral fractures with isolated anterior interosseous

-
- nerve injuries: is urgent treatment necessary? *J Bone Joint Surg Am* 96: 1793-1797.
45. Howard A, Mulpuri K, Abel MF, Braun S, Bueche M, et al. (2012) American Academy of Orthopaedic Surgeons. The treatment of pediatric supracondylar humerus fractures. *J Am Acad Orthop Surg* 20: 320-327.
46. Badkoobehi H, Choi PD, Bae DS, Skaggs DL (2015) Management of the pulseless pediatric supracondylar humeral fracture. *J Bone Joint Surg Am* 97: 937-943.
47. Choi PD, Melikian R, Skaggs DL (2010) Risk factors for vascular repair and compartment syndrome in the pulseless supracondylar humerus fracture in children. *J Pediatr Orthop* 30: 50-56.
48. Cheng JC, Lam TP, Maffulli N (2001) Epidemiological features of supracondylar fractures of the humerus in Chinese children. *J Pediatr Orthop B* 10: 63-67.
49. Weller A, Garg S, Larson AN, Fletcher ND, Schiller JR, et al. (2013) Management of the pediatric pulseless supracondylar humeral fracture: is vascular exploration necessary? *J Bone Joint Surg Am* 95: 1906-1912.
50. Malviya A, Simmons D, Vallamshetla R, Bache CE (2006) Pink pulseless hand following supra-condylar fractures: an audit of British practice. *J Pediatr Orthop B* 15: 62-64.
51. Joiner ER, Skaggs DL, Arkader A, Andras LM, Lightdale-Miric NR, et al. (2014) Iatrogenic nerve injuries in the treatment of supracondylar humerus fractures: are we really just missing nerve injuries on preoperative examination? *Pediatr Orthop* 34: 388-392.
52. Or O, Weil Y, Simanovsky N, Panski A, Goldman V, et al. (2015) The Outcome Of Early Revision Of Malaligned Pediatric Supracondylar Humerus Fractures. *Injury* 46: 1585-1590.