

Image guidance and improved accuracy of external ventricular drain tip position particularly in patients with small ventricles

Anan Shtaya, PhD,^{1,2} Joy Roach, MRCS,¹ Ahmed-Ramadan Sadek, DPhil (Oxon), FRCS(SN),¹ Benjamin Gaastra, MRCS,¹ Jonathan Hempenstall, FRCS(SN),¹ and Diederik Bulters, FRCS(SN)¹

¹Wessex Neurological Centre, University Hospital Southampton, Southampton; and ²Neurosciences Research Centre, St. George's, University of London, United Kingdom

OBJECTIVE External ventricular drain (EVD) insertion is one of the most common emergency neurosurgical procedures. EVDs are traditionally inserted freehand (FH) in an emergency setting, but often result in suboptimal positioning. Image-guided surgery (IGS) is selectively used to assist placement. However, the accuracy and practicality of IGS use is yet to be reported. In this study, the authors set out to assess if IGS is practical and improves the accuracy of EVD placement.

METHODS Case notes and images obtained in patients who underwent frontal EVD placement were retrospectively reviewed. Ventriculomegaly was determined by the measurement of the Evans index. EVD location was classified as optimal (ipsilateral frontal horn) or suboptimal (any other location). Propensity score matching of the two groups (IGS vs FH) for the Evans index was performed. Data were analyzed for patient age, diagnosis, number of EVDs, and complications. Those without postoperative CT scans were excluded.

RESULTS A total of 607 patients with 760 EVDs placed were identified; 331 met inclusion criteria. Of these, 287 were inserted FH, and 44 were placed with IGS; 60.6% of all unmatched FH EVDs were optimal compared with 75% of the IGS group ($p = 0.067$). The IGS group had a significantly smaller Evans index ($p < 0.0001$). Propensity score matching demonstrated improved optimal position in the IGS group when compared with the matched FH group (75% vs 43.2%, OR 4.6 [1.5–14.6]; $p = 0.002$). Patients with an Evans index of ≥ 0.36 derived less benefit (75% in IGS vs 66% in FH, $p = 0.5$), and those with an Evans index < 0.36 derived more benefit (75% in IGS vs 53% in FH, $p = 0.024$). The overall EVD complication rate was 36% in the FH group versus 18% in the IGS group ($p = 0.056$). Revision rates were higher in the FH group ($p = 0.035$), and the operative times were similar ($p = 0.69$). Long intracranial EVD catheters were associated with tip malposition irrespective of the group.

CONCLUSIONS Image guidance is practical and improves the accuracy of EVD placement in patients with small ventricles; thus, it should be considered for these patients.

<https://thejns.org/doi/abs/10.3171/2017.11.JNS171892>

KEYWORDS hydrocephalus; external ventricular drain; Evans index; image guidance; freehand; surgical technique

PLACEMENT of an external ventricular drain (EVD) is the most commonly performed neurosurgical procedure for the measurement and management of elevated intracranial pressure in hydrocephalus and to deliver intrathecal medications. Despite the acceptance of the role of image guidance in neurosurgery for over 2 decades,¹⁴ the insertion of EVDs is frequently performed freehand (FH) using anatomical surface landmarks to direct the

catheter tip into the ipsilateral frontal horn to lie close to the foramen of Monro.⁶ Incorrect placement of the catheter tip using the FH technique is not infrequent, with rates of 12.3% to 44.9% reported in the literature.^{8,15} Indeed, it has been observed that suboptimal EVD tip placement can result in revision or replacement of an EVD in up to 40% of cases.¹⁶

Several authors have described anatomical scoring sys-

ABBREVIATIONS EVD = external ventricular drain; FH = freehand; IGS = image-guided surgery; ST1–3 = surgical trainees in years 1–3; ST4–8 = surgical trainees in years 4–8.

SUBMITTED August 2, 2017. **ACCEPTED** November 10, 2017.

INCLUDE WHEN CITING Published online May 11, 2018; DOI: 10.3171/2017.11.JNS171892.

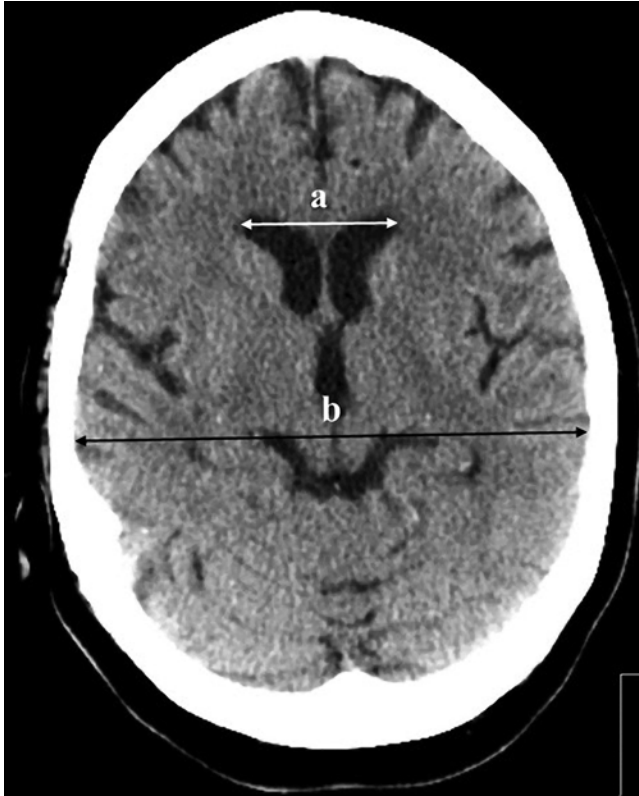


FIG. 1. Illustrative axial CT section obtained in a patient, showing how we measured the Evans index (the maximal frontal horn ventricular width [a] divided by the transverse inner diameter of the cranium at the same brain scan section at the level of the foramen of Monro [b]).

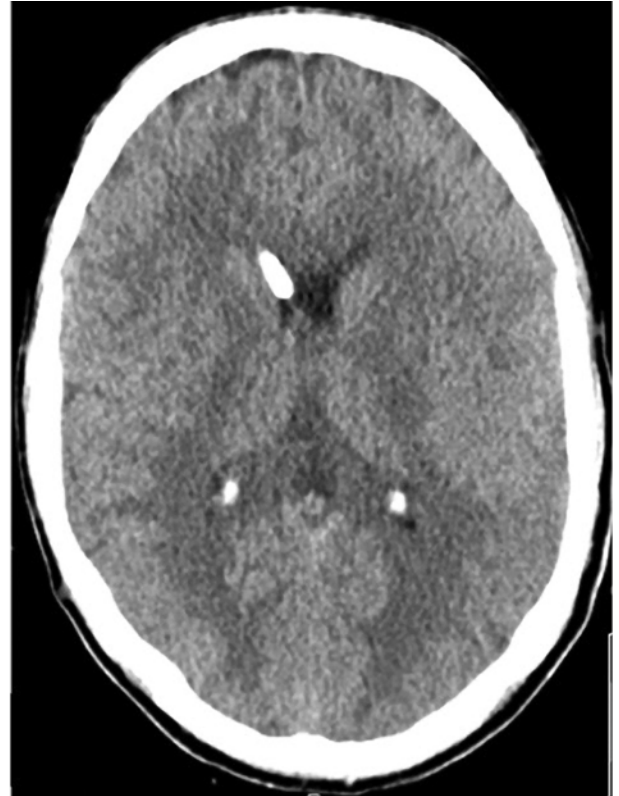

FIG. 2. Illustrative axial CT section obtained in a patient, showing the ipsilateral frontal horn location of the EVD catheter tip.

tems by which to define the optimal position of an EVD catheter tip,^{9,12} while others have argued that a misplaced catheter is, by definition, one in which the EVD is non-functional and requires replacement.³ The observation of CSF flow through an FH-inserted EVD is the only marker of intraoperative success. This in itself is falsely reassuring, as up to 50% of EVD tips have been observed in CSF spaces other than the frontal horn of the lateral ventricle.¹⁶ Indeed, up to 10% of catheter tips are observed to sit within brain parenchyma despite having initially drained CSF following insertion.¹⁶ There is mounting evidence that the use of intraoperative image guidance results in improved accuracy of EVD placement.^{4,5,11} Herein, we describe our center-based experience comparing the accuracy, underlying pathology, and complications of both FH and image-guided insertion of frontal EVDs, with a particular focus on cases with small ventricles.

Methods

This retrospective cohort study is registered as an audit with approval from our institution. A database was created for all EVDs inserted during the period from January 2010 to April 2015. Patients with occipital EVDs, those whose EVDs were inserted under direct vision via craniotomy, and patients without postoperative CT scans were excluded. Data were collected for patient age, diagnosis, number of EVDs, and complications. We subdivided these

patients into the FH group (287 patients) and the image-guided surgery (IGS) group (44 patients). CT scans of the brain were reviewed by the first author (A.S.), who was blinded to outcomes using the hospital Sectra system (Sectra AB), and the EVD tip position was counterchecked against the independent neuroradiology report. The preoperative Evans index (the maximum frontal horn ventricular width [Fig. 1 a] divided by the transverse inner diameter of the cranium on the same brain scan section at the level of the foramen of Monro [Fig. 1 b]) was measured using the Sectra measurement function. EVD tip location was graded as optimal (ipsilateral anterior horn of the lateral ventricle [Fig. 2]) or suboptimal (ipsilateral body or contralateral frontal horn of the lateral ventricle, third ventricle, subarachnoid cisterns, and intraparenchymal).¹⁶ The reviewer (A.S.) was blinded to the CT neuroradiology report in which the EVD tip site was described, which was considered as an internal control for the results. The intracranial EVD length from the tip of the EVD to the inner table of the cranium was also measured. Since it was anticipated that the Evans index would be significantly lower in patients in whom EVDs were inserted under IGS when compared with FH, propensity score matching was performed by an author (B.G.) blinded to the catheter outcomes. Propensity score matching was implemented in the R package MatchIt⁷ using the nearest-neighbor method. Patients were matched according to the Evans index. Only the first procedure accuracy results were analyzed for patients who had more than one EVD. We performed statistical analysis

of the data utilizing the chi-square test, Student's t-test, and propensity score matching using GraphPad Prism (GraphPad Software, Inc.) and IBM SPSS Amos (version 24, IBM Corp.) as appropriate and detailed in *Results*. Significance was set at $p < 0.05$.

EVD Insertion

In our practice, EVD insertion procedures are performed in the operating room using standard tunneled EVD catheters or in the neurointensive care unit using bolt EVDs. No EVDs are placed with the patient in the CT scanner. In this cohort, no bolt EVDs were placed using IGS. The decision whether to place an EVD in the intensive care unit was based on surgeon preference and generally limited to patients with larger ventricles and those needing more urgent drainage. IGS is used when inserting tunneled EVDs in the operating room when feasible, particularly in patients with small ventricles. The surgical navigation electromagnetic tracking system (StealthStation S7, Medtronic) was employed as our IGS method. Preoperative stealth CT or MRI of the head was performed, uploaded to StealthStation, registered, and used to guide the EVD catheter into the ventricles. The standard surgical procedure includes routine skin preparation and draping with the head in a neutral position; a 3-cm skin incision is made over the Kocher point (2.5 cm from midline and 1 cm anterior to the coronal suture) or frontally 10 cm above the supraorbital ridge (midpupillary line) and 2.5 cm from the midline. A burr hole is fashioned using a Stryker 14-mm disposable perforator. After coagulating and opening the dura, the stylet-loaded ventricular catheter is introduced perpendicular to the skull aimed at the ipsilateral medial epicanthus in the coronal plane and just anterior to the external auditory meatus in the sagittal plane. The aim is to target the ipsilateral anterior horn of the lateral ventricle close to the foramen of Monro with a maximum length of intracranial EVD catheter of 6 cm from the brain surface. Free flow of CSF usually suggests successful placement. This is followed by either subcutaneous tunneling of the distal end of the ventricular catheter before closing the skin and securing the catheter to the skin with flange and silk sutures to avoid postoperative unintentional pullout or screwing the bolt to the skull (when Camino bolt [Integra] EVDs were used). The distal end of the catheter is then attached to a closed external drainage and monitoring system (Integra). The need for postoperative CT scanning was based on clinical assessment. Patients with functioning suboptimal EVD tip positions were managed based on clinical grounds and observed as long as the EVDs were patent.

Results

Patient and General Characteristics

A total of 607 patients underwent 760 EVD insertion procedures between January 2010 and April 2015. The median age of the patients was 51 years (range 1 month–84 years). Occipital EVDs ($n = 31$), those that were inserted under direct vision ($n = 26$), EVDs with no postoperative CT head ($n = 219$), and any additional EVDs that were inserted after the first one ($n = 153$) were excluded. A total

TABLE 1. Underlying pathology for IGS vs FH unmatched groups

Pathology	No. of EVDs (%)		p Value	χ^2
	IGS ($n = 44$)	FH ($n = 287$)		
TBI	22 (50)	44 (15.3)	<0.05*	28.7
SAH	11 (25)	102 (35.5)	0.17	1.9
ICH/IVH	2 (4.55)	63 (22.0)	<0.05*	7.3
Tumor	4 (9.1)	38 (13.2)	0.44	0.6
Infection/shunt dysfunction	2 (4.55)	16 (5.6)	0.78	0.08
Postop hydrocephalus	3 (6.8)	2 (0.7)	<0.05*	9.6
Congenital	0 (0)	2 (0.7)	NA	
Colloid cyst	0 (0)	10 (3.5)	NA	
Other	0 (0)	10 (3.5)	NA	

ICH = intracerebral hemorrhage; IVH = intraventricular hemorrhage; NA = not applicable; SAH = subarachnoid hemorrhage; TBI = traumatic brain injury.

* Statistically significant.

of 331 patients' EVDs met the criteria for inclusion in the study. Two hundred eighty-seven EVDs were inserted FH, while 44 EVDs were placed under IGS. The most common indication for EVD insertion in the FH group was subarachnoid hemorrhage, intraventricular hemorrhage, or intracerebral hemorrhage (57.5%; Table 1). Other causes included traumatic brain injury in 15.3% and tumors in 13.2%. However, in the IGS group the most common indication was traumatic brain injury (50%), followed by vascular causes in 29.6% and tumors in 9.1% (Table 1).

In the FH group, EVDs were inserted on the right side in 246 procedures (86%), while in the IGS group they were inserted on the right in 41 procedures (93%), with no significant difference between the two groups ($p = 0.17$, $\chi^2 = 1.8$). Operator data were available for 260 cases from the FH group and the entire IGS group. In the FH group, consultants performed 22 procedures, specialty trainees in years 4–8 (ST4–8) or equivalent level performed 133 operations, and specialty trainees in years 1–3 (ST1–3) or equivalent level did 105 cases. However, in the IGS group, consultants performed only 3 procedures, ST1–3 or equivalent-level trainees inserted 14 EVDs, and ST4–8 or equivalent-level trainees performed 27 procedures. Ventricles were significantly larger in the FH group, and the mean preoperative Evans index for this group was 0.38 ± 0.004 vs 0.31 ± 0.01 in the IGS group ($p < 0.0001$, Student's t-test).

Accuracy of EVD Tip Position for the Unmatched Groups

In the FH group, 174 (60.6%) EVD tips were in the ipsilateral frontal horn, 25 (8.7%) were in the third ventricle, 46 (16%) were in the ipsilateral body of the ventricle, 24 (8.4%) were in the contralateral frontal horn, 16 (5.6%) were in the parenchyma, and 2 (0.7%) were in the basal cisterns (Table 2). However, in the IGS group 33 (75%) EVD tips were in the ipsilateral frontal horn, 6 (13.6%) were in the third ventricle, 1 (2.3%) was in the ipsilateral body of the ventricle, 3 (6.8%) were in the contralateral frontal horn, 1 (2.3%) was in the basal cisterns, and none were in the parenchyma (Table 2). When the EVD tip position was classified as optimal or suboptimal and IGS and

TABLE 2. EVD tip position for both IGS and FH unmatched groups

Location	No. of EVDs (%)		p Value	χ^2
	IGS	FH		
Ipsilateral frontal	33 (75)	174 (60.6)	0.067	3.4
3rd ventricle	6 (13.64)	25 (8.7)	0.3	1.1
Ipsilateral body	1 (2.27)	46 (16)	<0.05*	5.9
Contralateral frontal	3 (6.81)	24 (8.4)	0.73	0.1
Basal cisterns	1 (2.27)	2 (0.7)	0.3	1.1
Brain parenchyma	0	16 (5.6)	NA	

* Statistically significant.

FH groups were compared, there was no significant difference ($p = 0.067$, $\chi^2 = 3.4$).

We hypothesized that smaller ventricles might benefit more and performed an exploratory subgroup analysis to examine if there was a differential effect in large and small ventricles. The median Evans index was 0.36. Utilizing this as a cut point, in those with small ventricles (Evans index < 0.36), IGS more frequently achieved optimal positioning than FH (75% in IGS vs 53% in FH; $p = 0.024$, $\chi^2 = 5.0$), whereas in those with larger ventricles (Evans index ≥ 0.36) there was no significant difference (75% in IGS vs 66% in FH; $p = 0.5$, $\chi^2 = 0.09$). However, there was no obvious cut point beyond which IGS provided no additional benefit.

Accuracy of EVD Tip Position After Propensity Matching of the Groups

As anticipated, the Evans index was significantly smaller in the IGS group ($p < 0.0001$, Student's t-test). Therefore, as planned, we performed propensity score matching of the Evans index for both the IGS and the FH groups to correct for this. Propensity score matching revealed a significantly higher rate of optimal EVD tip positioning in the IGS group when compared with the FH group (75% vs 43.2%; OR 4.6 [1.5–14.6], $p = 0.002$). There were no statistically significant differences in the indications for EVD insertion (Table 3). We further performed propensity score matching of both the Evans index and underlying pathology for both the IGS and the FH groups. The results demonstrated a significantly higher percentage of optimal EVD tip positions in the IGS group (75%) when compared with the FH group (50%) (OR 3 [95% CI 1.22–3.40], $p = 0.016$).

Comparisons of Complications Between the Matched Groups

Although there was a trend, no significant difference in overall complications was observed between the matched groups (36% in FH vs 18% in IGS; $p = 0.056$, $\chi^2 = 3.7$) or in the infection rate (11% in IGS vs 18% in FH; $p = 0.37$, $\chi^2 = 0.8$). However, the rate of EVD revision/reinsertion was significantly higher in the FH group (3 in IGS vs 10 in FH; $p = 0.035$, $\chi^2 = 4.4$) (Table 4). We observed that the catheter tip positions in 50% of the revised EVDs in the FH group were suboptimal, but none of the IGS-revised EVDs were

TABLE 3. Underlying pathology for IGS vs FH matched groups

Variable	No. of EVDs (%)		p Value	χ^2
	IGS	FH		
TBI	22 (50)	16 (36)	0.2	1.7
SAH	11 (25)	14 (32)	0.48	0.5
ICH/IVH	2 (4.5)	7 (15.9)	0.08	3.1
Tumor	4 (9.0)	3 (7)	0.69	0.15
Infection/shunt dysfunction	2 (4.5)	2 (4.5)	1	0
Postop hydrocephalus	3 (7)	1 (2.3)	0.3	1
Congenital	0 (0)	0 (0)	NA	
Colloid cyst	0 (0)	0 (0)	NA	
Other	0 (0)	1 (2.3)	NA	

in a suboptimal position. However, the numbers are too small to perform any meaningful statistical analysis.

EVD Length

There was no significant difference in the mean length of the EVDs placed optimally in the frontal horn (51.9 \pm 1.2 mm FH vs 51.8 \pm 0.9 mm IGS) or in the length of suboptimally placed EVDs (59.2 \pm 2.1 mm FH vs 66.3 \pm 2.9 mm IGS; $p = 0.06$, Student's t-test). However, when considering EVDs placed by either method, suboptimally placed EVDs were longer (51.8 \pm 0.7 mm vs 61.5 \pm 1.8 mm; $p < 0.0001$, Student's t-test).

Operator Distribution for the Matched Groups

In the matched FH group, 3 EVDs were inserted by consultant neurosurgeons, 19 by ST4–8 or equivalent trainees, 20 by ST1–3 or equivalent trainees, and 1 by a neurointensive care technician; insertion data about the surgeon were not available for 1 EVD. This was comparable to the IGS group, where consultants performed 3 procedures, ST1–3 or equivalent-level trainees inserted 14 EVDs, and ST4–8 or equivalent-level trainees performed 27 procedures ($p = 0.3$, $\chi^2 = 2.4$).

EVD Catheter Passes and Operating Room Time for the Matched Groups

Further analysis of the number of catheter passes during EVD insertion revealed no significant difference between the matched FH groups when compared with the IGS group (Table 5).

Operating room time (from arriving into the operating room until surgery finishes) and surgical time (knife to skin until placing last suture) data were available for 18 cases in the FH group and 36 cases in the IGS group. The missing operating room time in some cases is due to either the time not being documented or the EVDs being placed in the neurointensive care unit or emergency department, as observed in 10 cases of the FH matched group. The mean operating room time for placing an FH EVD was 61.00 \pm 7.5 minutes ($n = 18$) versus 63.71 \pm 3.1 minutes for IGS ($n = 36$) ($p = 0.69$, Student's t-test). There was no significant difference in the actual surgical time between the two groups (36.3 \pm 4.9 minutes in FH vs 32.1 \pm 1.9 minutes in the IGS group; $p = 0.35$, Student's t-test).

TABLE 4. Complication comparisons between the matched groups

Complication	No. of EVDs (%)		p Value	χ^2
	IGS	FH		
Overall	8 (18)	16 (36)	0.056	3.7
Infection	5 (11)	8 (18)	0.37	0.8
Fall out	1 (2.3)	5 (11)	0.09	2.9
CSF leak	1 (2.3)	3 (6.8)	0.3	1.0
Blockage	1 (2.3)	0 (0)	NA	
EVD revision/reinsertion	3 (6.8)	10 (22.7)	0.035*	4.4

* Statistically significant.

TABLE 5. Comparison of the number of EVD catheter passes between the matched groups

No. of Passes	No. of EVDs (%)		p Value	χ^2
	IGS	FH		
1	27 (61.4)	24 (54.5)	0.52	0.42
2	4 (4.5)	7 (15.9)	0.33	0.9
3	1 (2.3)	2 (4.5)	0.56	0.3
4	1 (2.3)	0	NA	—
5	1 (2.3)	1 (2.3)	>0.99	0
≥6	1 (2.3)	1 (2.3)	>0.99	0
Unknown	10 (22.7)	10 (22.7)	>0.99	0

Discussion

Insertion of an EVD is a common and often lifesaving procedure. Although it is regarded as simple, there are potential risks of injury, including intracerebral hematoma, infection, and failure from catheter malposition. The traditional FH technique has been associated with a relatively frequent occurrence of these complications.^{11,16} Therefore, other techniques and/or use of available technology should be employed to improve the placement accuracy and reduce complications. The use of a Ghajar guide at Kocher's point and live CT guidance in placing EVD catheters have been described.^{4,6,10,12} Image guidance has also been proposed to have a positive role in EVD placements;¹¹ however, there are few data comparing FH and IGS procedures. We have performed a timely analysis of the precision of EVD placement in consecutive cases using both conventional FH and image guidance techniques at a single busy neurosurgical unit. We classified EVD tip position in the ipsilateral frontal horn as optimal versus tip position in any other location as suboptimal as described by Toma et al.¹⁶ In the FH group, we observed that in 60.6% of cases the EVD tip was in the ipsilateral frontal horn. This figure reaches 85.3% when both ipsilateral body and third ventricles are included. While this may seem disappointing, this result is good compared with those in other published series.^{1,2,9,13,16}

In our study, when IGS was used to insert EVDs, optimal tip position improved to 75%. However, the ventricle size as indicated by the Evans index and the underlying pathology were significantly different when comparing the IGS group with the FH group. This difference in ventricle size between the two groups was because IGS is more likely to be used when the insertion of an EVD is thought to be challenging. Therefore, we performed propensity score matching according to Evans index alone or Evans index and the underlying pathology. The matched population demonstrated that IGS-placed EVDs were significantly more likely to achieve an optimal position than FH-placed ones. We also considered in which patients IGS was of greatest benefit. While patients with an Evans index less than 0.36 saw a greater benefit from IGS placement, those with an Evans index of 0.36 or more were just as likely to have an optimally placed EVD with or without use of IGS ($p = 0.5$, $\chi^2 = 0.09$).

The intracranial EVD catheter length has been associ-

ated with tip malposition.^{15,16} In our study, the mean length of optimally placed EVDs was very similar in the FH and IGS groups (51.9 and 51.8 mm), reiterating traditional teaching that 5 cm is optimal. The mean lengths of suboptimally placed EVDs were 59.2 (FH) and 66.3 (IGS) mm. In addition, the length of suboptimally placed catheters in all cases (i.e., FH and IGS) is significantly longer (61.5 mm) than that of the optimally placed ones (51.8 mm). These results are in agreement with literature and provide clear evidence that whether image guidance is being used or not, long intracranial catheters are probably associated with increased EVD catheter malposition.

Although the difference between groups for overall complications (18% IGS vs 36% FH) did not reach the threshold for significance ($p = 0.056$, $\chi^2 = 3.7$), it was very close and warrants further consideration. Importantly, there was a statistically significant difference in the reinsertion rate, with 3 times as many EVDs undergoing revision/reinsertion in the FH group (6.8% in the IGS vs 22.7% in the FH group, $p = 0.035$, $\chi^2 = 4.4$). Three EVDs were revised in the IGS group versus 10 in the FH group. Although correlating the revision rates with both placement methods and the underlying pathology is also important to consider, the numbers are too small to justify further subanalysis in our study. However, there were no significant differences in underlying pathology noted between the groups (Table 3).

One consideration when employing IGS is the additional time needed to perform the stealth registration on the patient before the actual operating time. However, our results revealed no significant difference in operating room time (32 minutes in the IGS group vs 36 minutes in the FH group). This may reflect increased speed of the procedure once the IGS is set up, compensating for the initial setup time. There is therefore also no additional cost of using IGS in terms of operating room time. However, there is an estimated additional £200 cost in consumables for an IGS procedure.

Limitations

Our results come with the limitations of a retrospective study. The most serious limitation is that patients were selected for IGS on a case-by-case basis by their surgeons. We have attempted to correct for selection bias by employing propensity score matching. However, it remains possible that there were other differences between the groups.

Analyzing the EVD catheter tip site to additionally include the third ventricle as an optimal location will not change the outcome in our study (89% in optimal location in the IGS vs 55% in the FH; $p < 0.001$, $\chi^2 = 12.6$). It is challenging to define and measure this target area and allow for matching of the two groups to occur. On the contrary, the Evans index is a validated method and can be rigorously measured and allow less biased propensity matching of the two groups.

All IGS-placed EVDs were placed in operating rooms; however, in the FH group, 9 EVDs were inserted in the neurointensive care unit and 1 was placed in the emergency department. Subgrouping and further analysis should be considered in future studies.

Missing data also limited some analyses. For example, since the operating room time was not available for all cases included, we noted variability in operating room time, which may be related to the operator and other factors that are beyond the scope of this paper.

Data on the number of passes of the EVD were also recorded too variably to make a meaningful analysis, although it would be interesting to see if this was improved by IGS, as it might be assumed that additional passes would be associated with an increased risk of hematoma.

Generalizability

This consecutive series from a busy tertiary neurosurgical unit would seem applicable across neurosurgical practice. No comparisons have been made with alternative techniques, such as CT or ultrasound guidance, and these may provide similar results.

Our exploratory subgroup analysis suggests that there may be a differential effect in patients with small and large ventricles. It could be argued that IGS should be limited to use in patients with small ventricles, as is largely our practice. However, there was no clear cutoff in the data, and the entire matched cohort had better EVD positions, suggesting that IGS may be applicable to all EVD insertions.

Conclusions

Overall, our results suggest an important role for image guidance in cannulating ventricles, improving accuracy, and reducing the need for repositioning. This benefit is more pronounced in patients with small ventricles, and therefore FH placement might still be a valid technique with acceptable outcomes for patients with large ventricles in the emergency setting, although in this study FH was not associated with any reduction in operative time.

References

1. Abdoh MG, Bekaert O, Hodel J, Diarra SM, Le Guerinel C, Nseir R, et al: Accuracy of external ventricular drainage catheter placement. *Acta Neurochir (Wien)* **154**:153–159, 2012
2. Bergdal O, Springborg JB, Holst AV, Hauerberg J, Way S, Breum P, et al: Accuracy of tunneled vs. bolt-connected external ventricular drains. *Clin Neurol Neurosurg* **115**:1972–1975, 2013
3. Bogdahn U, Lau W, Hassel W, Gunreben G, Mertens HG, Brawanski A: Continuous-pressure controlled, external ventricular drainage for treatment of acute hydrocephalus—evaluation of risk factors. *Neurosurgery* **31**:898–904, 1992
4. Fiorella D, Peeling L, Denice CM, Sarmiento M, Woo HH: Integrated flat detector CT and live fluoroscopic-guided external ventricular drain placement within the neuroangiography suite. *J Neurointerv Surg* **6**:457–460, 2014
5. Gautschi OP, Smoll NR, Kotowski M, Schatlo B, Tosic M, Stimec B, et al: Non-assisted versus neuro-navigated and XperCT-guided external ventricular catheter placement: a comparative cadaver study. *Acta Neurochir (Wien)* **156**:777–785, 2014
6. Ghajar JB: A guide for ventricular catheter placement. Technical note. *J Neurosurg* **63**:985–986, 1985
7. Ho DE, Imai K, King G, Stuart EA: MatchIt: Nonparametric preprocessing for parametric causal inference. *J Stat Software* **42**:1–28, 2011
8. Huyette DR, Turnbow BJ, Kaufman C, Vaslow DF, Whiting BB, Oh MY: Accuracy of the freehand pass technique for ventriculostomy catheter placement: retrospective assessment using computed tomography scans. *J Neurosurg* **108**:88–91, 2008
9. Kakarla UK, Kim LJ, Chang SW, Theodore N, Spetzler RF: Safety and accuracy of bedside external ventricular drain placement. *Neurosurgery* **63**:ONS162–ONS167, 2008
10. Krötz M, Linsenmaier U, Kanz KG, Pfeifer KJ, Mutschler W, Reiser M: Evaluation of minimally invasive percutaneous CT-controlled ventriculostomy in patients with severe head trauma. *Eur Radiol* **14**:227–233, 2004
11. Mahan M, Spetzler RF, Nakaji P: Electromagnetic stereotactic navigation for external ventricular drain placement in the intensive care unit. *J Clin Neurosci* **20**:1718–1722, 2013
12. O’Leary ST, Kole MK, Hoover DA, Hysell SE, Thomas A, Shaffrey CI: Efficacy of the Ghajar Guide revisited: a prospective study. *J Neurosurg* **92**:801–803, 2000
13. Park YG, Woo HJ, Kim E, Park J: Accuracy and safety of bedside external ventricular drain placement at two different cranial sites: Kocher’s point versus forehead. *J Korean Neurosurg Soc* **50**:317–321, 2011
14. Peters T, Davey B, Munger P, Comeau R, Evans A, Olivier A: Three-dimensional multimodal image-guidance for neurosurgery. *IEEE Trans Med Imaging* **15**:121–128, 1996
15. Saladino A, White JB, Wijdicks EF, Lanzino G: Malplacement of ventricular catheters by neurosurgeons: a single institution experience. *Neurocrit Care* **10**:248–252, 2009
16. Toma AK, Camp S, Watkins LD, Grieve J, Kitchen ND: External ventricular drain insertion accuracy: is there a need for change in practice? *Neurosurgery* **65**:1197–1201, 2009

Disclosures

The authors report no conflict of interest concerning the materials or methods used in this study or the findings specified in this paper.

Author Contributions

Conception and design: Shtaya, Bulters. Acquisition of data: Shtaya, Roach. Analysis and interpretation of data: all authors. Drafting the article: all authors. Critically revising the article: Shtaya, Bulters. Reviewed submitted version of manuscript: all authors. Approved the final version of the manuscript on behalf of all authors: Shtaya. Statistical analysis: Shtaya, Gaastra. Study supervision: Bulters.

Correspondence

Anan Shtaya: Neurosciences Research Centre, St. George’s, University of London, United Kingdom. ashtaya@sgul.ac.uk.